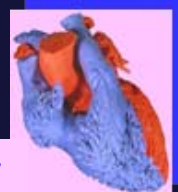

Anatomy of unrepaired Tetralogy of Fallot

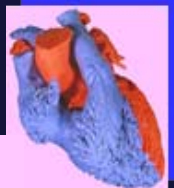S. Yen Ho
London, UK



The anatomic spectrum of Fallot

Malformation first described by
Niels Stensen in 1673

Etienne-Louis Arthur Fallot
1888

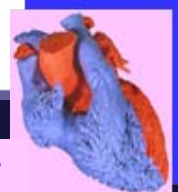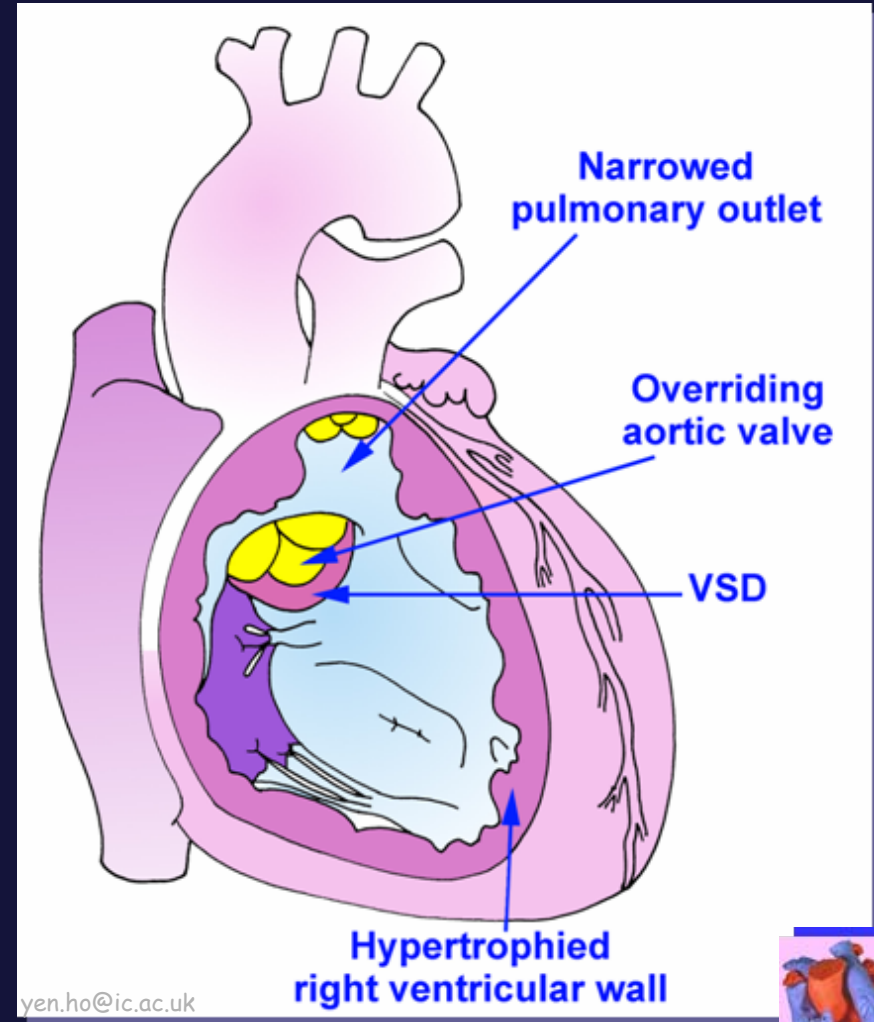


Cardiac Morphology

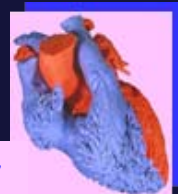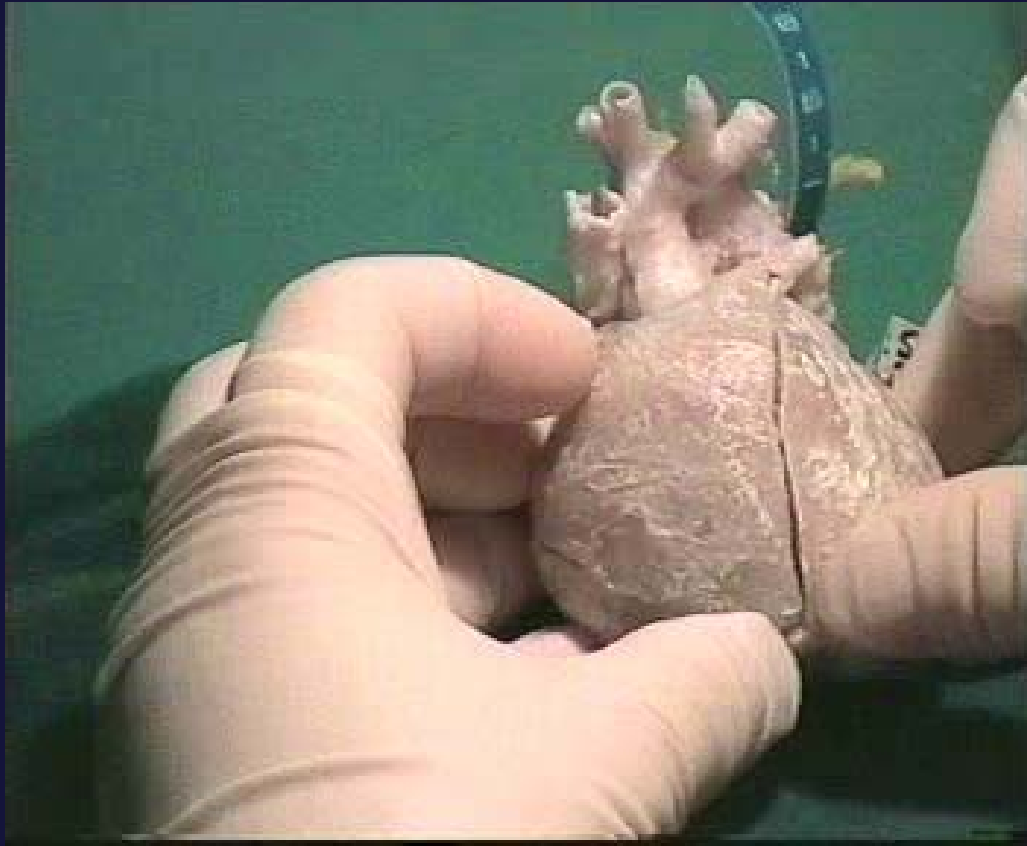
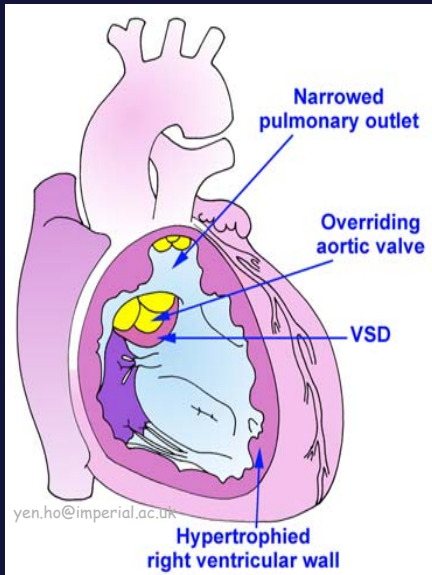
Anatomy of unrepaired Tetralogy of Fallot

- the native lesion

5% of congenital heart disease

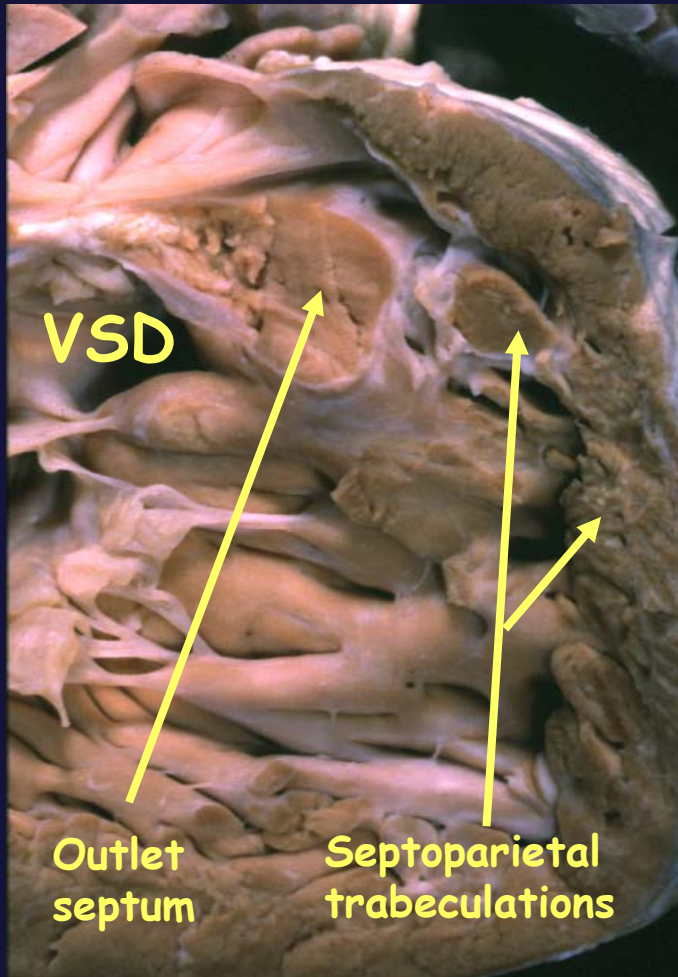


Cardiac Morphology



Anatomy of unrepaired Tetralogy of Fallot

Characteristic morphologic features

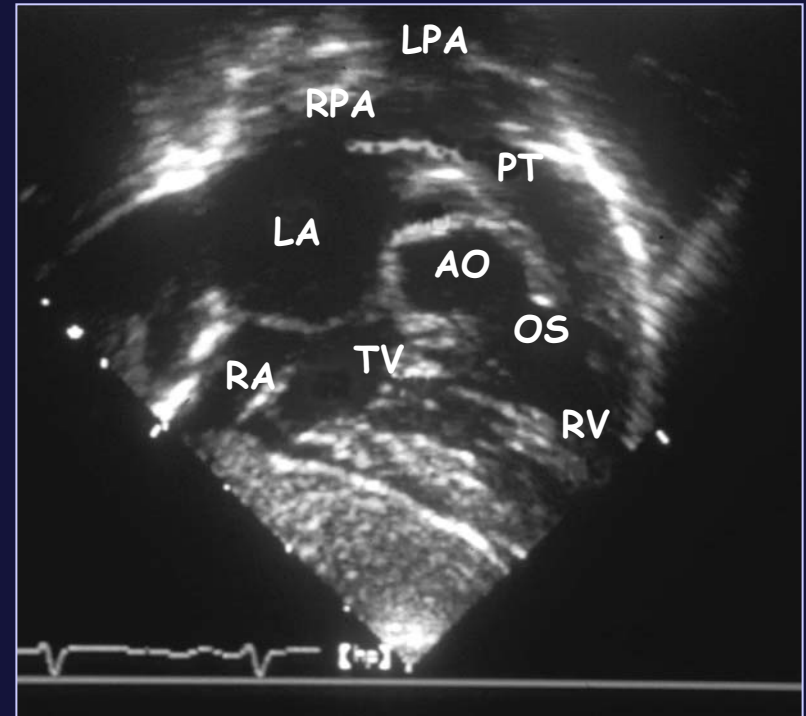
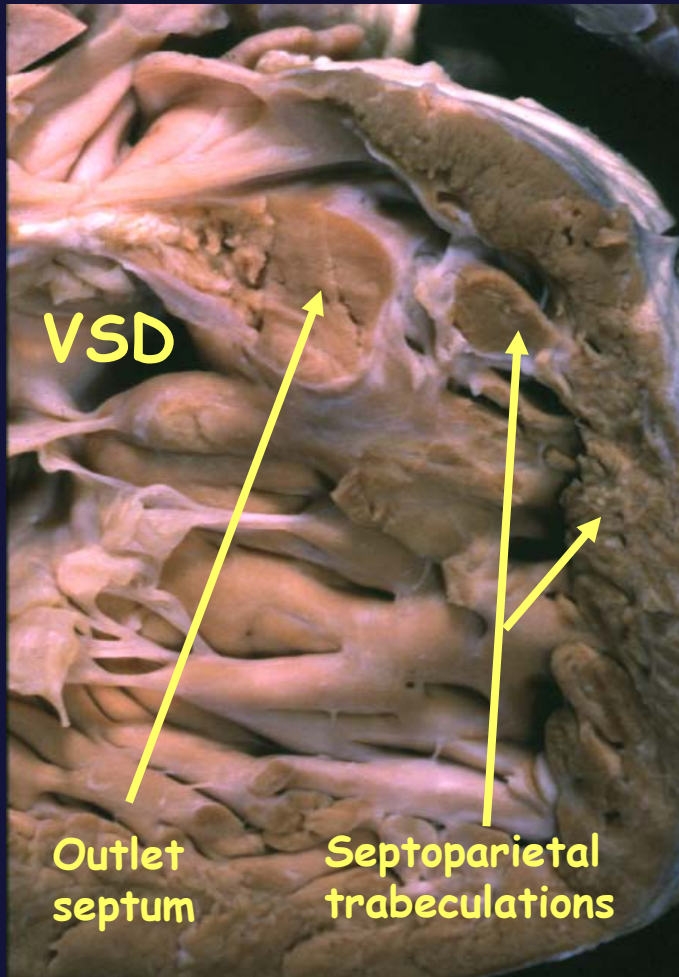


- antero-cephalad deviation of outlet septum
- hypertrophied septoparietal trabeculations



Anatomy of unrepaired Tetralogy of Fallot

Characteristic morphologic features



Anatomy of unrepaired Tetralogy of Fallot

Variable morphologic features

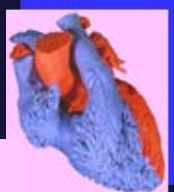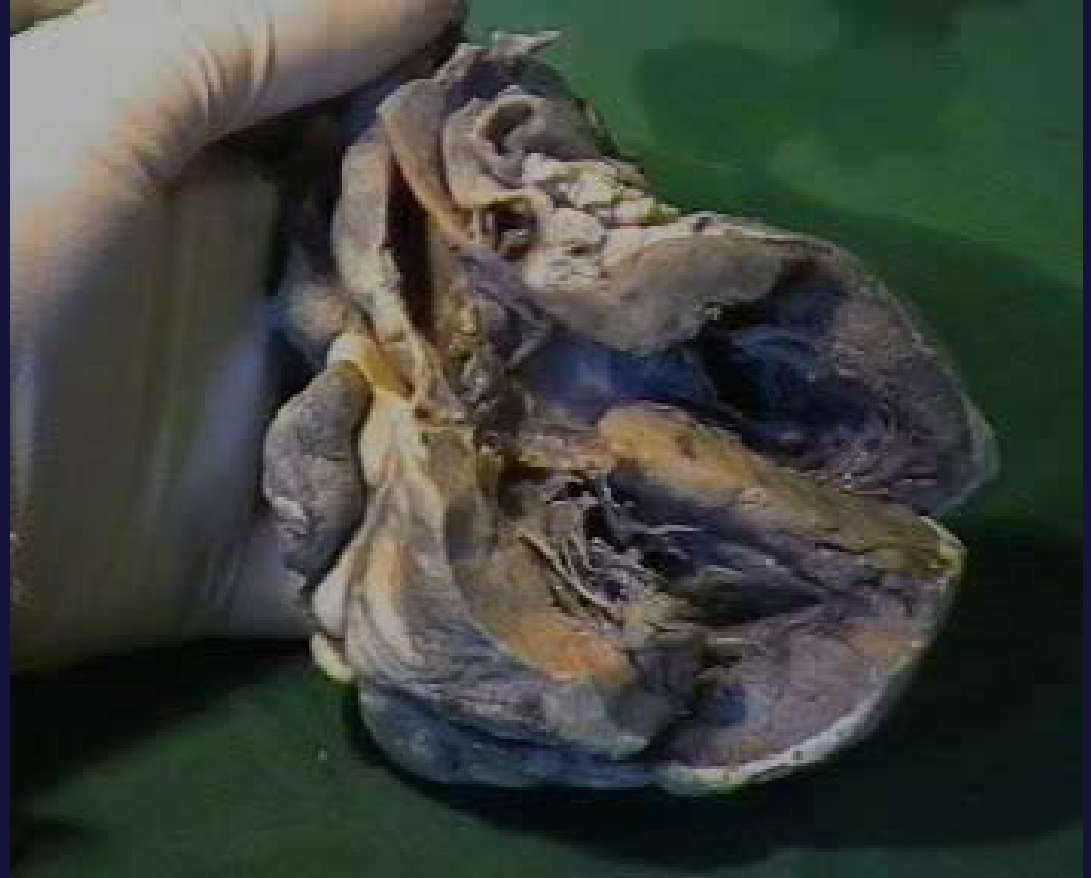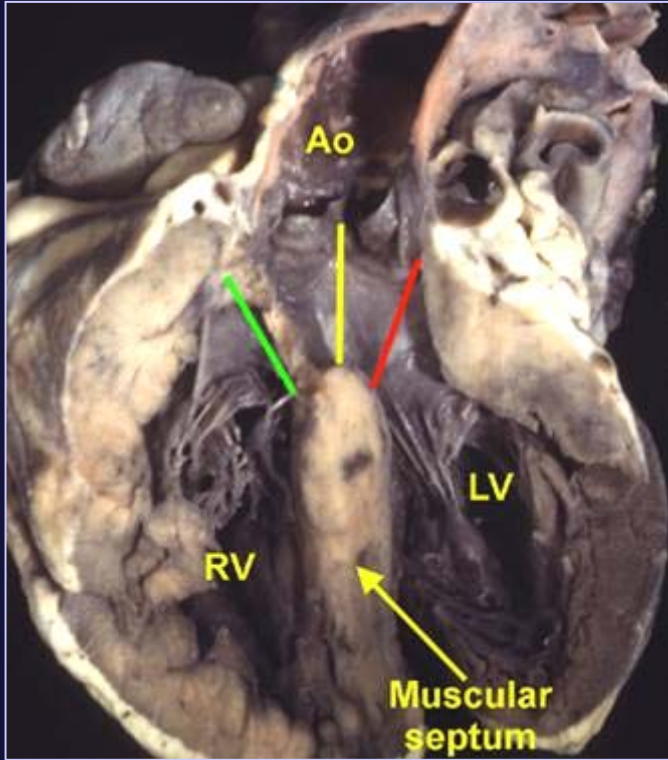
- Extent of aortic override
- Right ventricular margins of VSD
- Nature of sub-pulmonary obstruction
- Associated malformations



Cardiac Morphology

Anatomy of unrepaired Tetralogy of Fallot

Overriding aorta



Variability in Aortic Override

- Aorta predominantly supported by left ventricle
(effectively **concordant connections**)
- Aorta predominantly supported by right ventricle
(effectively **double outlet connection**)

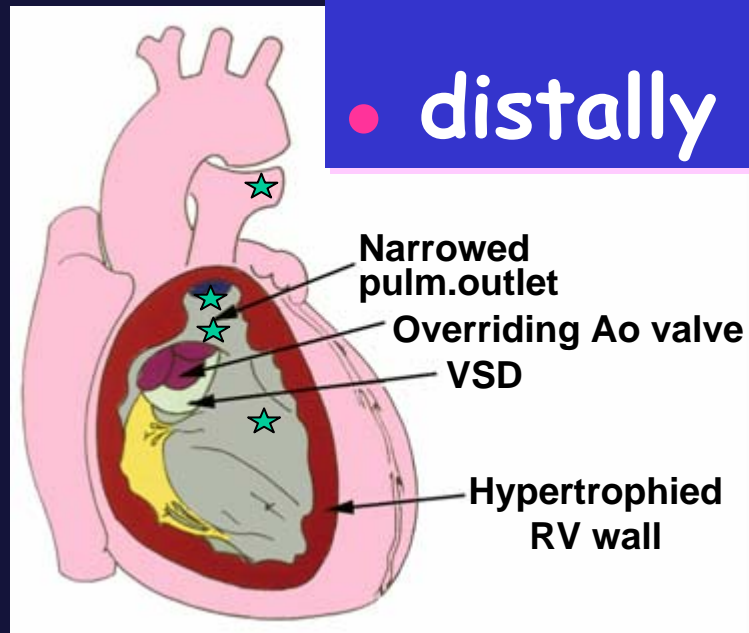


Cardiac Morphology

Anatomy of unrepaired Tetralogy of Fallot

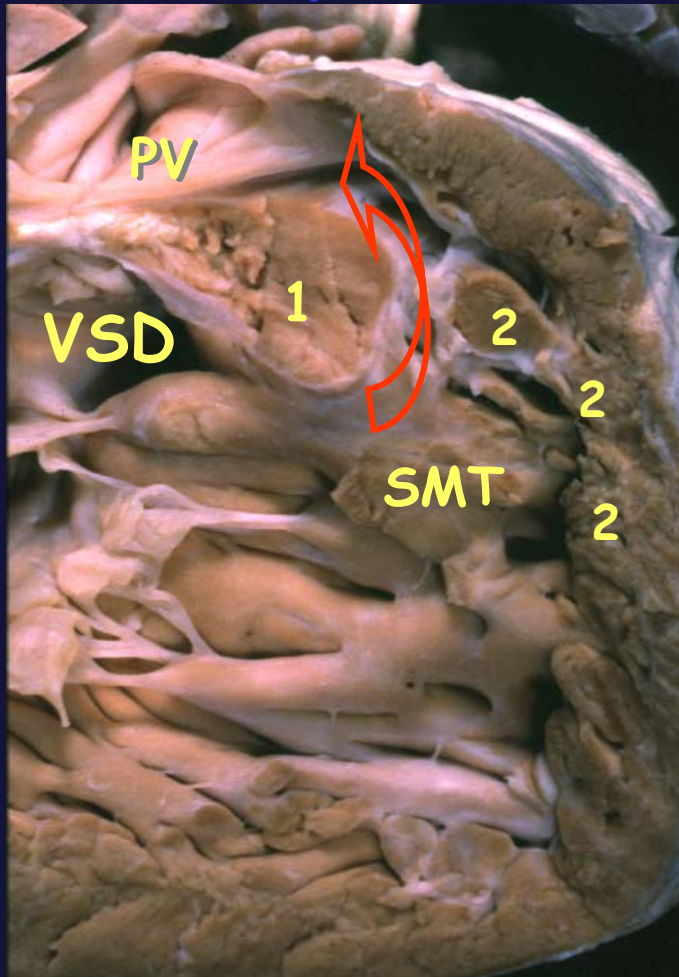
Pulmonary stenosis : levels

- at mouth of infundibulum
- pulmonary valve
- within body of right ventricle
- distally within pulmonary arteries



Anatomy of unrepaired Tetralogy of Fallot

Pulmonary stenosis: anatomic substrates



1. Outlet septum

2. Septoparietal trabeculations

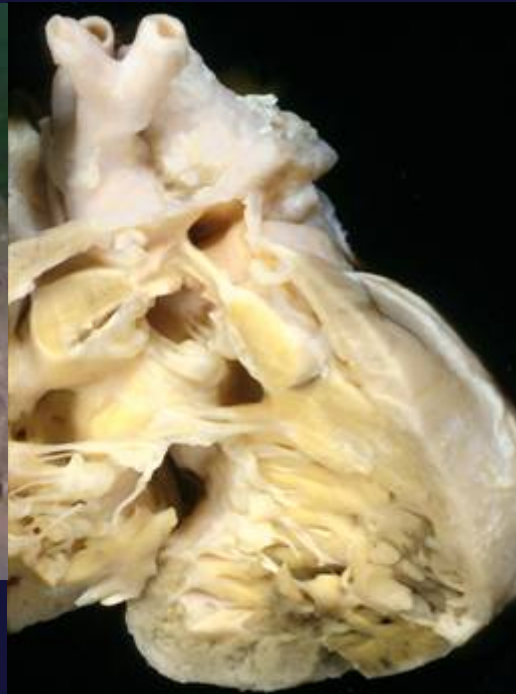
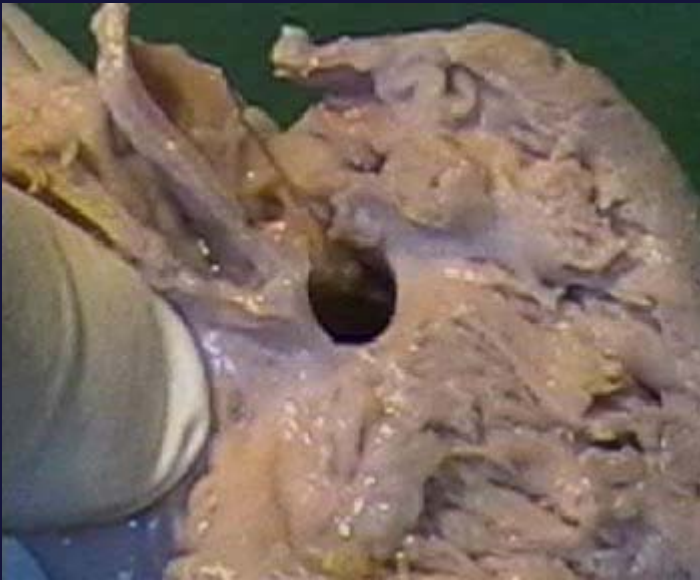SMT Septomarginal trabeculation

PV Pulmonary valve

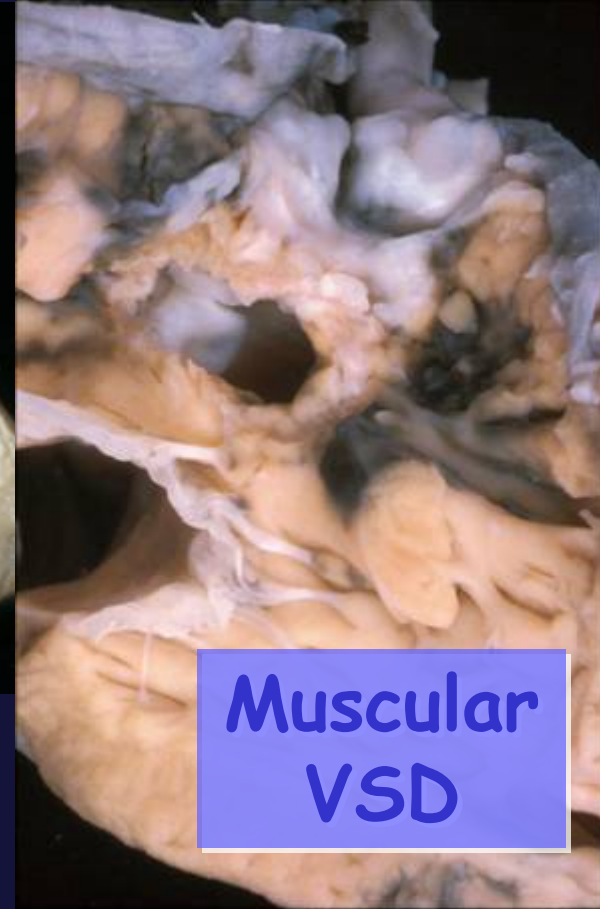


Anatomy of unrepaired Tetralogy of Fallot

Ventricular septal defect



Perimembranous VSD



**Muscular
VSD**

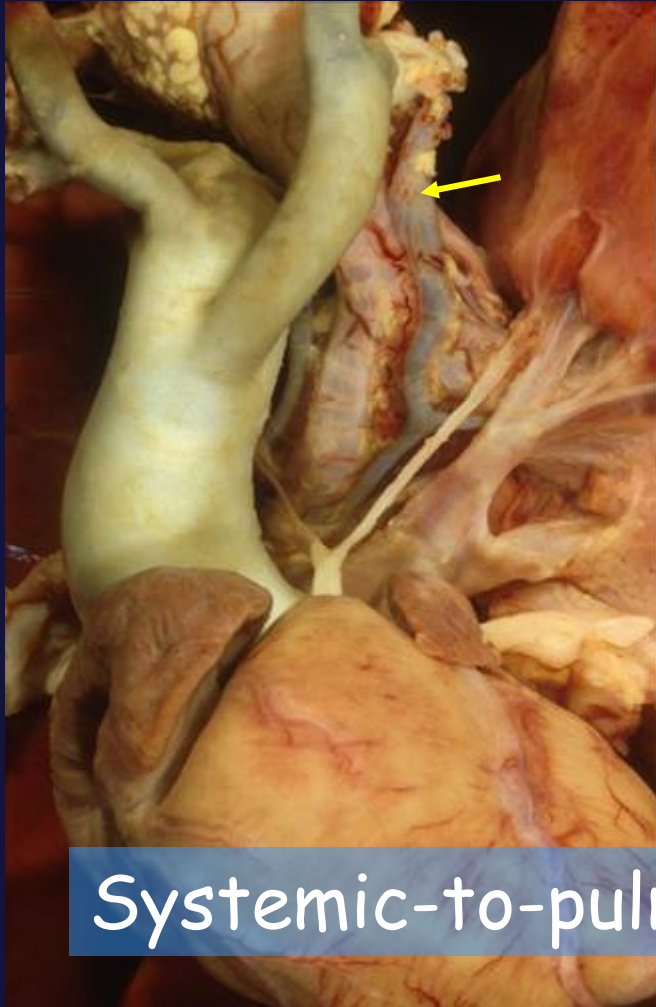
Anatomy of unrepaired Tetralogy of Fallot

Associated malformations

- Pulmonary atresia
- “Absent” leaflets of pulmonary valve
- Straddling tricuspid valve
- Atrioventricular septal defect
- Coronary arterial anomalies
- Right aortic arch
- Muscular inlet VSD

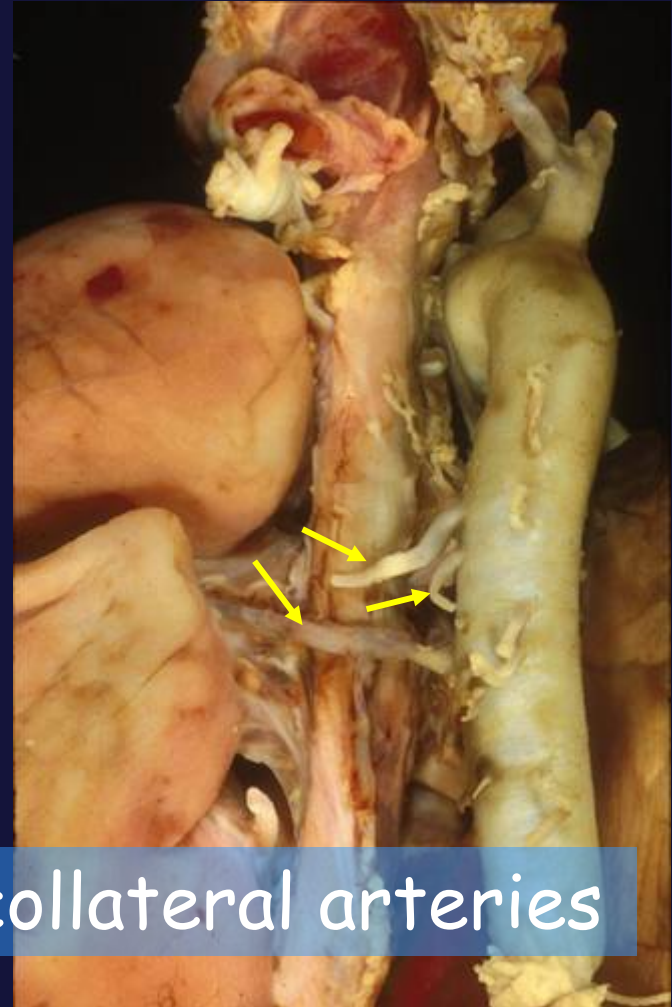
Anatomy of unrepaired Tetralogy of Fallot

Features complicating pulmonary supply



Systemic-to-pulmonary collateral arteries

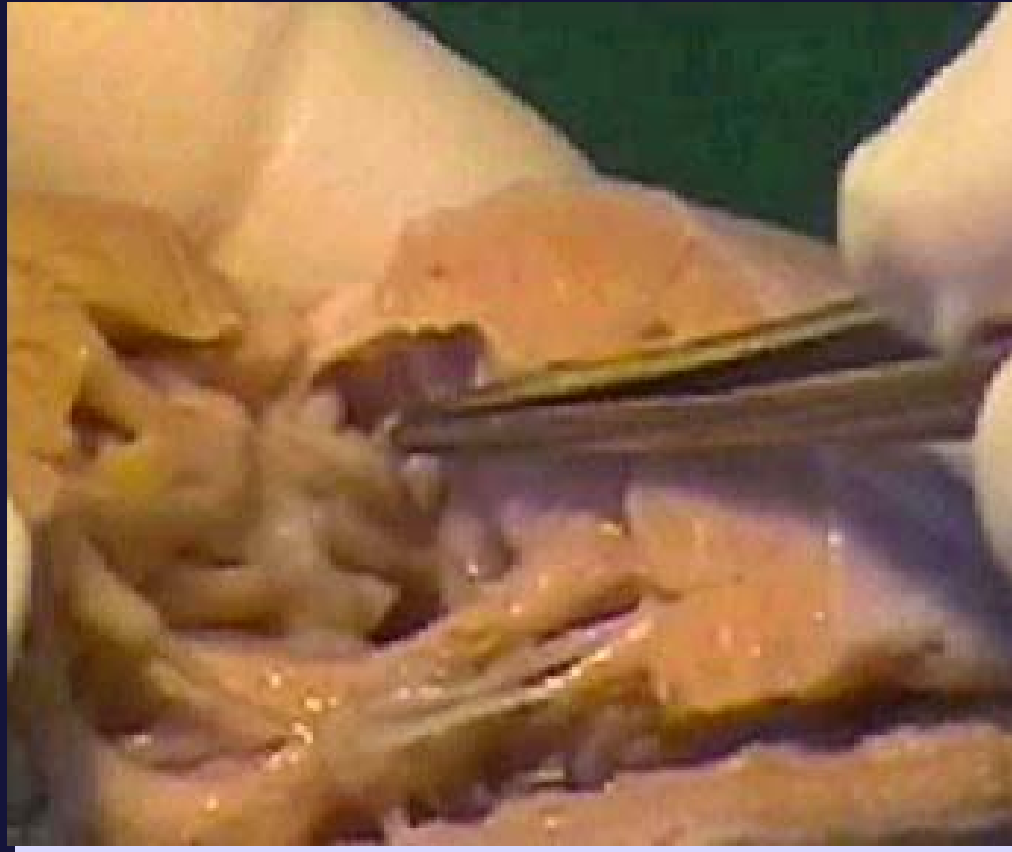
Pulmonary atresia



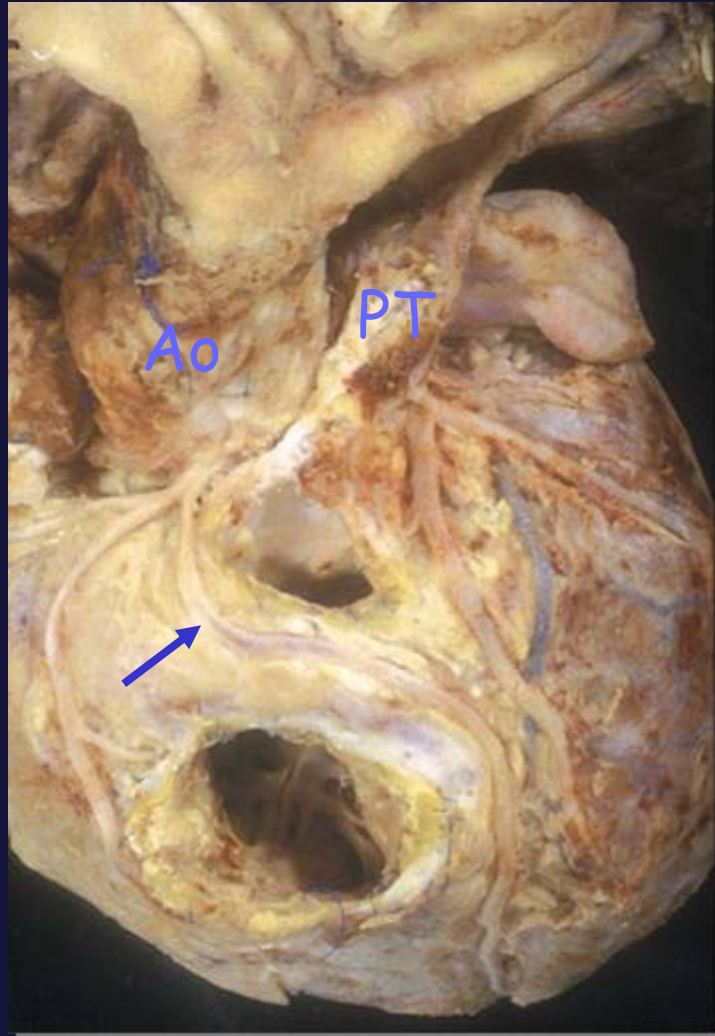
Collateral arteries

Anatomy of unrepaired Tetralogy of Fallot

'Absent' pulmonary valve



Anatomy of unrepaired Tetralogy of Fallot Coronary artery anomaly



Cardiac Morphology

Anatomy of unrepaired Tetralogy of Fallot

