

Standard heart rate variability spectral analysis: does it purely assess cardiac autonomic function?

L. Sidorenko^{1,2}, J.F. Kraemer², and N. Wessel^{2*}

¹State University of Medicine and Pharmacy "Nicolae Testemitanu", Chişinău, Republic of Moldova; and ²Humboldt-Universität zu Berlin, Berlin, Germany

* Corresponding author. E-mail address: wessel@physik.hu-berlin.de

In the 24-h ambulatory Holter electrocardiogram (ECG) recording of a 20-year-old woman, a non-sustained ventricular tachycardia (VT) was identified and a large amount, about 5000, ventricular premature complexes (VPCs) were detected. To ascertain the reason for the said VT and VPCs, a differential diagnosis of idiopathic VT was performed, including 12-lead ECG, 24 h Holter recording, echocardiography, ergometry, and cardiac MRI. These excluded structural reasons. Therefore, the cardiac autonomic function was assessed via heart rate variability (HRV) analysis using methods in both time and frequency domains at multiple points in time throughout the day.¹ We recorded 5-min resting ECGs in supine position and 6-min orthostatic test ECGs, respecting an individual recovery period of 5–20 min (depending on the reported previous activity level) before the first measurement to achieve signal stationarity. During the resting measurements, no VPCs were detected, and no marked differences were found between the different times of day. According to the results of standard HRV spectral analysis, without taking respiration in consideration, a remarkably increased sympathetic activity (LF) was found in the resting state (cf. Figure 1 A) with a strongly decreased level of parasympathetic regulation of the heart rhythm (HF). Following this interpretation, a therapy with β -blockers would be recommended. To allay suspicions of a respiratory induced shift of the spectrum to the LF band, we also analysed respiration here.² From the resting measurement, we extracted the ECG-derived respiration (EDR). This

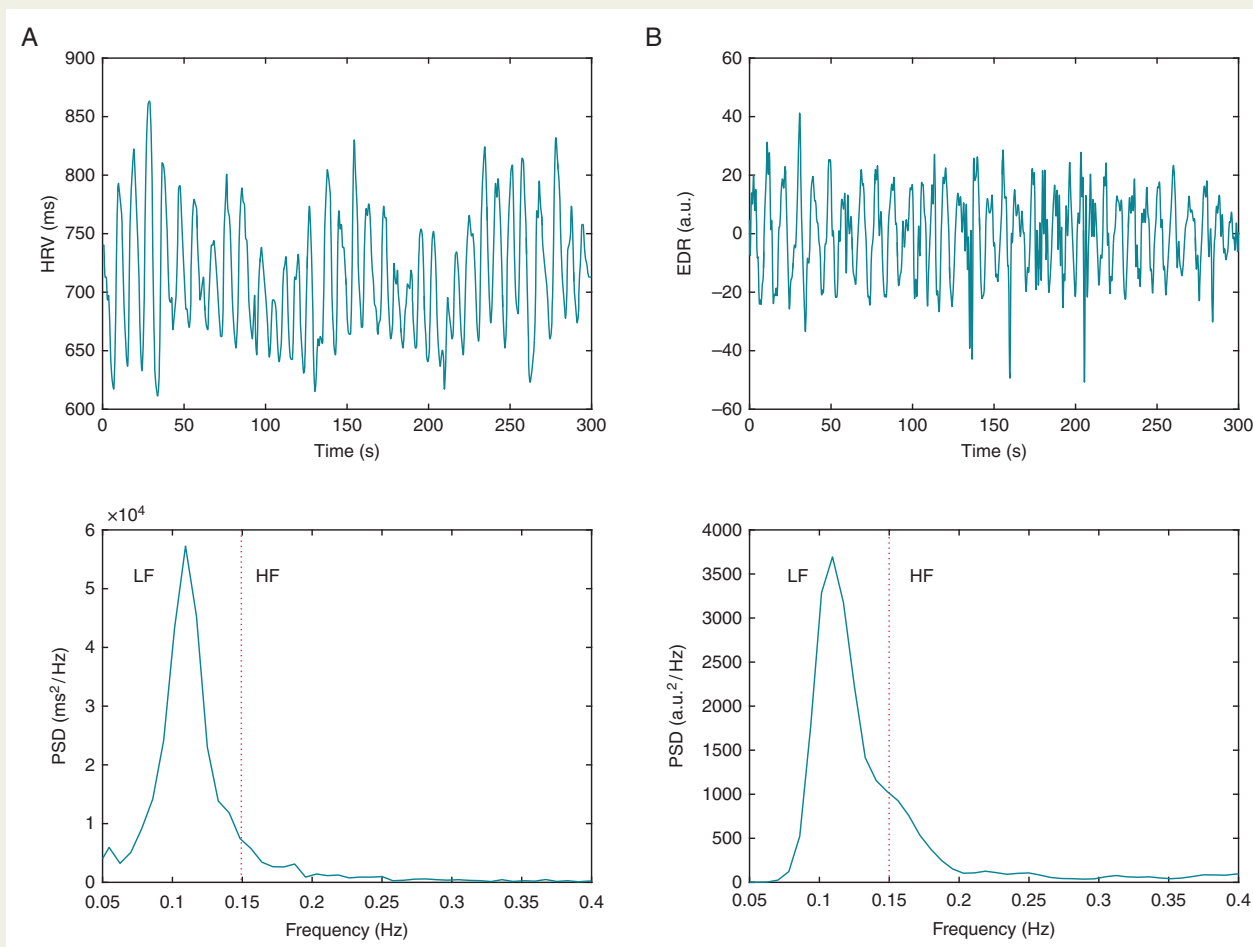


Figure 1 (A) Five minute heart rate variability recording of a 20-year-old woman with previously diagnosed non-sustained ventricular tachycardia while recording sinus rhythm with the corresponding power spectral density and (B) the electrocardiogram-derived respiration estimated from the electrocardiogram morphology as well as its power spectral density.

approach is based on the fact that the positions of ECG electrodes move relative to the heart, and transthoracic impedance varies, as the lungs fill and empty. The EDR can be reliably obtained under resting conditions even in case of cardiac disease. Looking at the spectral analysis of both the EDR (cf. *Figure 1B*) and HRV (cf. *Figure 1A*) we see an almost identical picture; leading to the conclusion that respiration is clearly dominating the HRV. It follows that the 20-year-old woman does not have a sympathetic overactivation, but a situational changed respiratory pattern, shifting the whole spectrum to the LF band. Hence, β -blockers are not the appropriate therapy and standard heart rate variability analysis should incorporate at least respiration rate.

Conflict of interest: none declared.

References

1. Heart rate variability: standards of measurement, physiological interpretation and clinical use. Task Force of the European Society of Cardiology and the North American Society of Pacing and Electrophysiology. *Circulation* 1996;**93**:1043–65.
2. Wessel N, Riedl M, Kurths J. Is the normal heart rate “chaotic” due to respiration? *Chaos* 2009;**19**:028508.