

Possible late diagnosis of the Brugada syndrome in a patient presenting with a primary cardiac arrest

Peter T. Moore and Gerald C. Kaye*

Department of Cardiology, Princess Alexandra Hospital, 199 Ipswich Road, Wollongabba, QLD 4102, Australia

* Corresponding author. Tel: +61 07 3176 2383; fax: +61 07 3176 7630. E-mail address: gerald.kaye@health.qld.gov.au

A 38-year-old male was successfully resuscitated from an out of hospital ventricular fibrillation arrest. Extensive investigation, including flecainide challenge, did not reveal a cause. An implantable cardioverter-defibrillator was implanted without recurrence of arrhythmia. During generator change and RV Riata lead testing 9 years later, electrograms revealed a transient Brugada pattern after cardioversion, possibly indicative of a late diagnosis of Brugada syndrome.

A 38-year-old male suffered an out of hospital ventricular fibrillation (VF) cardiac arrest. On arrival of emergency services, he was cardioverted to sinus rhythm after multiple defibrillations. The post-reversion 12-lead electrocardiogram (ECG) was normal. Clinical history, examination, and blood tests were unremarkable. Family history was negative for premature sudden cardiac death. Coronary angiography showed no coronary artery disease. Left ventricular function was normal on echocardiogram and cardiac magnetic resonance imaging was also normal. Electrophysiology testing was non-contributory and a flecainide challenge test was negative. An implantable cardioverter-defibrillator (ICD) with an active fixation dual-coil Riata lead (St Jude Medical, Minneapolis, MN, USA) was implanted. During 9-year follow-up, no ventricular arrhythmias were detected. At routine clinical follow-up over 9 years, ECGs remained normal and showed no change compatible with the Brugada syndrome.

During scheduled generator change 9 years after implant, testing of the Riata right ventricular lead was performed. Under anaesthesia, an R wave synchronized shock of 33 J was delivered between the generator can and the distal shock coil. Lead shock impedance was normal at

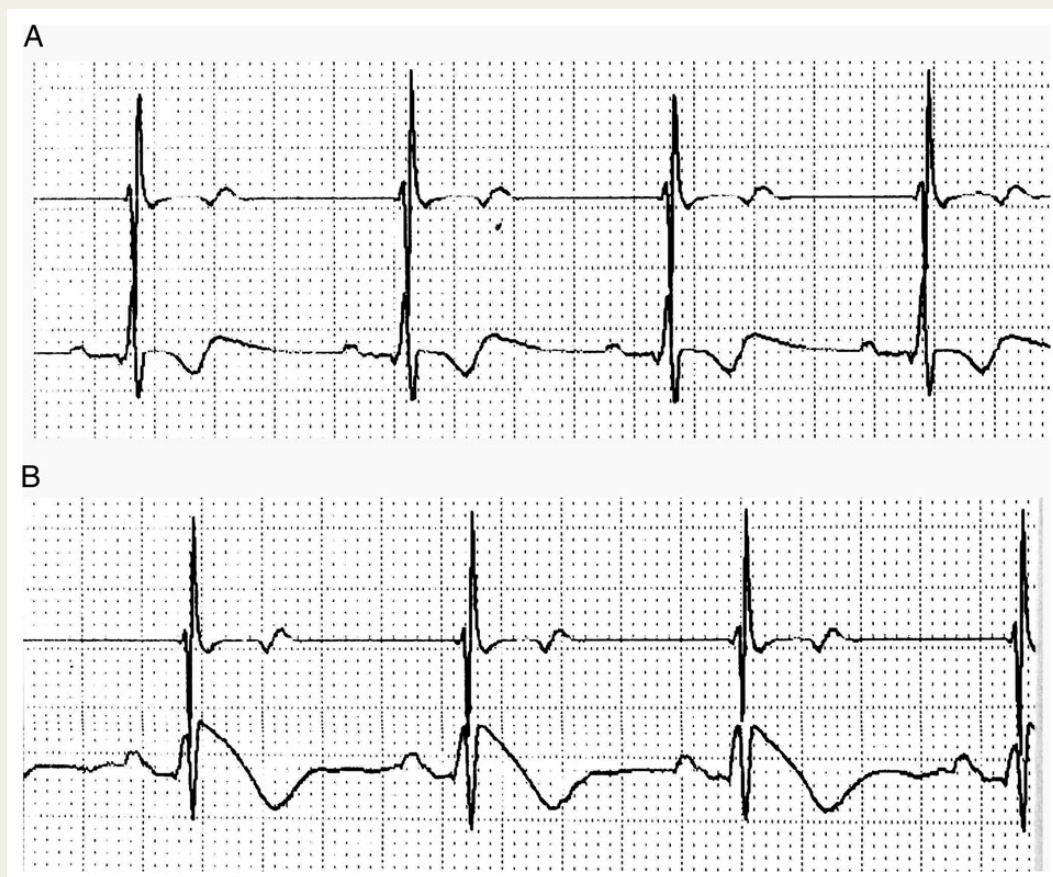


Figure 1 Intracardiac electrograms immediately prior to (A) and after (B) the test shock.

69 Ω . Intracardiac electrograms (EGMs) were recorded between the superior vena cava coil and generator prior to lead testing (Figure 1 A) and immediately post-test (Figure 1B). The EGM immediately after the shock showed a transient, upwardly coved elevation compatible with a Type 1 Brugada pattern (Figure 1B), which reverted to baseline within 1 min. The rapidity of change in the EGM did not provide time for a 12-lead surface ECG to be recorded to confirm the ST segment changes. Although it is possible that the EGM changes could represent a transient repolarization abnormality after cardioversion, at our centre routine intracardiac EGM monitoring is performed during Riata lead testing at generator change, and no similar recordings have been noted previously.

The sensitivity of a pharmacological challenge in diagnosing Brugada syndrome varies across studies. Brugada *et al.*¹ demonstrated 100% sensitivity for 45 patients with documented Brugada or a positive genotype challenged with flecainide, procainamide or ajmaline. Priori *et al.*² elicited 35 positive flecainide or ajmaline challenges in 41 patients (85.5%) with diagnosed Brugada, but only 2 of 13 (15%) silent gene carriers. In 677 patients, who underwent ajmaline testing, Veltmann *et al.*³ identified the absence of ST elevation in the right precordial leads predicted a negative test. Although ajmaline is considered more sensitive for the diagnosis of Brugada syndrome,³ it is not available in Australia.

This case exemplifies a potentially unique discovery of probable Brugada syndrome on ICD lead testing 9 years after a primary VF arrest when ECGs and a single flecainide challenge test were negative, and emphasizes the transient nature of the ECG changes.

Conflict of interest: none declared.

References

1. Brugada R, Brugada J, Antzelevitch C, Kirsch GE, Potenza D, Towbin JA *et al.* Sodium channel blockers identify risk for sudden death in patients with ST-segment elevation and right bundle branch block but structurally normal hearts. *Circulation* 2000;**101**:510–5.
2. Priori SG, Napolitano C, Gasparini M, Pappone C, Della Bella P, Brignole M *et al.* Clinical and genetic heterogeneity of right bundle branch block and ST-segment elevation syndrome: a prospective evaluation of 52 families. *Circulation* 2000;**102**:2509–15.
3. Veltmann C, Wolpert C, Sacher F, Mabo P, Schimpf R, Streitner F *et al.* Response to intravenous ajmaline: a retrospective analysis of 677 ajmaline challenges. *Europace* 2009;**11**: 1345–52.