

Contrast for detection of apical thrombus

Clinical Case Portal

Date of publication:

01 Dec 2011

Topics: Echocardiography (Non-invasive imaging)
Non-invasive imaging: Echocardiography, MR/CT, Nuclear

Authors:

Reidar Winter

Reviewers: Benoy Shah, Roxy Senior

Abstract

Case from the [Contrast Echo Box](#)
[Contrast Echocardiography for assessment of LV structure and function](#)

Introduction

- 45 year old male
- 164 cm/155 kg – Body mass index 57.6
- Past AMI and established heart failure:
- EF 40 % (2000)
- Drug abuse in the past
- Admitted due to shortness of breath

Not taken "some medications", ECHO in the CCU

Case Report

2D echocardiogram (fig 1)

Due to suboptimal image quality, 1 ml SonoVue bolus was given

Contrast echocardiogram (fig 2)

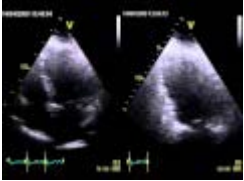
There was no suspicion of a thrombus in the grey scale images in this particular case, contrast was thus given only for LVO and the thrombus was in fact a random finding.

Conclusion

The case illustrates a possibility of an additional value from contrast echo that cannot always be predicted.

Video 1 :

[2D echocardiogram](#)



Video 2 :

[Contrast echocardiogram](#)

