

Detailed Anatomical Assessment of Degenerative Mitral Regurgitation

Clinical Case Portal

Date of publication:

21 Oct 2011

Authors:

Prof. Andreas Hagendorff

Authors details:

Universitat Leipzig

Contact:

[Email](#)

Abstract

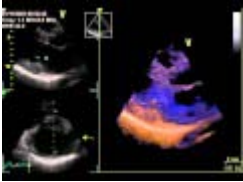
Echo study of a 56 year old woman who was symptomatic per dyspnea on effort and intermittent atrial fibrillation.

Introduction

Her first event of acute dyspnea occurred 4 years before present admission to our hospital. Her physical examination was remarkable for an apical pansystolic murmur irradiating to the axilla.

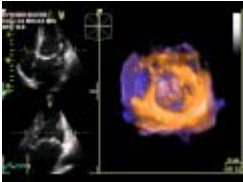
Video 1 :

[Single-beat full-volume 3D parasternal long-axis view of the heart](#)



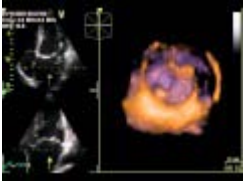
Video 2 :

[Single-beat full-volume 3D apical view](#)



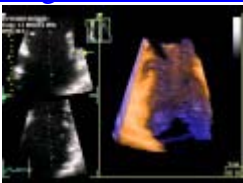Video 3 :

[Single-beat full-volume 3D apical view](#)



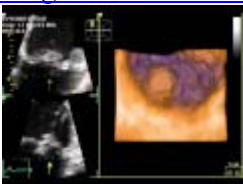Video 4 :

[Single-beat 3D zoom mode from apical 2-chamber or commissural 3D view](#)



Video 5 :

[Single-beat 3D-zoom apical view](#)



Video 6 :

[Single-beat 3D-zoom apical view](#)

