

Carcinoid Tricuspid Regurgitation

Clinical Case Portal

Date of publication:

27 Nov 2008

Topics: Valvular Heart Diseases

Echocardiography (Non-invasive imaging)

Non-invasive imaging: Echocardiography, MR/CT, Nuclear

Authors:

Prof. Andreas Hagendorff

Authors details:

Universitat Leipzig

Contact:

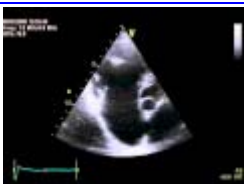[Email](#)

Abstract

Echo study obtained from a 65 year old female patient

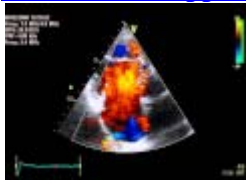
Video 1 :

[Two-dimensional short axis view](#)



Video 2 :

With color Doppler



Video 3 :

A severe tricuspid regurgitation

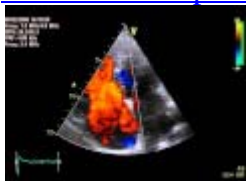


Fig. 1 :

Continuous wave Doppler spectrum

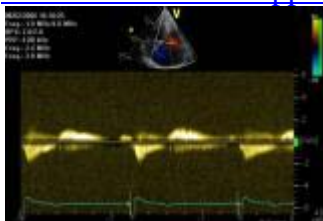
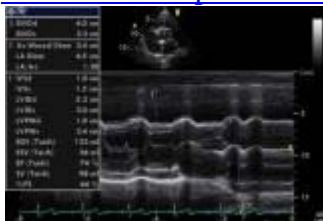


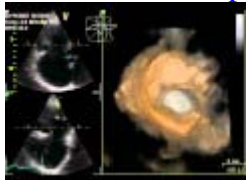
Fig. 2 :

M-Mode-Sweep and measurements



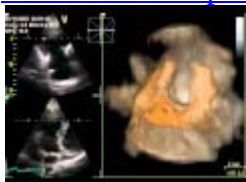Video 4 :

Full-volume 3D apical view



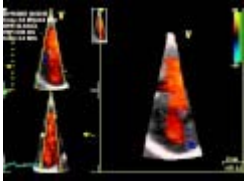
Video 5 :

Full-volume 3Dparasternal view




Video 6 :

[Full-volume color-coded apikal 3D view](#)



Video 7 :

[Full-volume color-coded apikal 3D view](#)



Video 8 :

[Two-dimensional 2-chamber view](#)

