Transcatheter Embolization of Non Bronchial Systemic Artery In Patient With Recurrent Hemoptysis

Clinical Case Portal

Date of publication:

29 Dec 2005

Topics: Invasive Imaging: Cardiac Catheterisation and Angiography

Authors:

Filippo Scalise, MD, FSCAI; Marco Papa, MD; Carla Auguadro, MD; Mariella Manfredi MD, Giuseppe Specchia MD, FACC. – Catheterization Laboratory – Policlinico di Monza – Monza, Italy Contact: filippo.scalise@policlinicodimonza.it

Case Report

A 36 years old female patient was addmitted to the our hospital for recurrent hemoptysis.
Thoracic MR Scan showed a large non bronchial systemic arterial anomalous collateral branch arising from the aortic arch.
Angiography of the thoracic aorta associated with selective angiography of the anomalous vessel confirmed the diagnosis.
Coils embolization of the anomalous vessel was successfully performed.

Patient history prior to current observation :

A 37 year old female patient was referred to our hospital with a history of recurrent hemoptysis.
Chest X Ray was negative.

Clinical findings on admission, evolution and outcome :

Chest MRI shows the presence of non bronchial systemic arterial collateral branch from the aortic arch to the right lung (lower lobe).
We performed thoracic aortography and selective aomalous vessel angiography for

confirmation fig. 1. Intraprocedural measurement of right pulmonary artery saturation was done. We performed closure of this anomalous vessel using coils embolizations device(Flipper detachable embolization coil delivery system - Boston Scientific) (2 coils 5 cm x 5 mm 0.038 inch) fig. 2.
Final angiographic control for anomalous vessel closure confirmation was performed fig. 3.

Conclusion

In patients with recurrent hemoptysis the angiographic study is useful to find the source of the bleeding and to localize the pulmonary lobes where the bleeding comes from.

The presence of non bronchial systemic arterial anomalous collateral should always be suspected in recurrent hemoptysis.

Nonbronchial systemic arterial embolization is a safe and effective nonsurgical solution for patients with recurrent hemoptysis.

References

1) Haponik EF, Fein A, Chin R. Managing life-threatening hemoptysis: has anything really changed? Chest 2000; 118:1431-1435.

2) Mal H, Rullon I, Mellot F, et al. Immediate and long-term results of bronchial artery embolization for life-threatening hemoptysis. Chest 1999; 115:996-1001.

Fig. 1 :
Non bronchial systemic artery_Selective angiography on admission

Fig. 2 :
Non bronchial systemic artery_Coils embolization

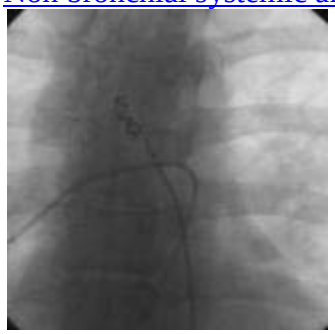

Fig. 3 :

Non bronchial systemic artery_Selective angiography after coils embolization