


EAE Teaching Course
Sofia, 2012

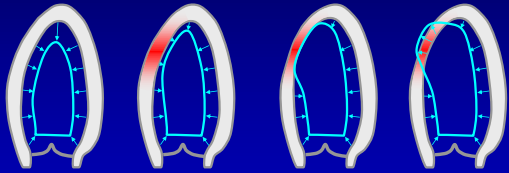


Deformation Patterns in Coronary Disease

Jens-Uwe Voigt
Dpt. of Cardiovascular Diseases
Cath. University Leuven
Belgium

Visual Function Assessment

semi-quantitative „wall motion score“




1 normal 2 hypokinesia 3 akinesia 4 dyskinesia

JU Voigt, University Leuven, Belgium

Visual Function Assessment

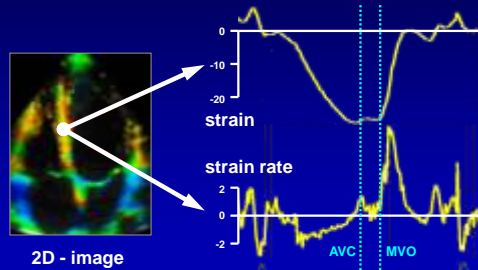
semi-quantitative „wall motion score“



1 normal 2 hypokinesia 3 akinesia 4 dyskinesia

JU Voigt, University Leuven, Belgium

Quantitative Function Assessment



2D - image

JU Voigt, University Leuven, Belgium

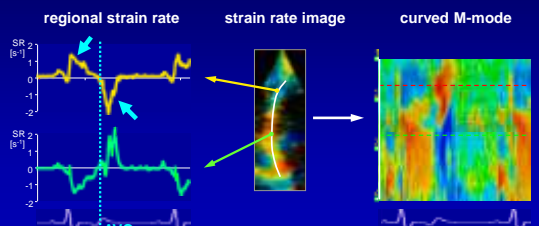
Deformation Imaging

How to Quantify Regional Dysfunction?

JU Voigt, University Leuven, Belgium

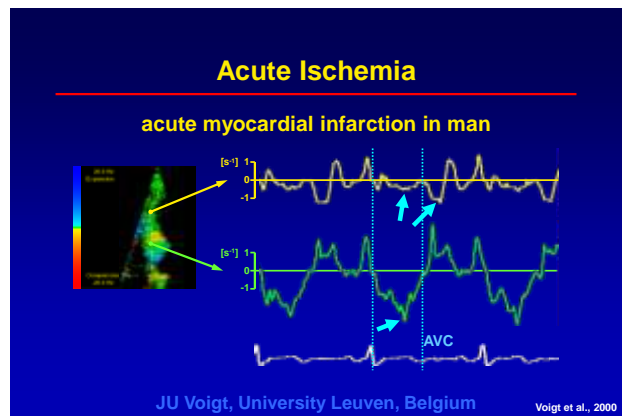
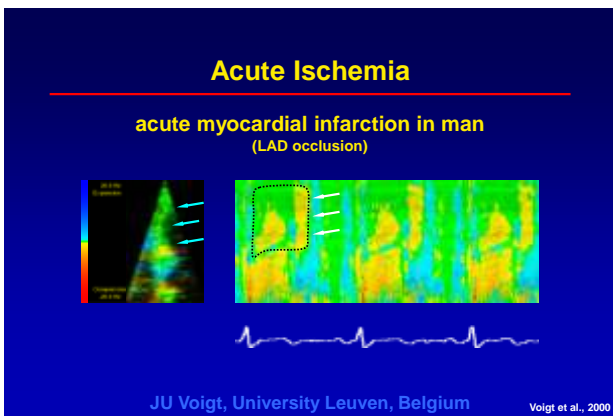
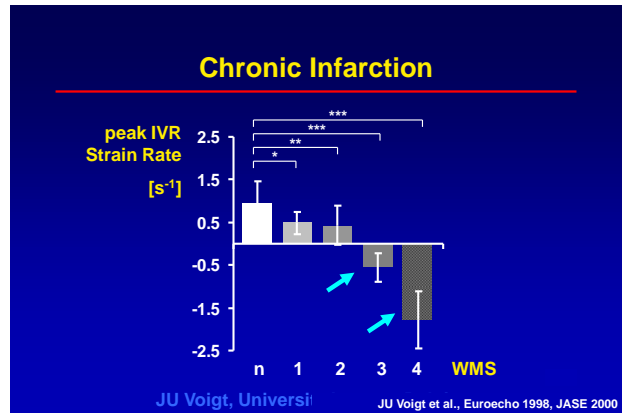
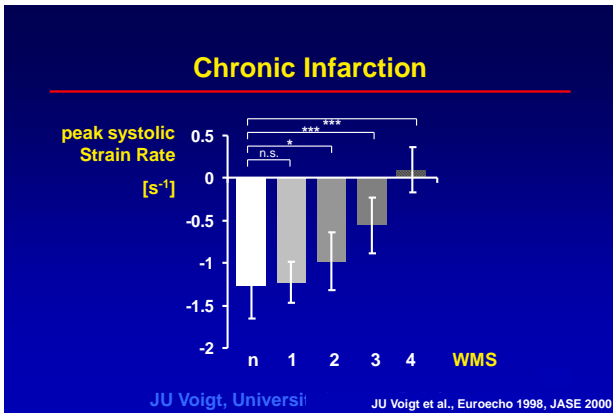
Chronic Infarction

septum with apical dyskinesia



regional strain rate strain rate image curved M-mode

JU Voigt, University Leuven, Belgium JU Voigt et al., Euroecho 1998, JASE 2000

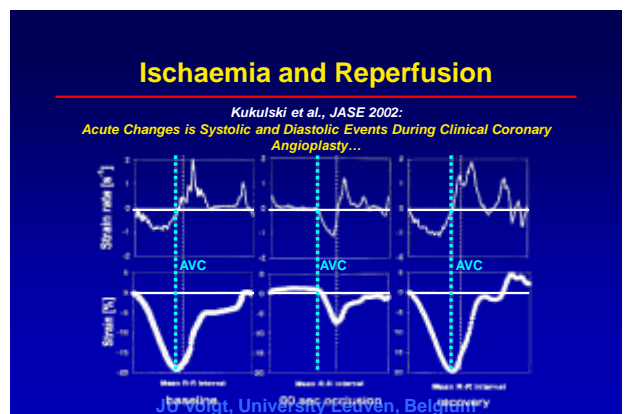


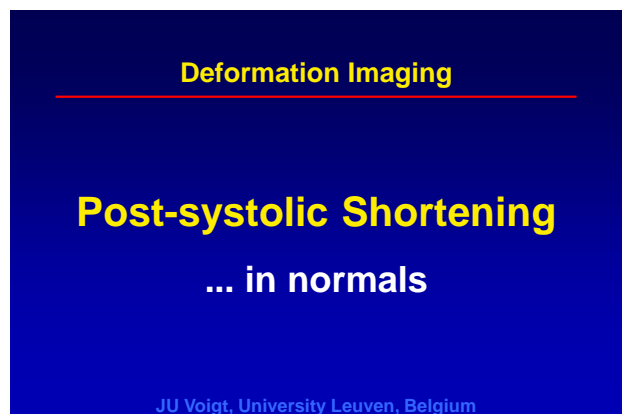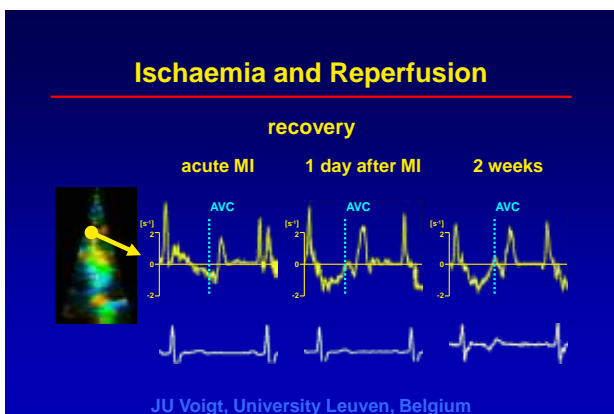
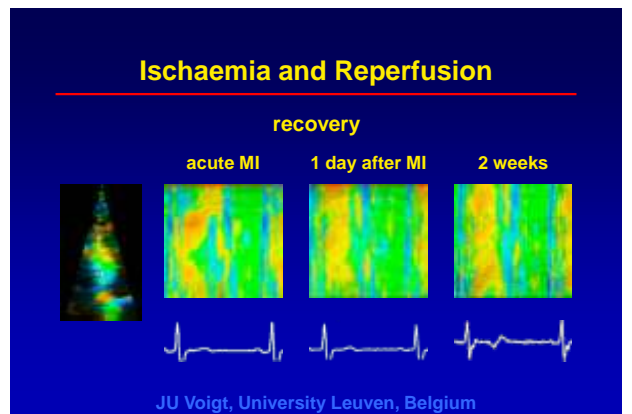

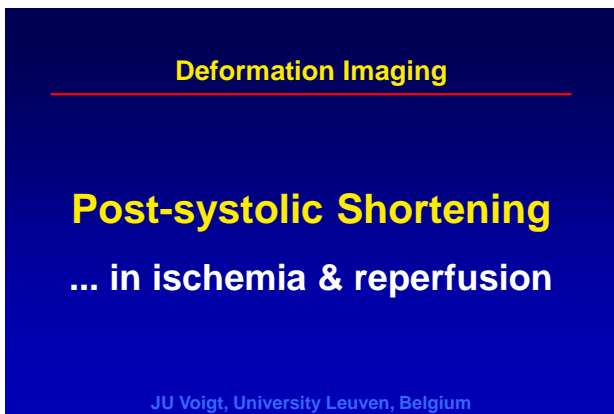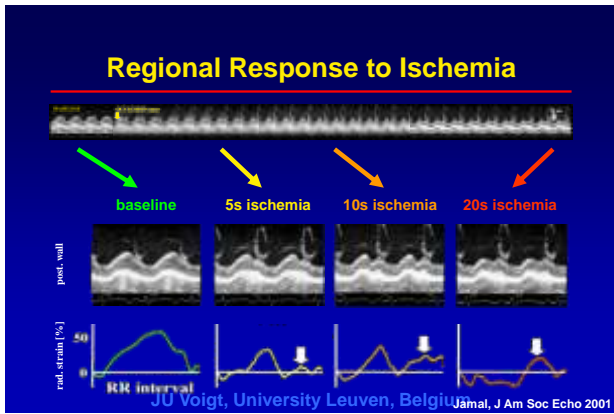
Deformation Imaging

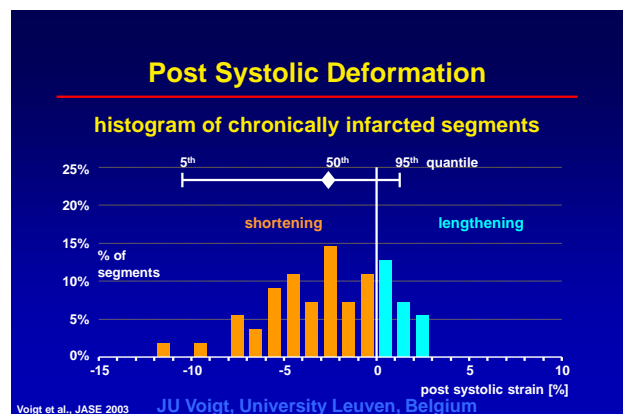
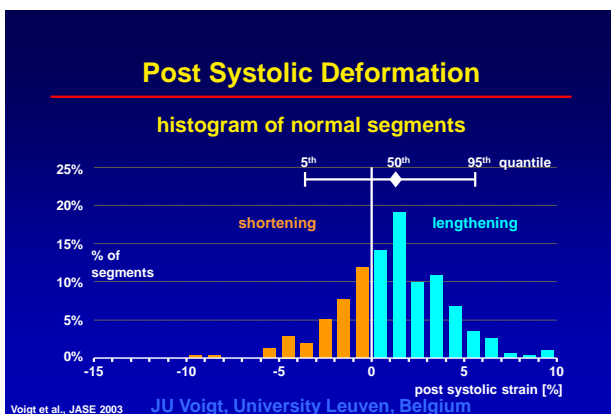
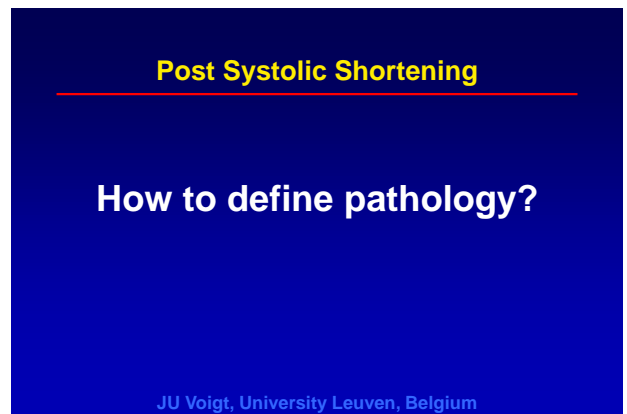
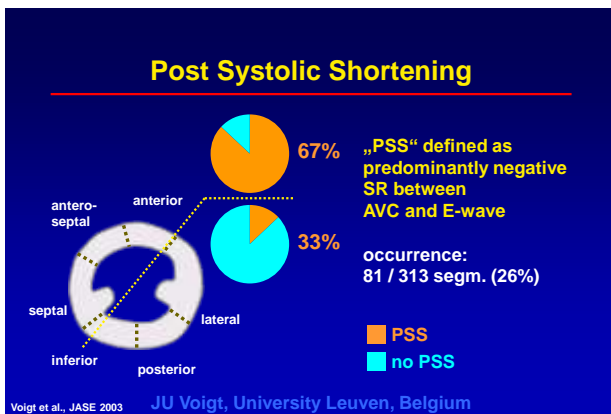
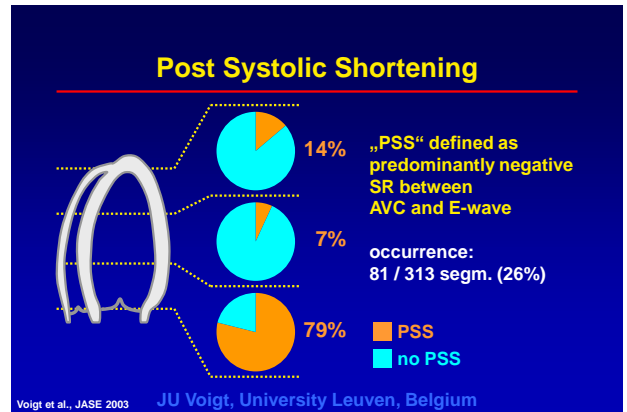
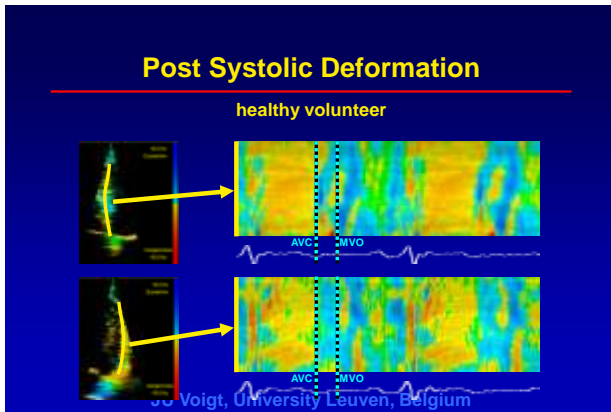
Post-systolic Shortening

... in acute ischemia

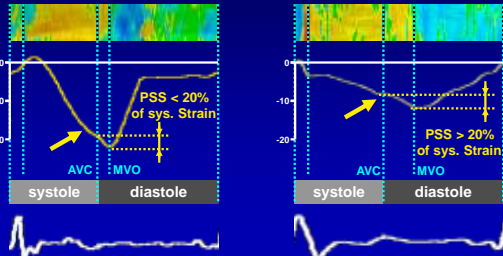
JU Voigt, University Leuven, Belgium







Post Systolic Index



Voigt et al., JASE 2003

University Leuven, Belgium

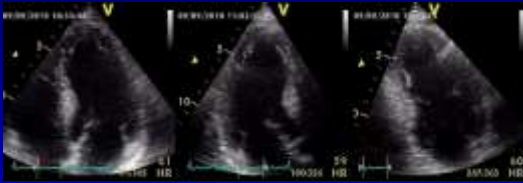Postsystolic Shortening

How to use it Clinically?
Detecting Chronic Scar

JU Voigt, University Leuven, Belgium

Detecting Subtle Dysfunction

post-infarct patient ?




JU Voigt, University Leuven, Belg

Amzulescu / Voigt

Detecting Subtle Dysfunction

post-infarct patient !



JU Voigt, University Leuven, Belg

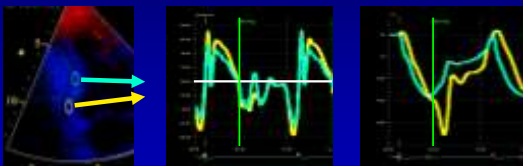
Amzulescu / Voigt

Chronic Infarction

velocity vs. deformation

long. velocity

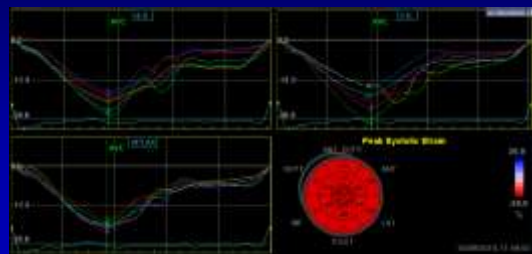
long. strain



JU Voigt, University Leuven, Belgium

Chronic Infarction

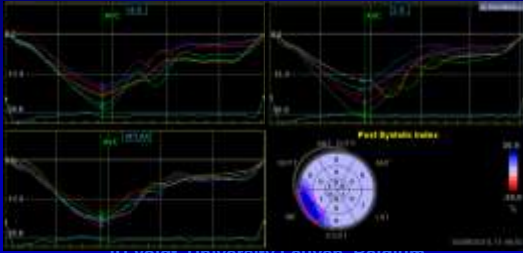
speckle tracking: systolic strain



JU Voigt, University Leuven, Belgium

Chronic Infarction

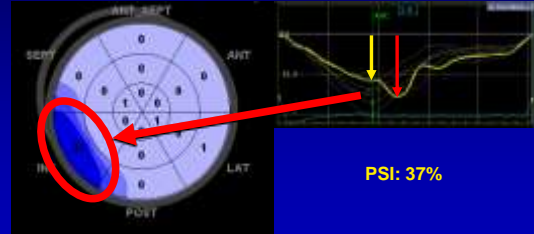
speckle tracking: postsystolic index



JU Voigt, University Leuven, Belgium

Chronic Infarction

speckle tracking: postsystolic index



JU Voigt, University Leuven, Belgium

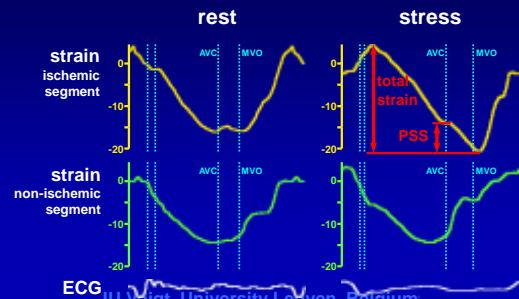
Postsystolic Shortening

How to use it clinically?

Ischemia detection during Stress Echo

JU Voigt, University Leuven, Belgium

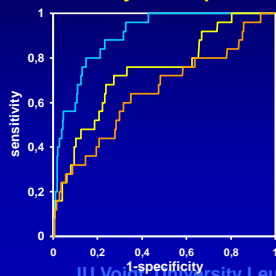
Strain Rate Imaging in Stress Echo



JU Voigt, University Leuven, Belgium Voigt et al., Circulation 2003

Strain Rate Imaging in Stress Echo

ROC analysis of quantitative parameters

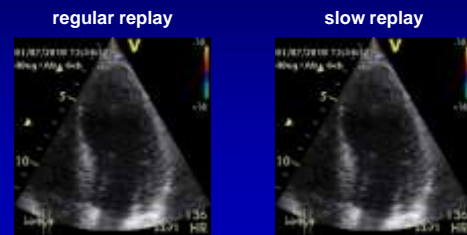

parameter	AUC
PSS	0.90
systolic strain rate	0.74
systolic strain	0.65

JU Voigt, University Leuven, Belgium Voigt et al., Circulation 2003

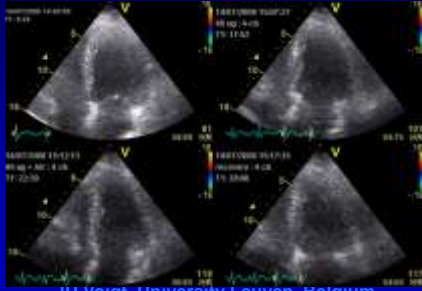
Visual Assessment

post-systolic shortening



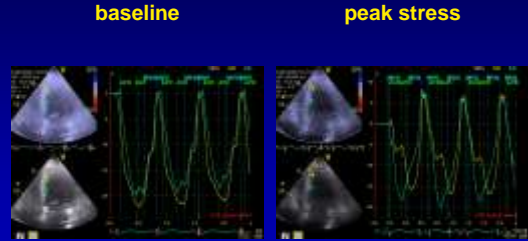
JU Voigt, University Leuven, Belgium

Case: Dobutamine Stress Echo, 4CV



JU Voigt, University Leuven, Belgium

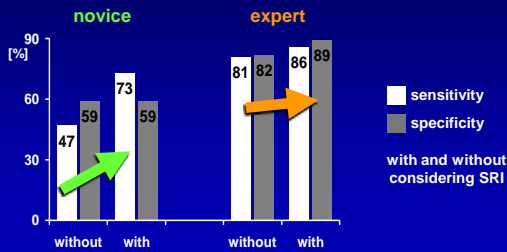
Case: Quantitative Assessment



JU Voigt, University Leuven, Belgium

Strain Rate in Stress Echo

accuracy improvement depends (less) on experience



JU Voigt, University Leuven, Belgium adapted from: Voigt et al., Circulation 2003

Summary

Changes in strain and strain rate patterns are sensitive markers of myocardial dysfunction.

Post-systolic shortening is a characteristic, easy to recognize feature which is hardly affected by noise.

Newly developing post-systolic shortening has a high accuracy for detecting ischemia.

JU Voigt, University Leuven, Belgium