


CORONARY PHYSIOLOGY IN THE CATHLAB:

FFR POST - PCI

***Educational Training Program ESC
European Heart House
april 24th - 26th 2014***



Nico H. J. Pijls, MD, PhD
Catharina Hospital,
Eindhoven, The Netherlands



FFR post PCI

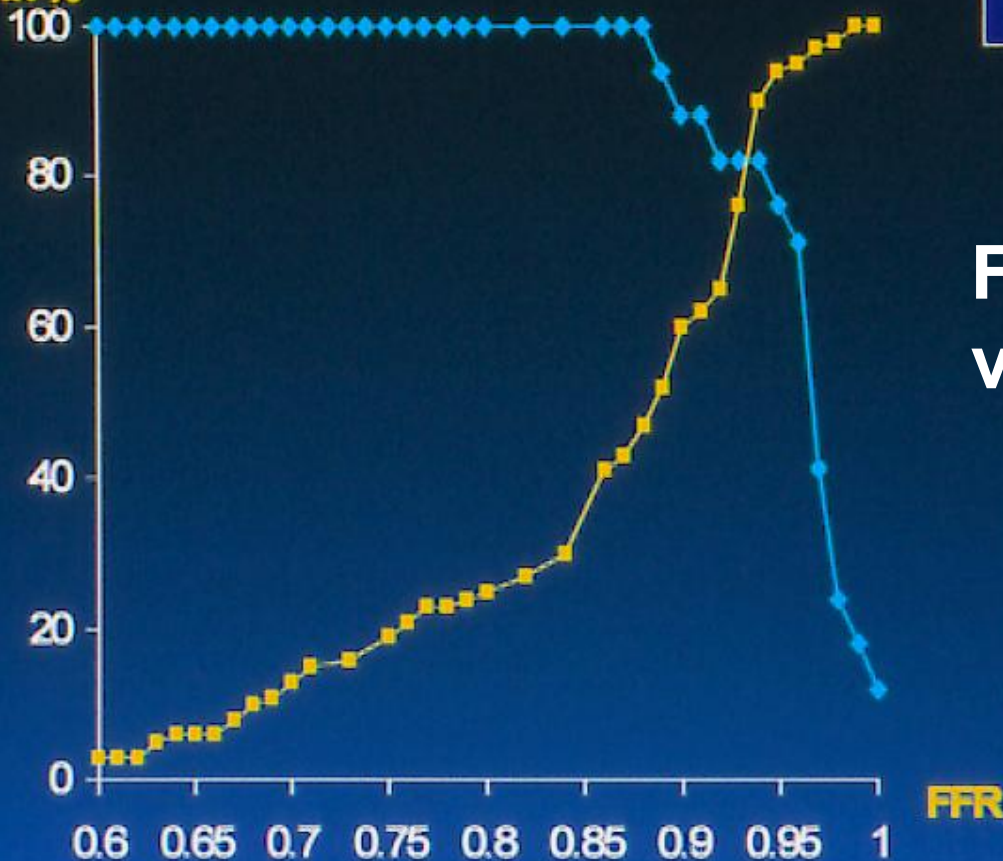
Do we have systematic data?

→ only a few good studies

Because the extreme heterogeneity of patients (inherent to the nature of coronary artery disease) there does not exist one single “uniform” FFR post-stent value indicative for a good result)

Nevertheless, FFR post-stent can give very useful Information, if measured and interpreted in the right way

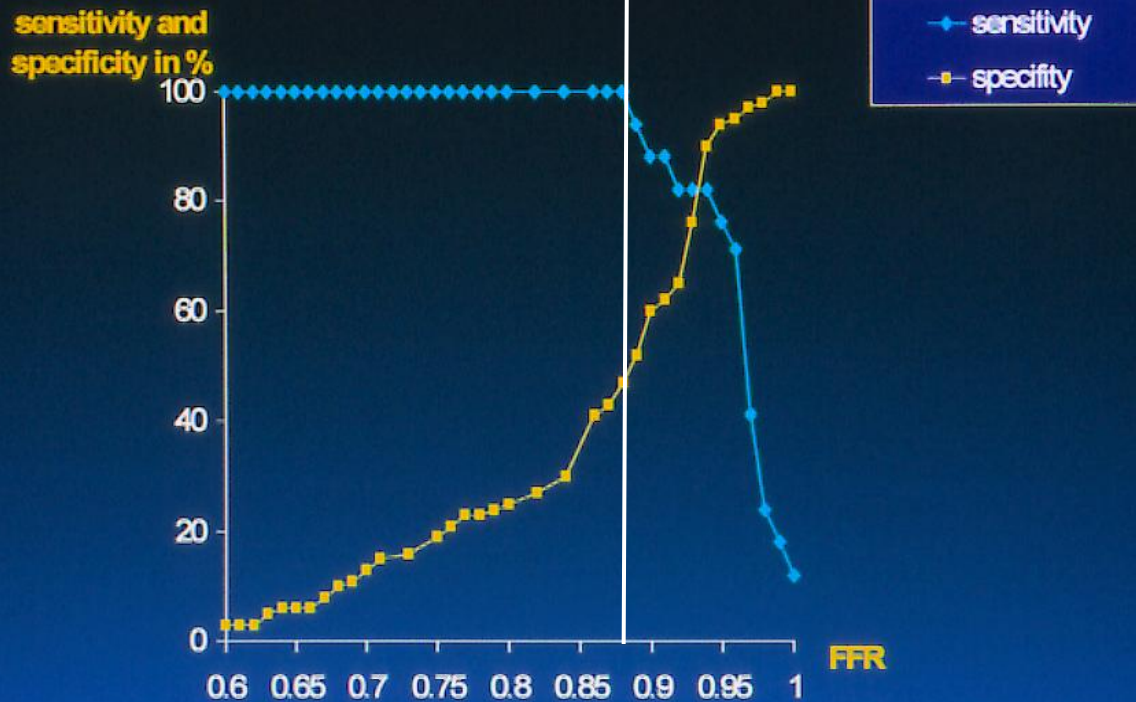
sensitivity and specificity in %



FFR post-stent versus IVUS

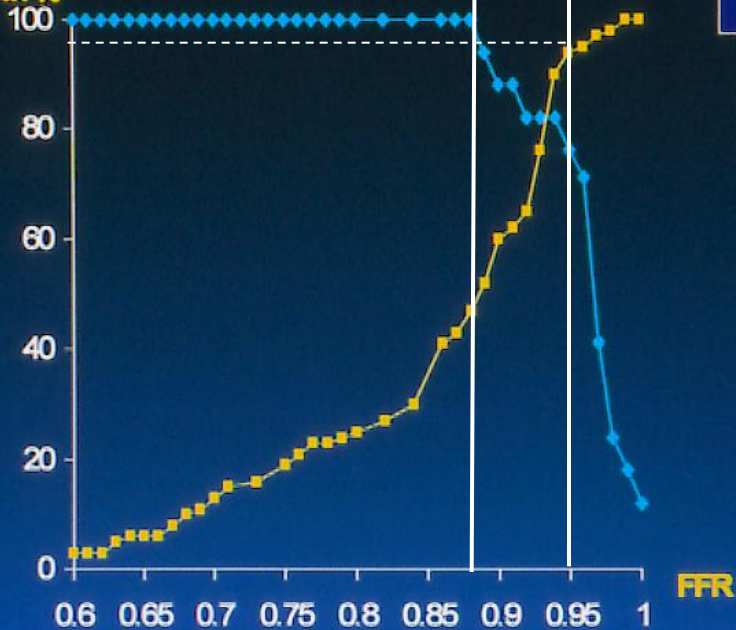
ROC curve, showing sensitivity and specificity for several FFR cut-off values, compared to intravascular ultrasound, for assessment of optimal stent deployment.

FFR post-stent versus IVUS



↑
FFR \leq 0.88 \rightarrow IVUS always abnormal

sensitivity and specificity in %



ROC curve, showing sensitivity and specificity for several FFR cut-off values, compared to intravascular ultrasound, for assessment of optimal stent deployment.

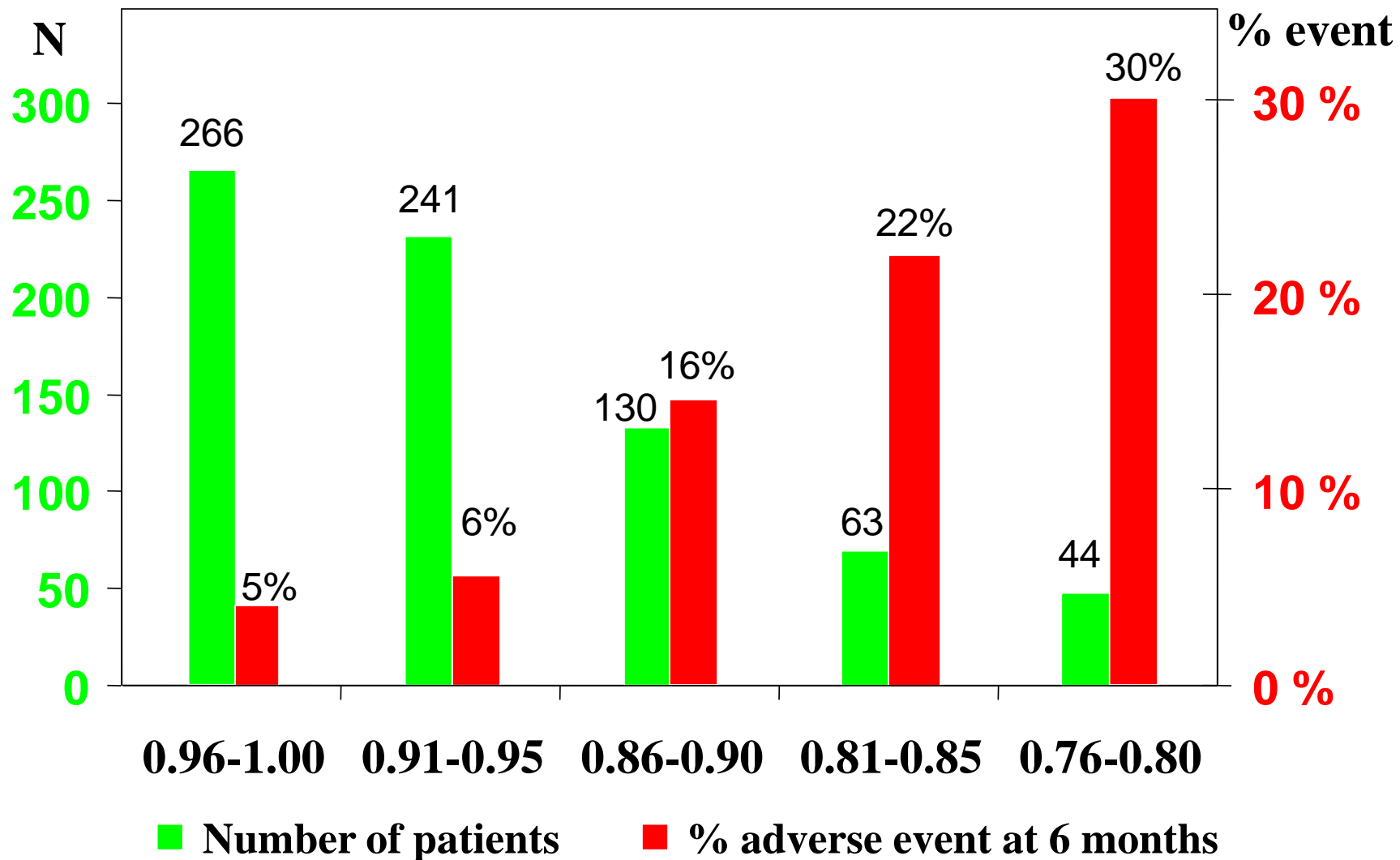
FFR post-stent versus IVUS



$\text{FFR} \geq 0.95 \rightarrow \text{IVUS is normal in 95\% of cases}$

FFR-post-STENT Registry (N =750)

% ADVERSE EVENTS AT 6 MONTHS



FFR post PCI

The Stent –Registry was performed more than 10 years ago, when the extent of disease and atherosclerotic burden in the average patient was much less than today

It is unknown in the stent Registry, if a persistent gradient was due to focal pressure drop across the stent, or to (focal or diffuse) disease more proximal or distal in the artery.

Events might be promoted by both: by inadequately deployed stents as well as high atherosclerotic burden elsewhere in the artery

FFR post PCI

A residual gradient within the coronary artery after apparently successful stenting, can be caused by:

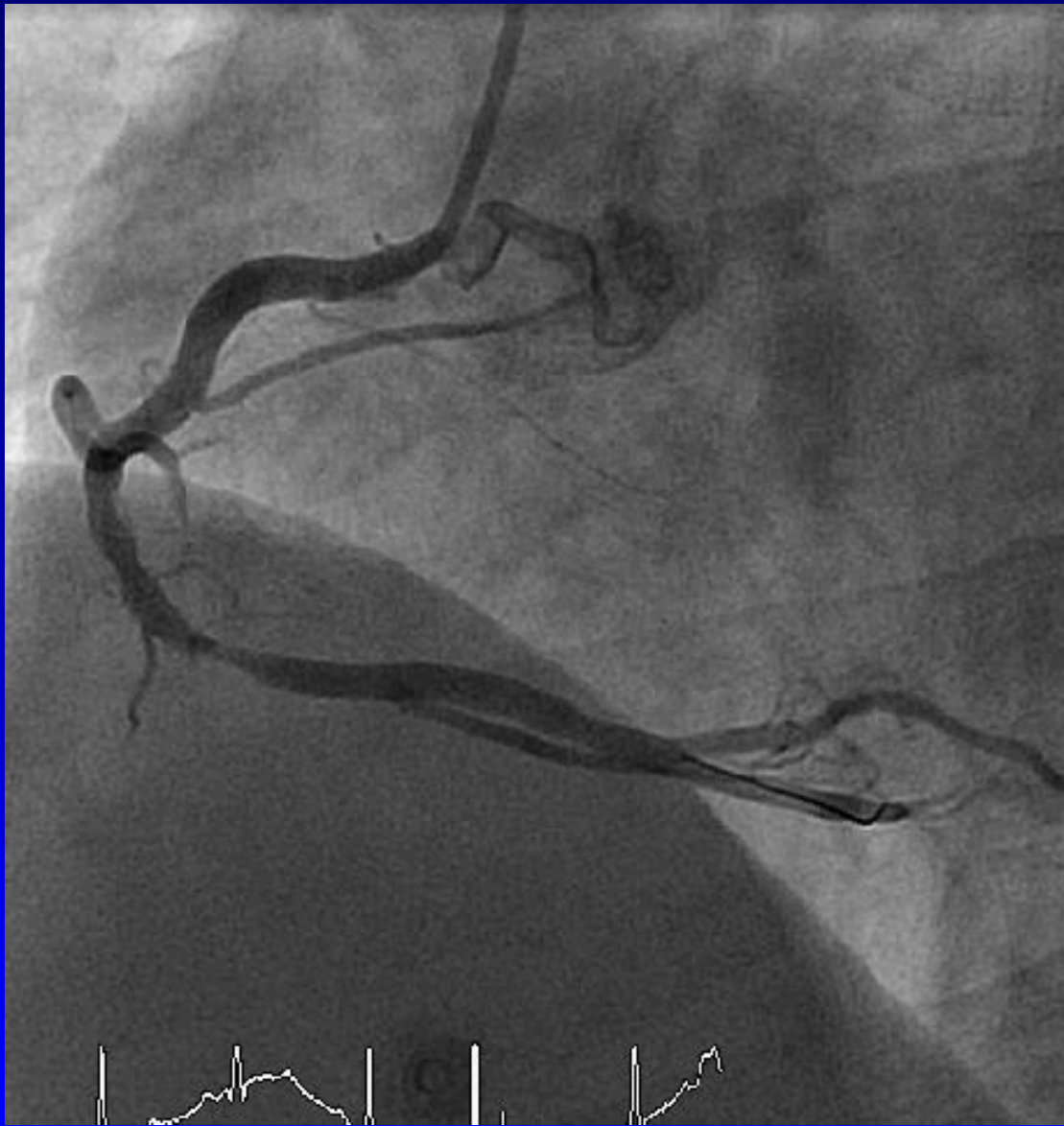
- *inadequate stent deployment (focal gradient across stent) , or by*
- *diffuse disease or other lesions (more proximal or distal) along the course of the stented artery*

The most reliable way to discriminate this, is a hyperemic pullback recording (i.v adenosine, i.c.papaverine, or i.v. regadenoson bolus) after stenting

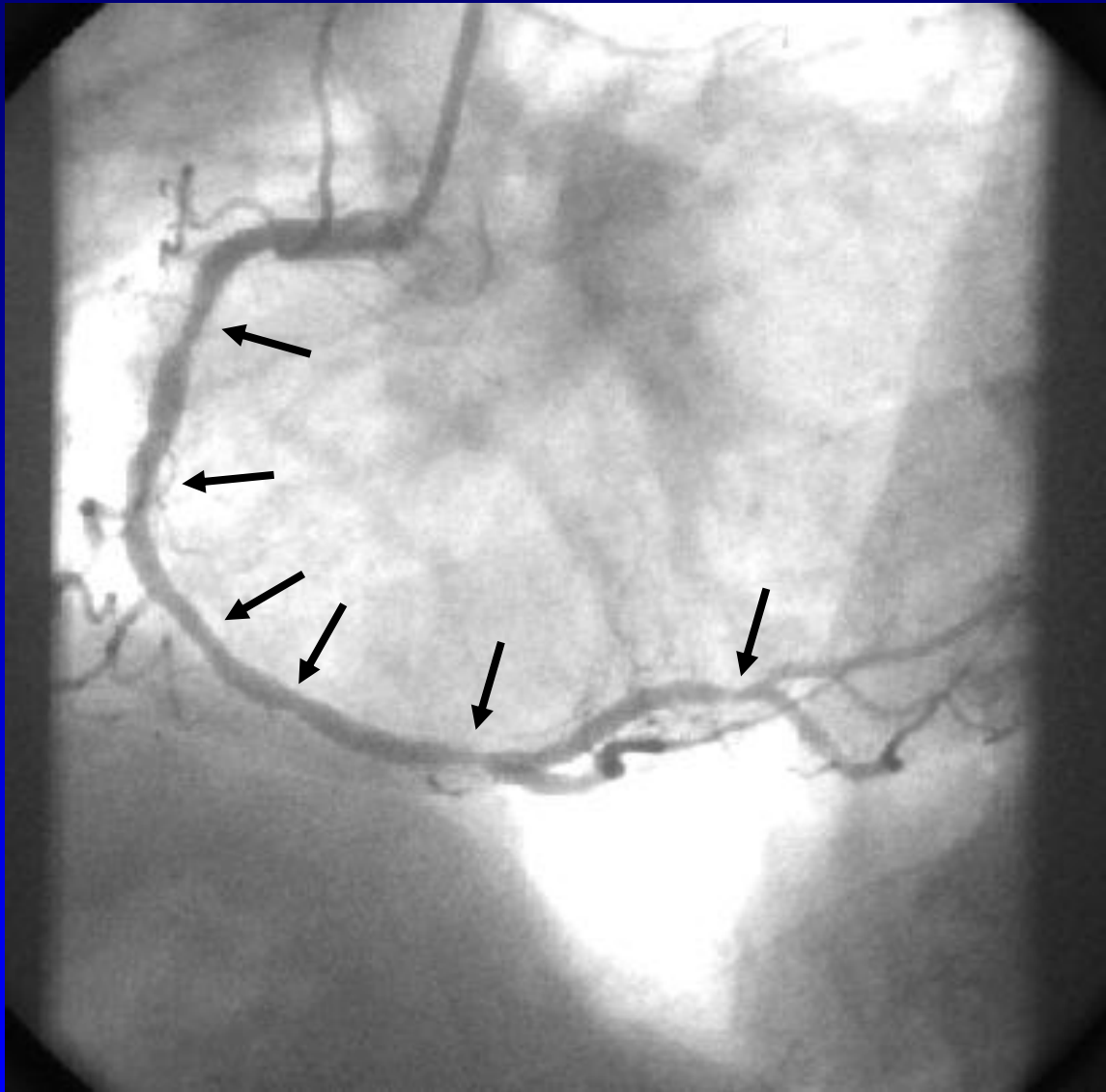
FFR post PCI:

HOW SHOULD WE DO IT IN CLINICAL PRACTICE ?

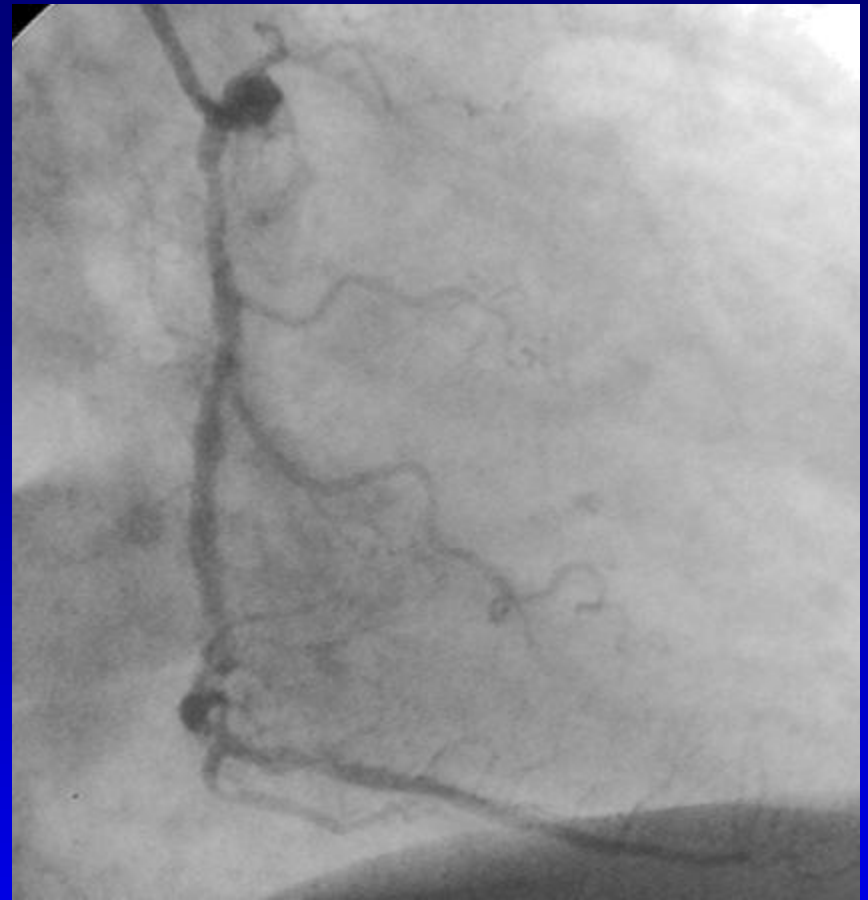
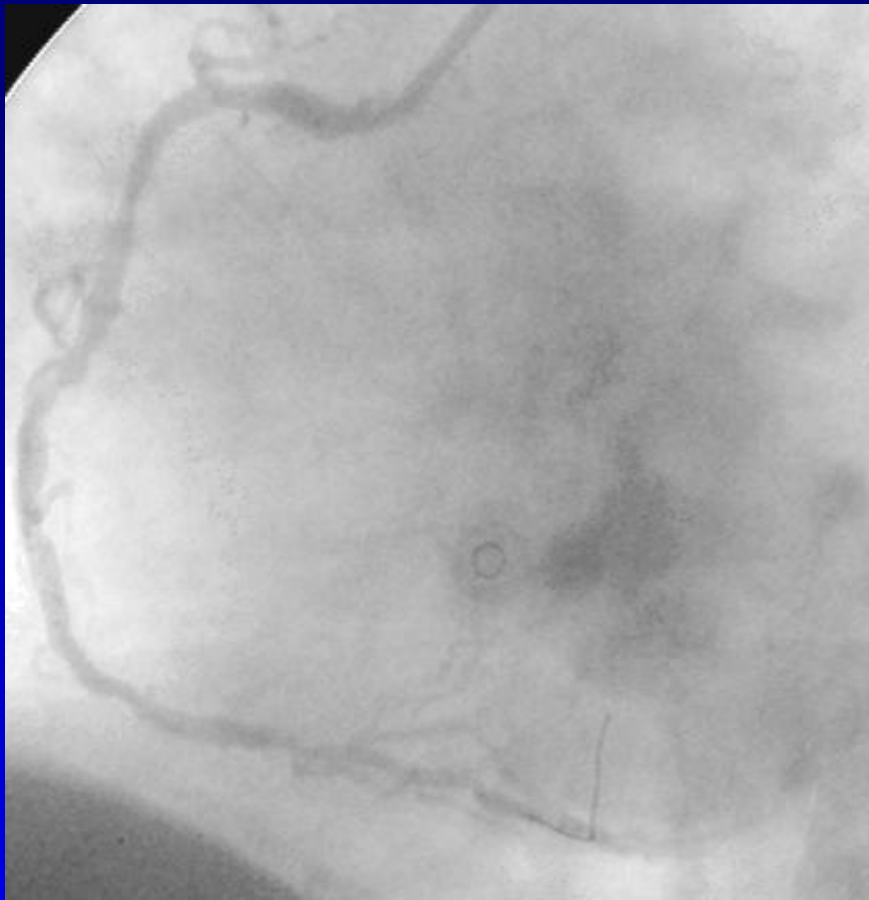
- Let's have a look at 3 different patients but all with chest pain and a positive MIBI in the inferior wall



Typical chest pain; positive MIBI-Spect inferior wall

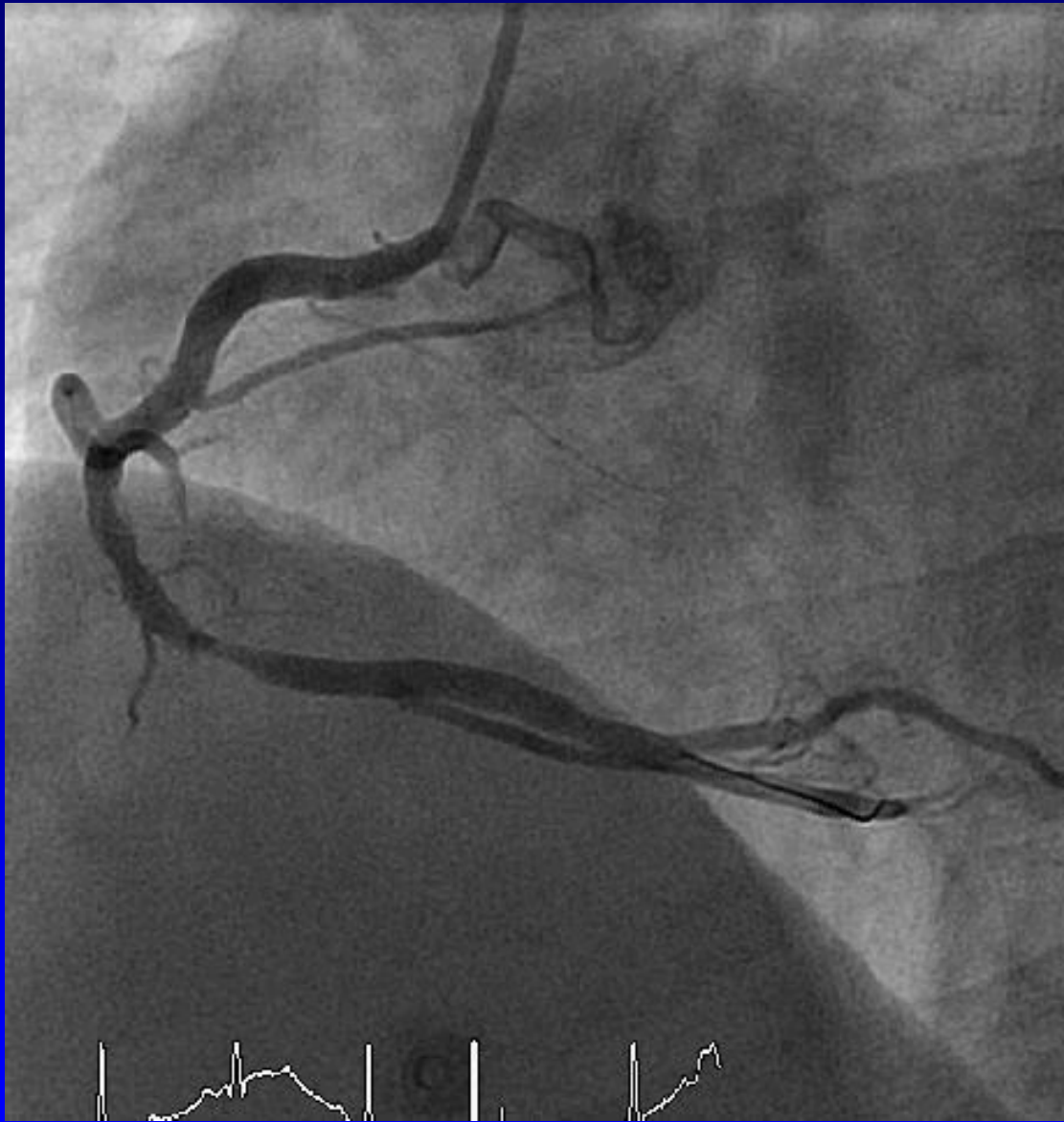


Typical chest pain; positive MIBI-Spect inferior wall



Very obese male,

Typical chest pain; positive MIBI-Spect inferior wall



PressureWire in RCA

ARCHIVE CUSTOM

D:\Mijn documenten\radi_download\RokvenFAME3P220168 RADI

| FOLDER | PATIENT ID | DATE | TIME | VESSEL | PROCEDURE | ACTION | TYPE | SIZE |
|----------------------|-----------------|------------|----------|--------|-----------|--------|------|-------|
| SchreuderBifurclesie | FAME3PhrR220168 | 2014-02-19 | 11:11:53 | | | | FFR | 69Kb |
| salmans | FAME3PhrR220168 | 2014-02-19 | 11:11:53 | | | | FFR | 69Kb |
| RULO | FAME3PhrR220168 | 2014-02-19 | 11:06:31 | | | | FFR | 103Kb |
| RokvenFAME3P220168 | FAME3PhrR220168 | 2014-02-19 | 11:04:06 | | | | FFR | 48Kb |
| REGADENOSON_081 | FAME3PhrR220168 | 2014-02-19 | 11:01:55 | | | | FFR | 11Kb |

PRINT EDIT RENAME EXPORT ERASE SETUP



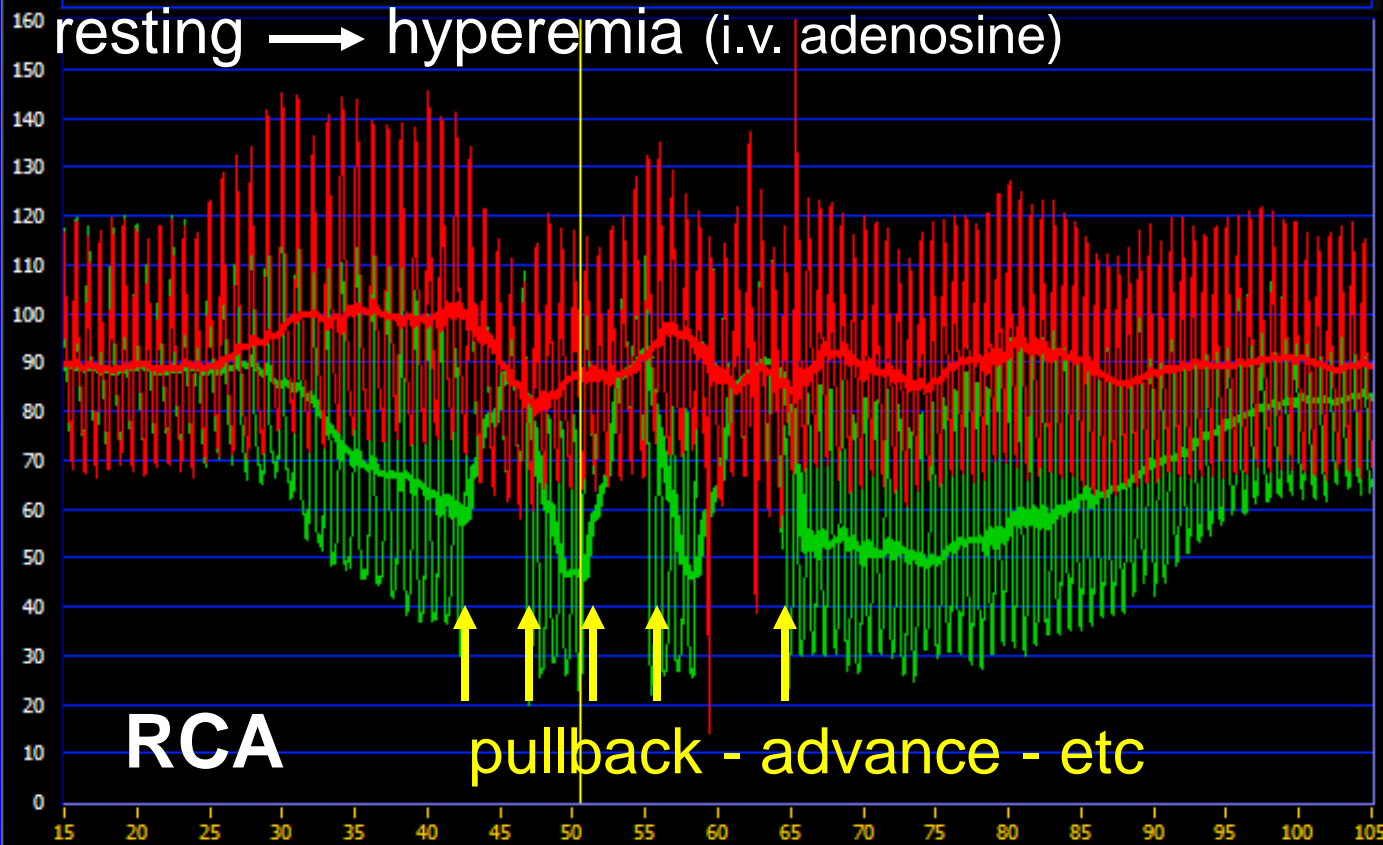
FAME3PhrR220168 2014-02-19 11:06:31

88
Pa mean

47
Pd mean

0,53
FFR

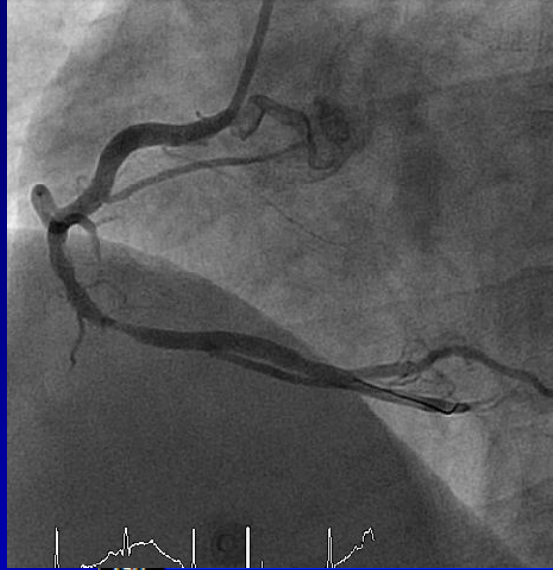
resting → hyperemia (i.v. adenosine)



50,5 CURSOR

+ [magnifying glass icon] [crosshair icon]

RESET



COM

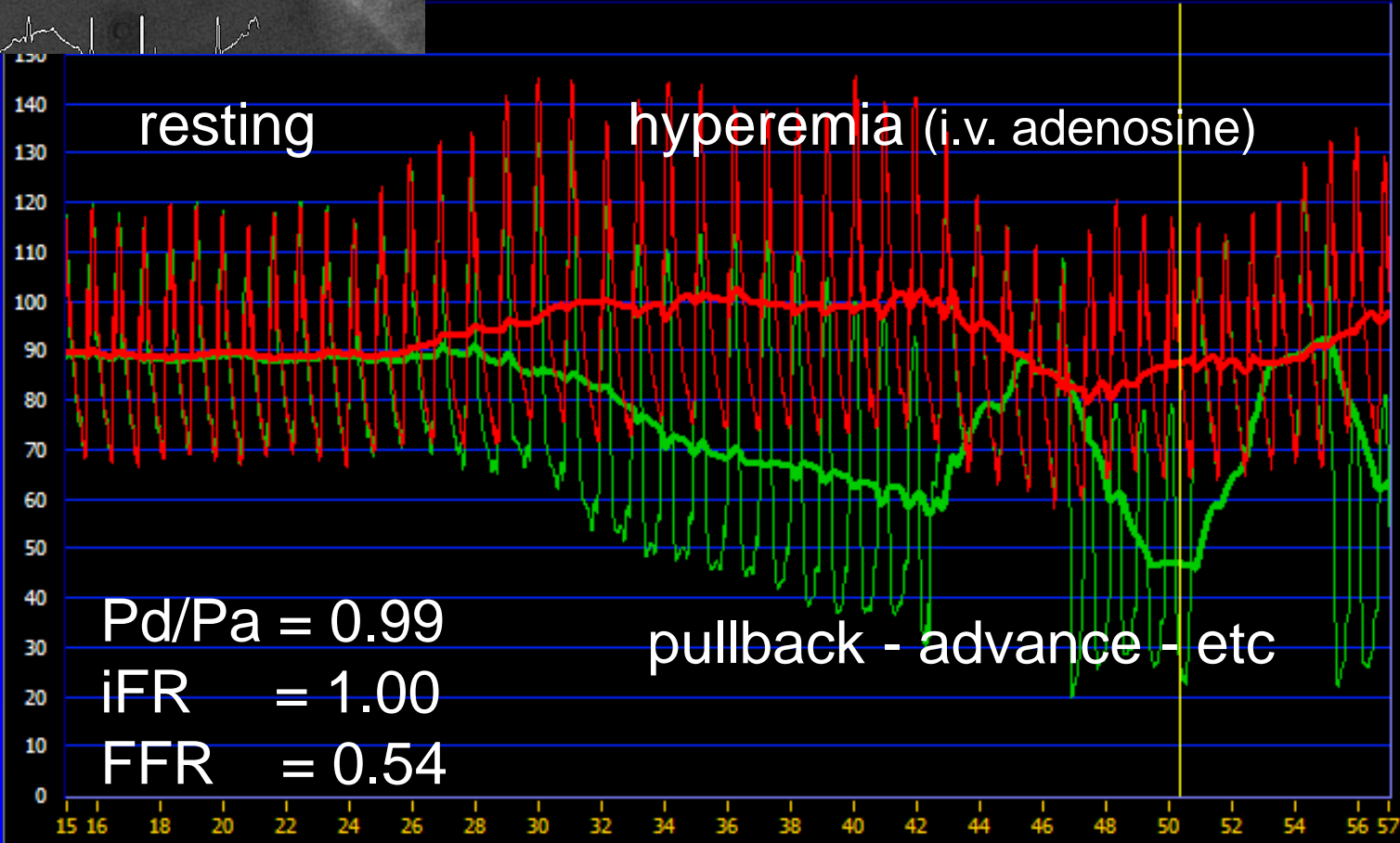
n documenten\radi_download\RokvenFAME3P220168 RADI

| IT ID | DATE | TIME | VESSEL | PROCEDURE | ACTION | TYPE | SIZE |
|------------|------------|----------|--------|-----------|--------|------|-------|
| PhrR220168 | 2014-02-19 | 11:11:53 | | | | FFR | 69Kb |
| PhrR220168 | 2014-02-19 | 11:06:31 | | | | FFR | 103Kb |
| PhrR220168 | 2014-02-19 | 11:04:06 | | | | FFR | 48Kb |
| PhrR220168 | 2014-02-19 | 11:01:55 | | | | FFR | 11Kb |
| PhrR220168 | 2014-02-19 | 10:54:57 | | | | FFR | 5Kb |

PRINT EDIT RENAME EXPORT ERASE SETUP



2014-02-19 11:06:31



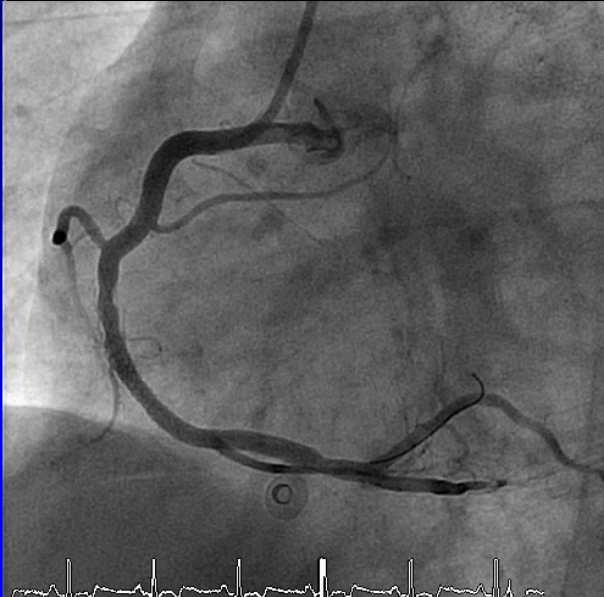
87
Pa mean

47
Pd mean

0,54
FFR

50,4
CURSOR

RESET



nten\radi_download\RokvenFAME3P220168 RADI

| DATE | TIME | VESSEL | PROCEDURE | ACTION | TYPE | SIZE |
|------------|----------|--------|-----------|--------|------|-------|
| 2014-02-19 | 11:11:53 | | | | FFR | 69Kb |
| 2014-02-19 | 11:11:53 | | | | FFR | 69Kb |
| 2014-02-19 | 11:06:31 | | | | FFR | 103Kb |
| 2014-02-19 | 11:04:06 | | | | FFR | 48Kb |
| 2014-02-19 | 11:01:55 | | | | FFR | 11Kb |

EDIT RENAME EXPORT ERASE SETUP

2014-02-19 11:11:53

hyperemia
(adenosine)



100
Pa mean

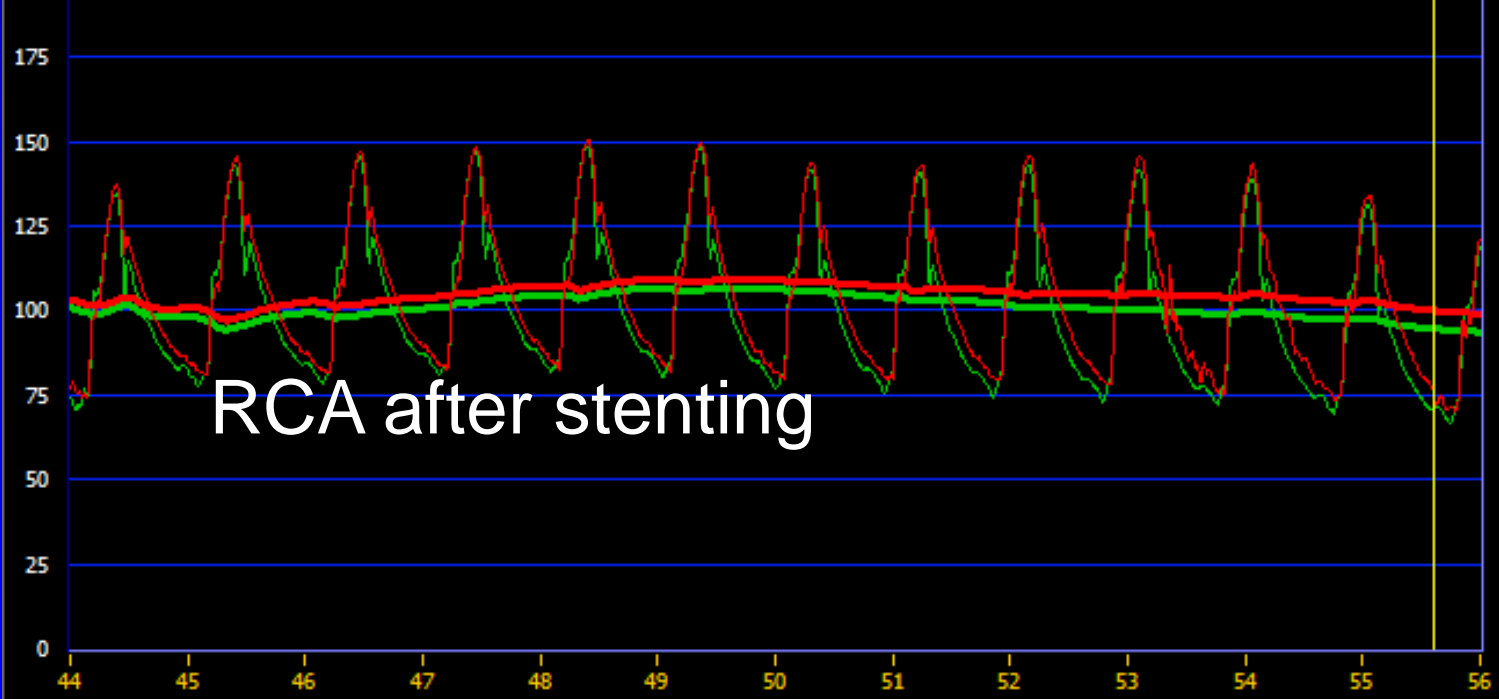
95
Pd mean

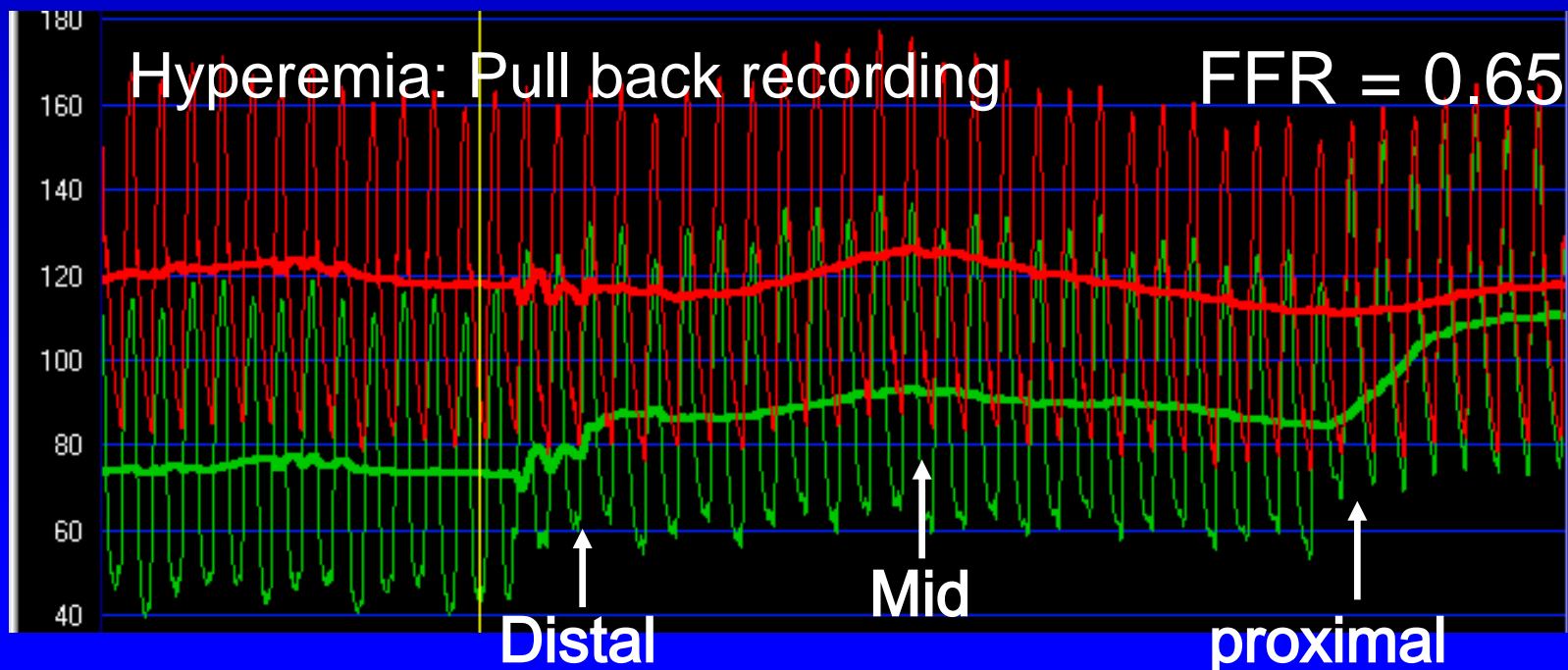
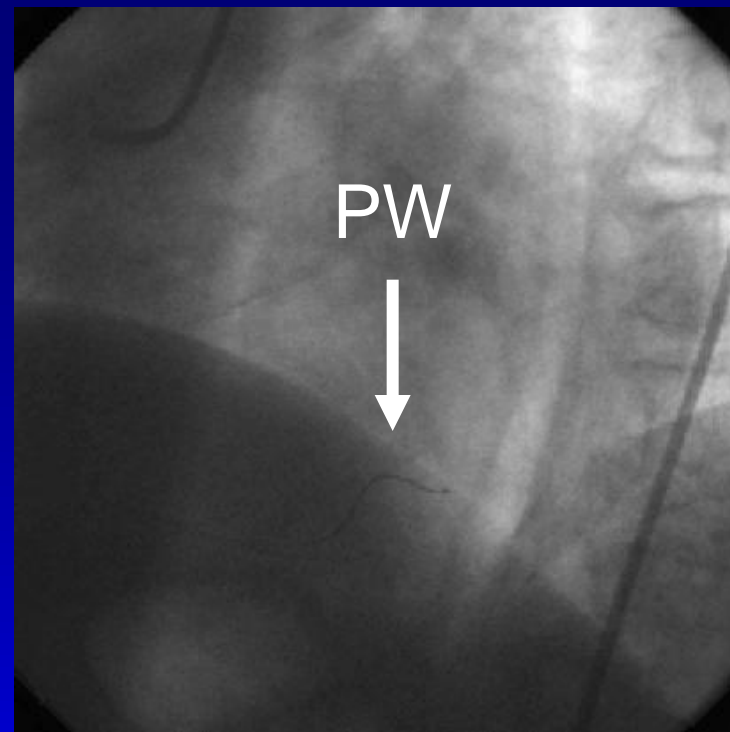
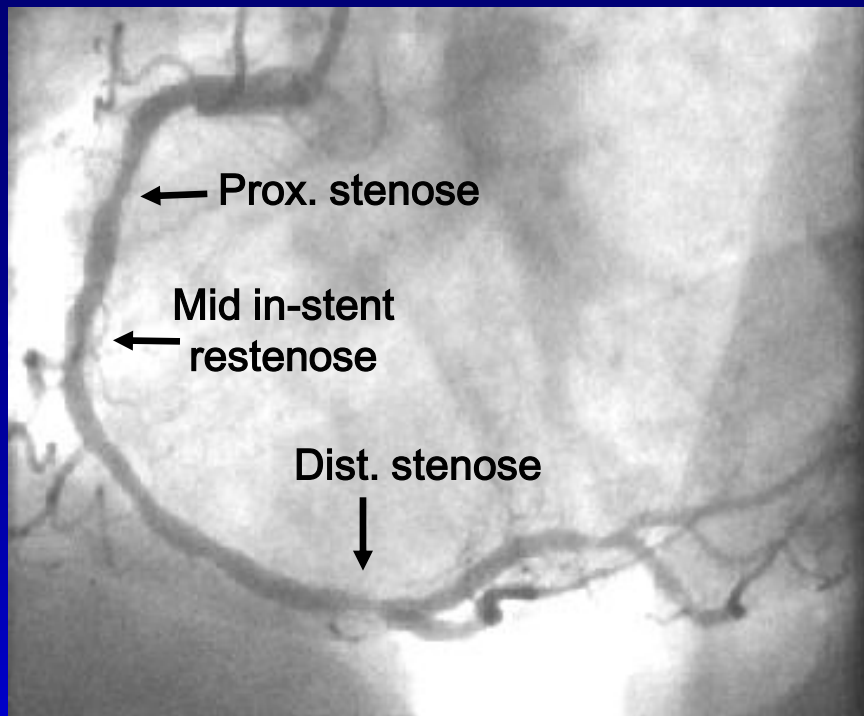
0,95
FFR

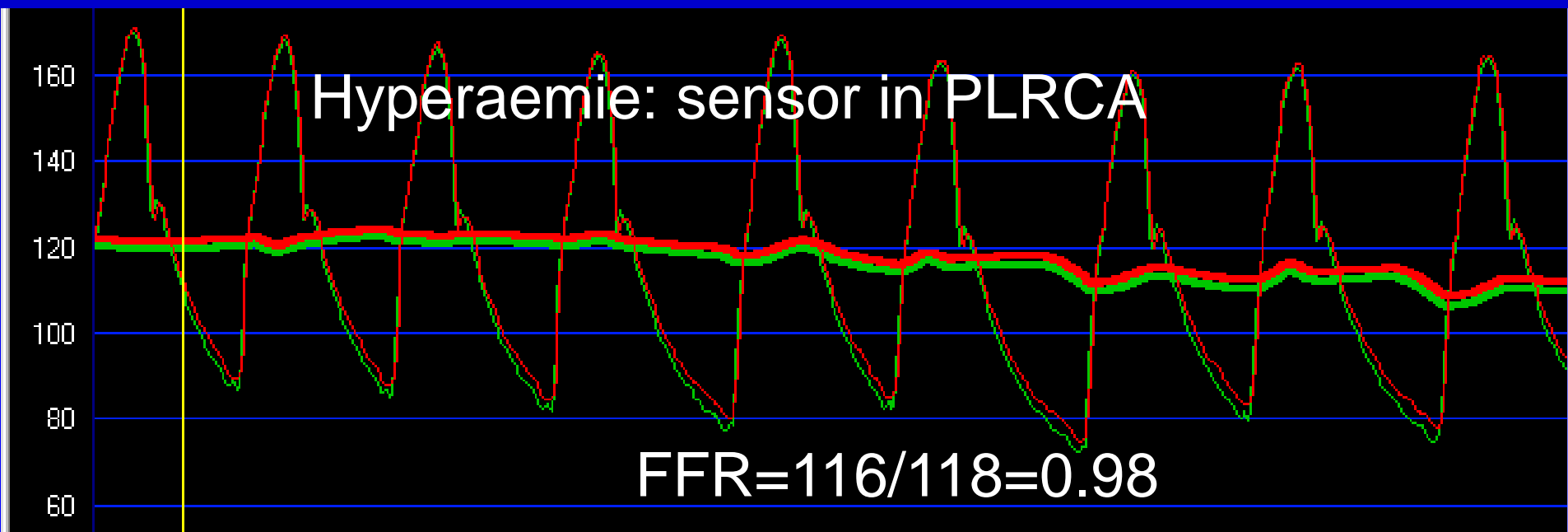
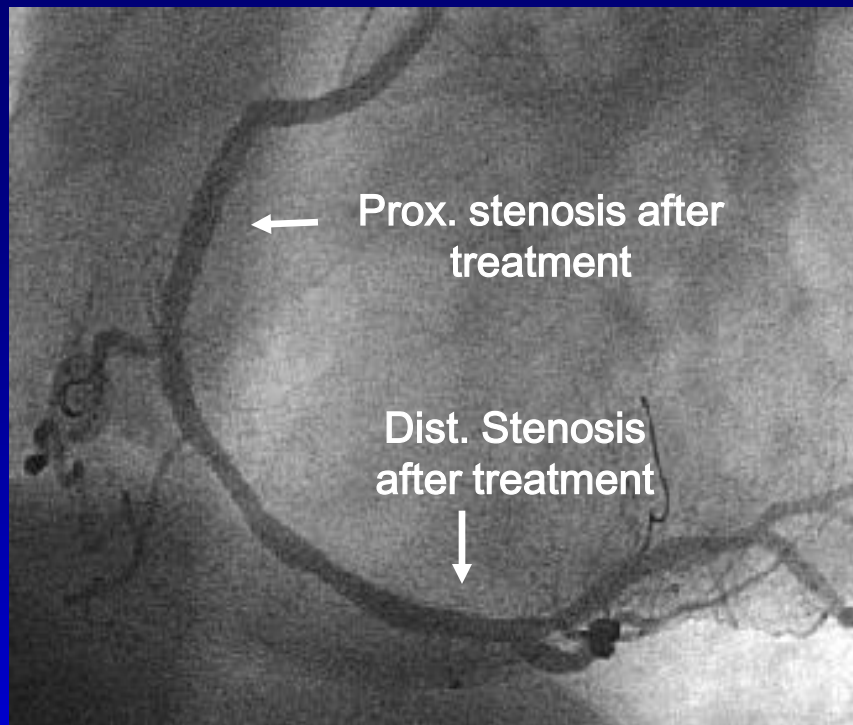
55,6
CURSOR

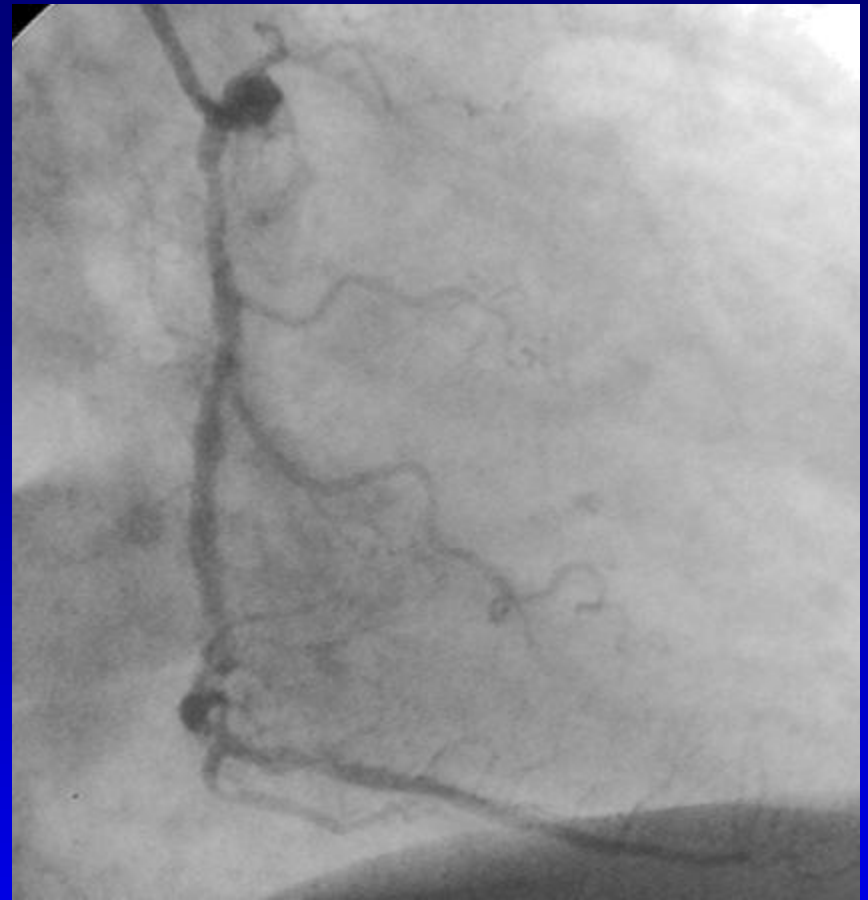
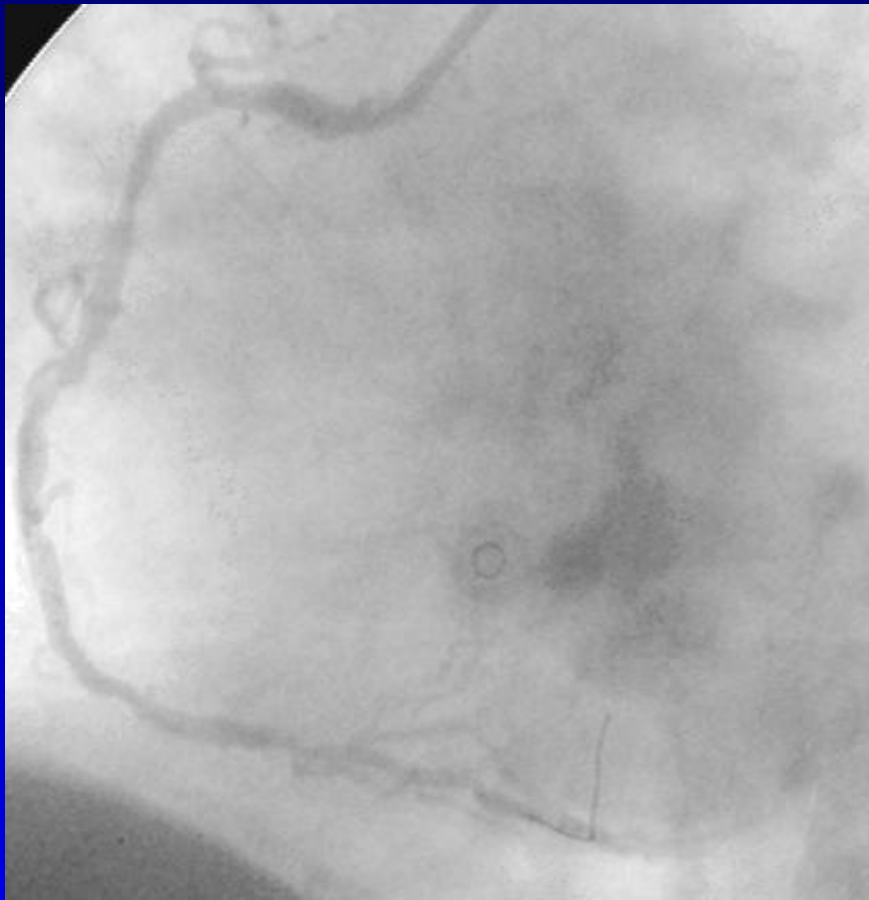


RESET









Very obese male,

Typical chest pain; positive MIBI-Spect inferior wall

EDIT RENAME EXPORT ERASE SETUP

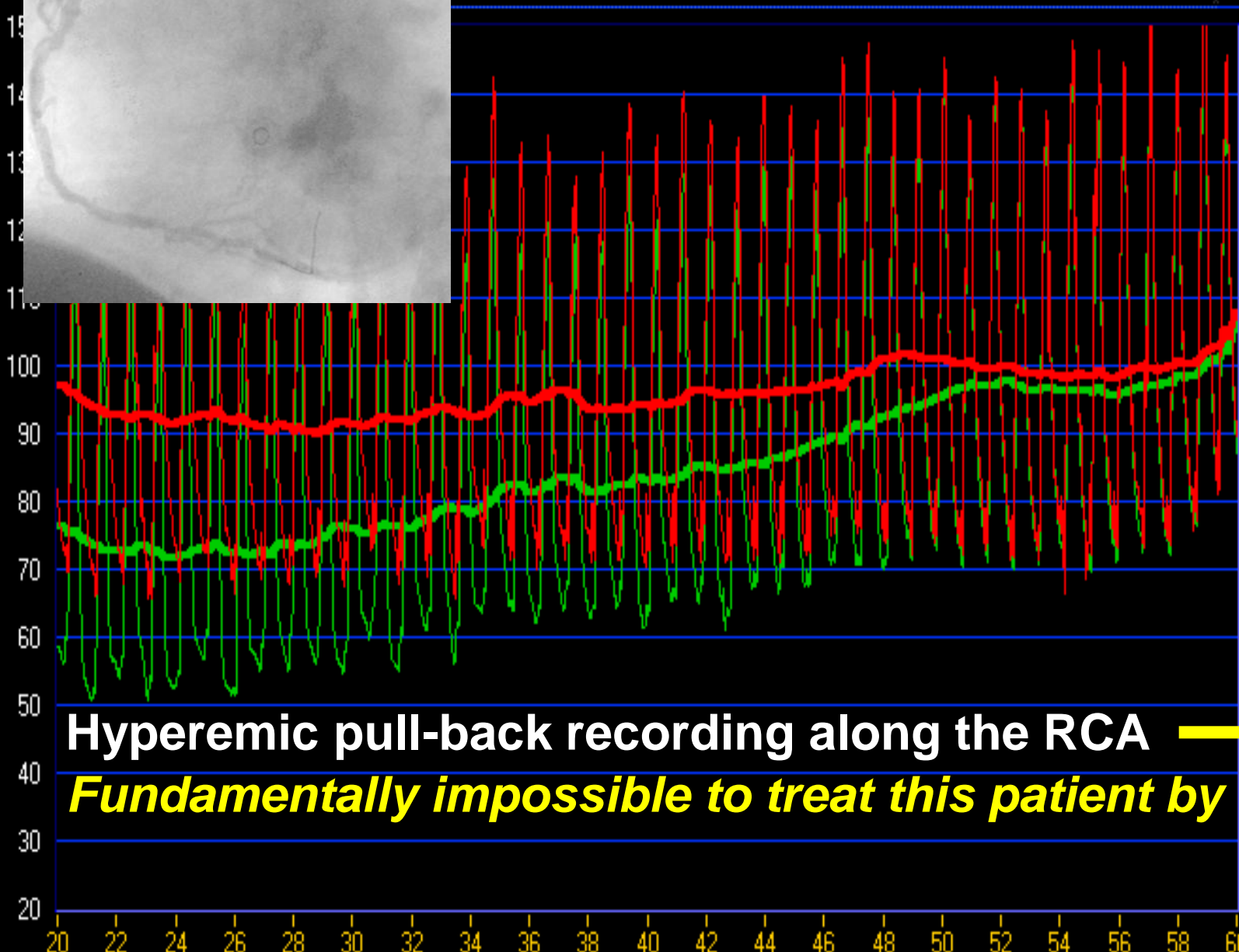
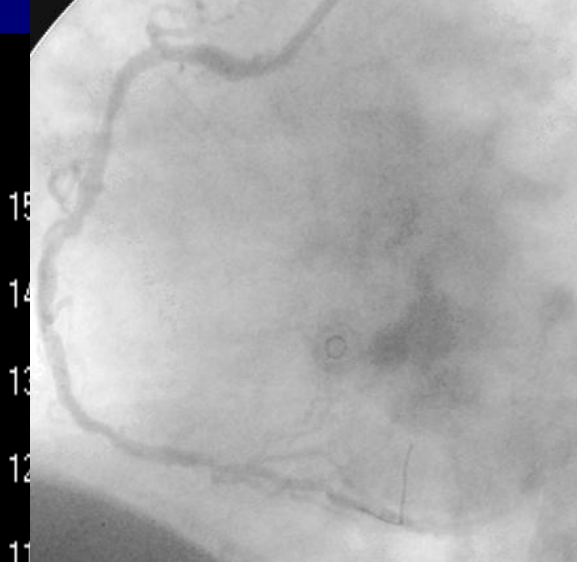
2004-06-14 15:55:19

109
Pa mean

84
Pd mean

0,77
FFR

7,9
Cursor

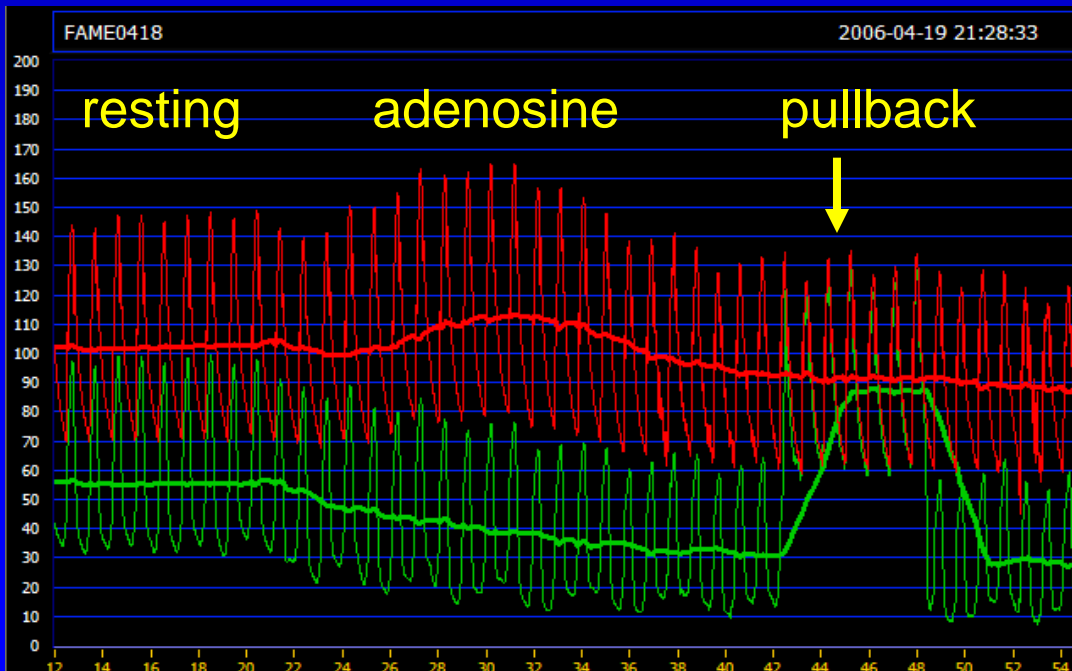
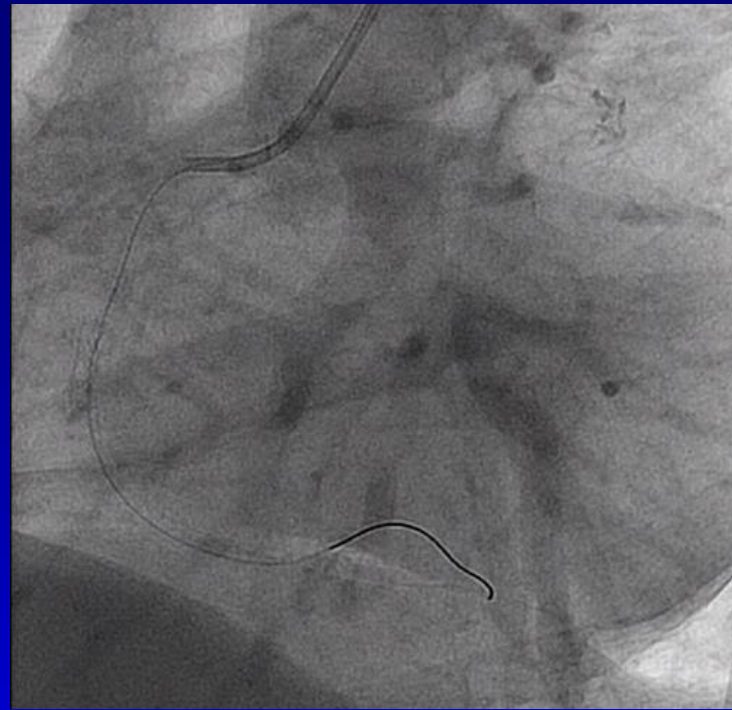
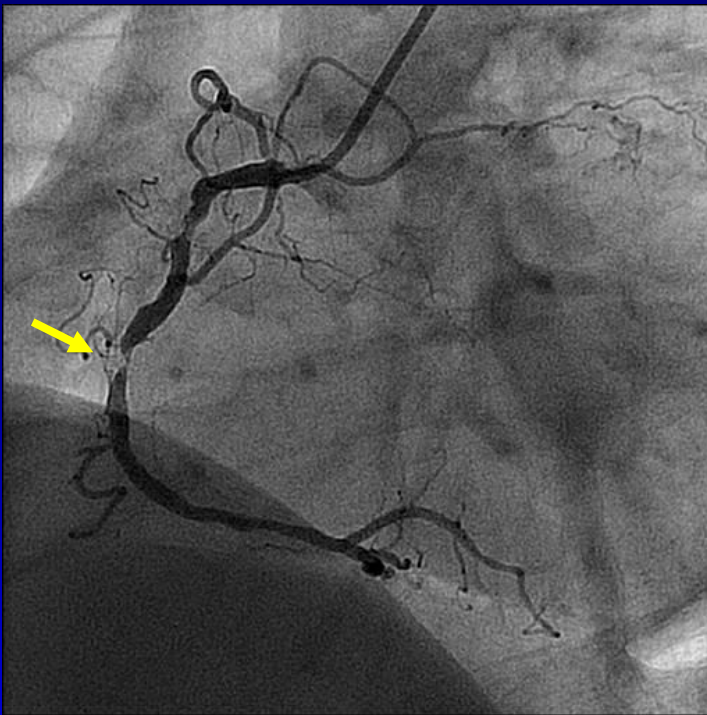


Hyperemic pull-back recording along the RCA →
Fundamentally impossible to treat this patient by stenting

+ 🔍 ↕
RESET

FFR post PCI

Be aware that after stenting a stenosis, blood flow in the artery will increase and other gradients within the vessel may be unmasked or increase !



RCA:

FFR = 0.34

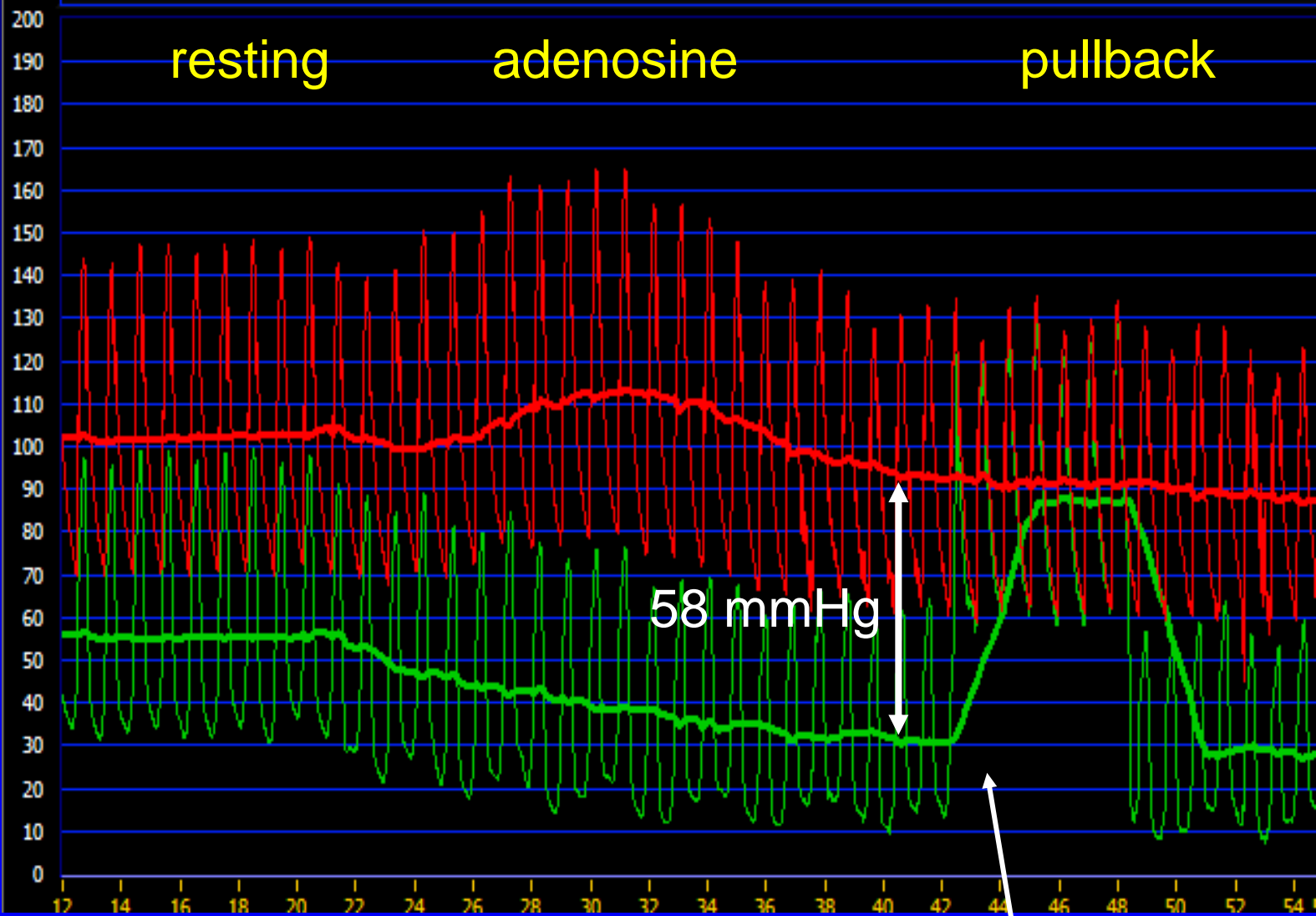
FAME0418

2006-04-19 21:28:33

resting

adenosine

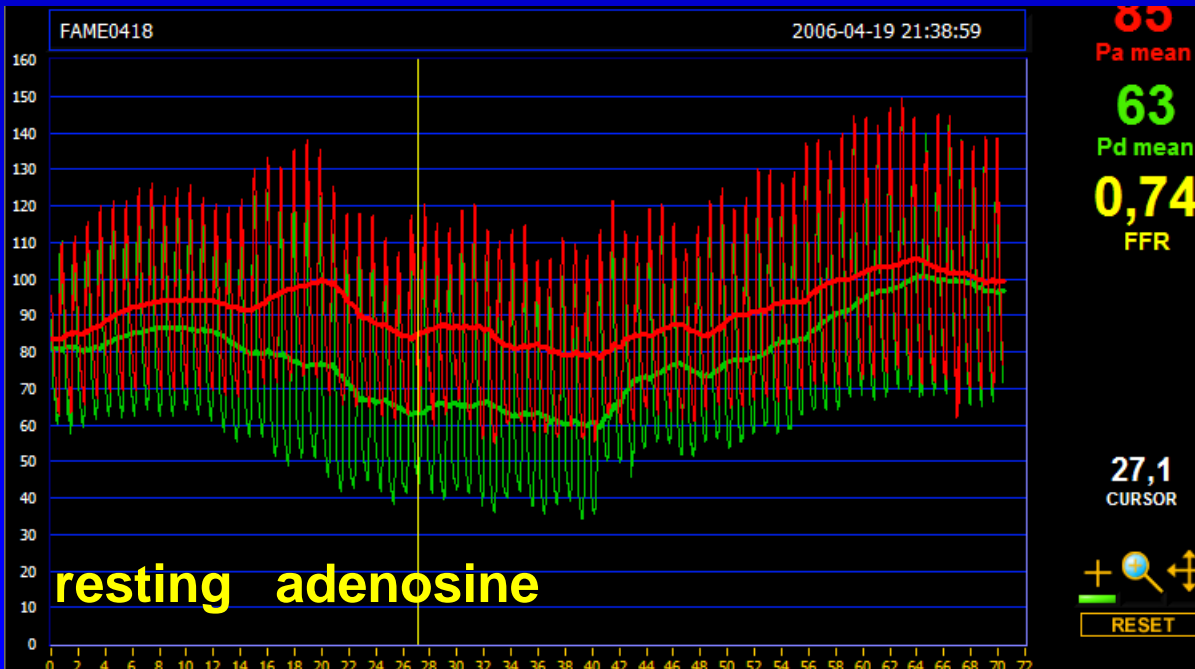
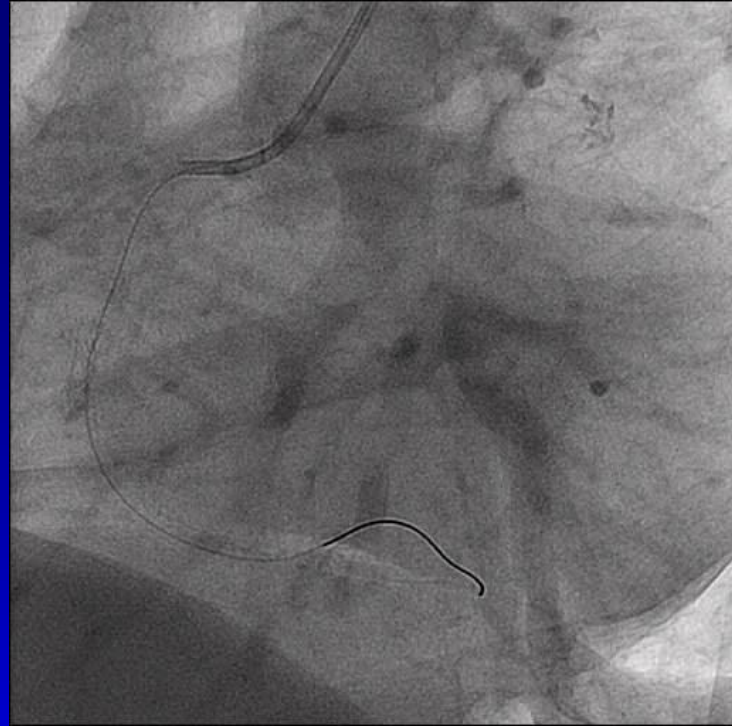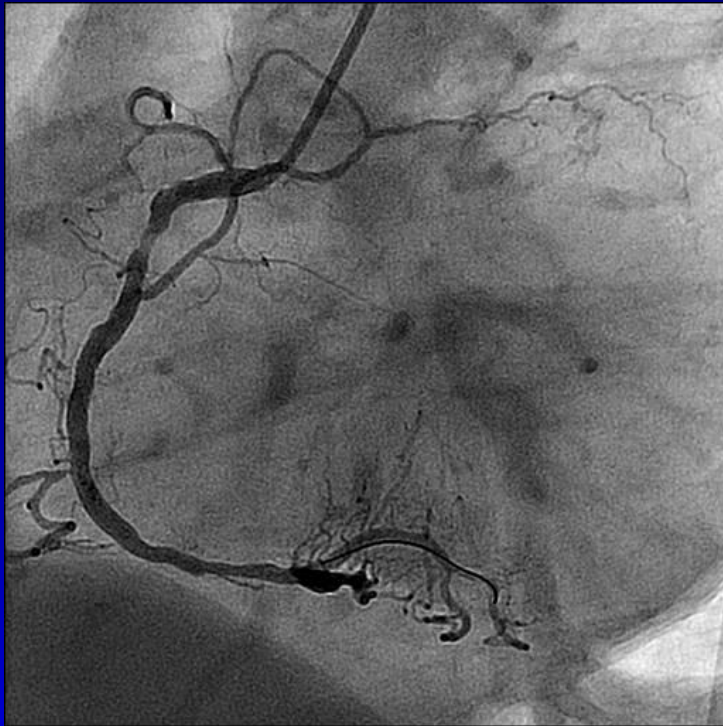
pullback



↕ 5 mmHg

58 mmHg

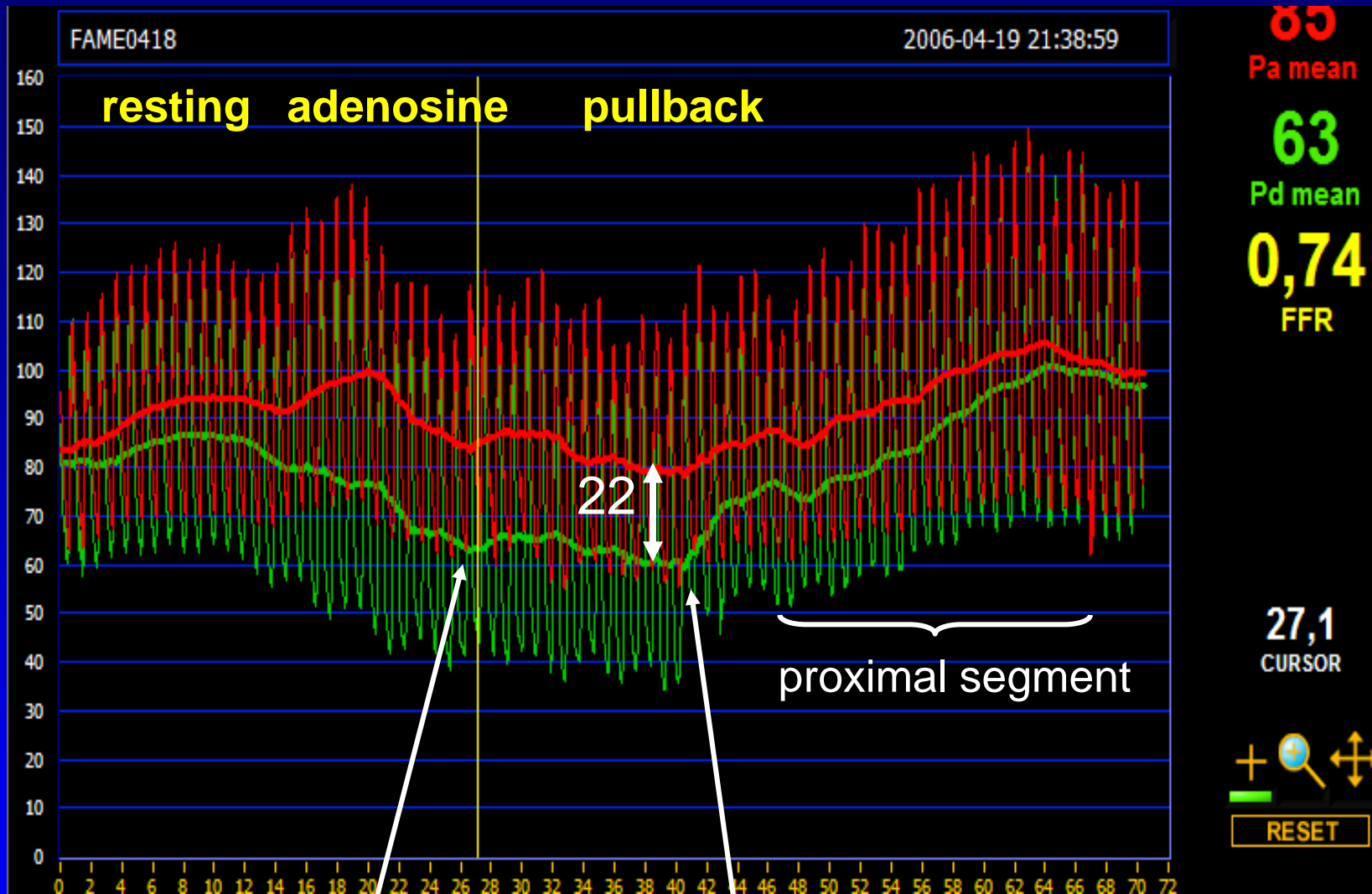
Pull-back across distal stenosis



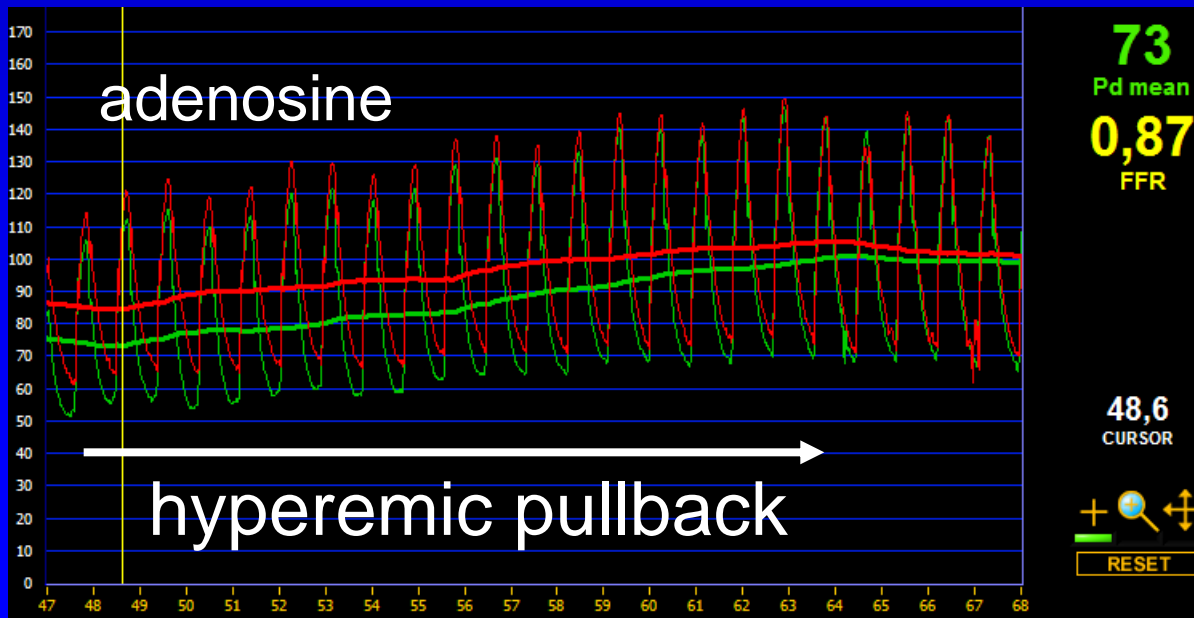
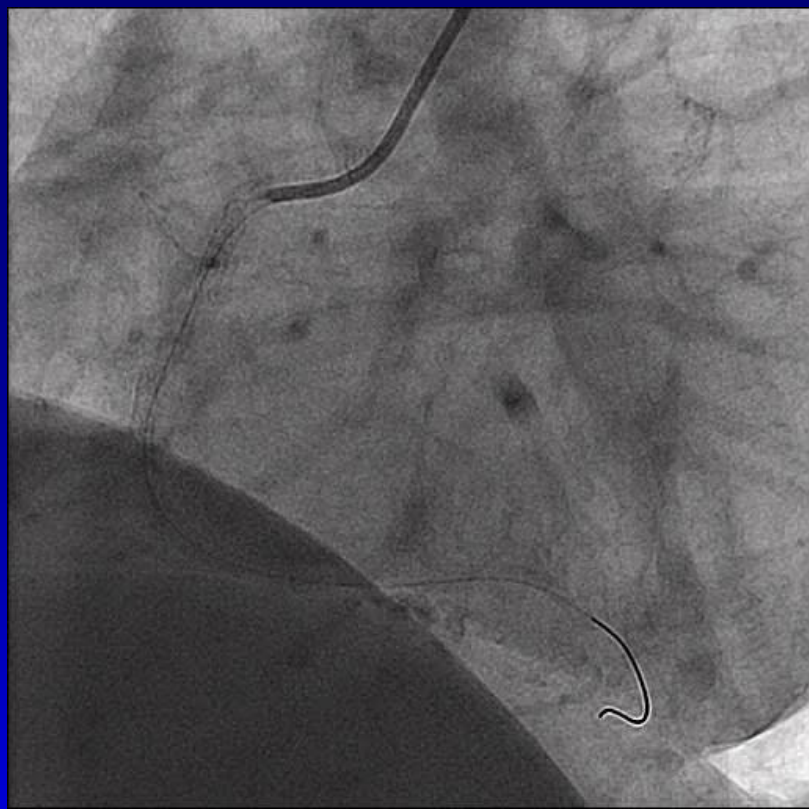
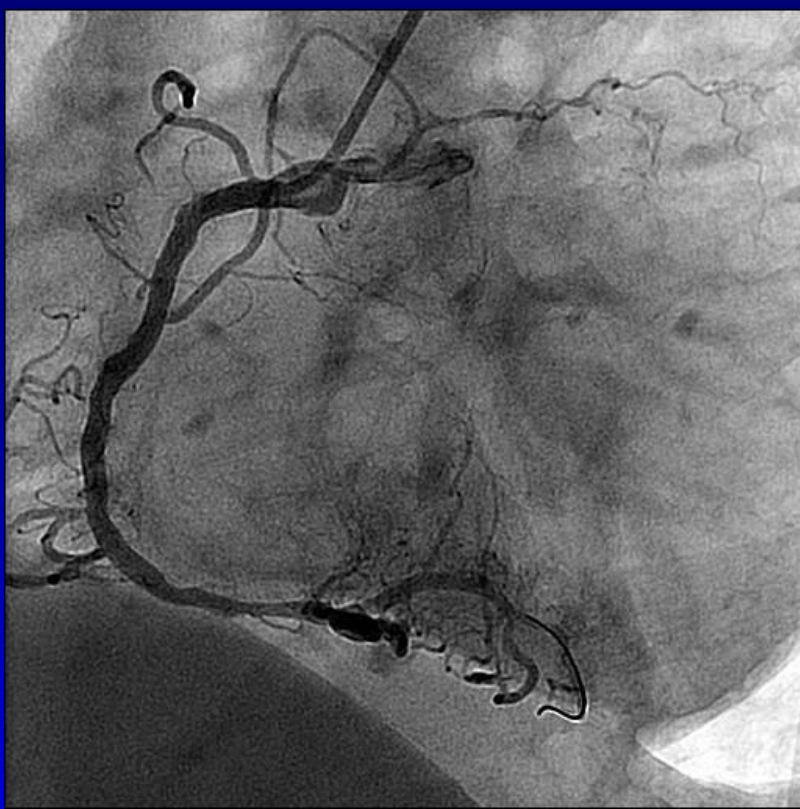
RCA after
one stent:

FFR = 0.74

FFR 0.34 → 0.74

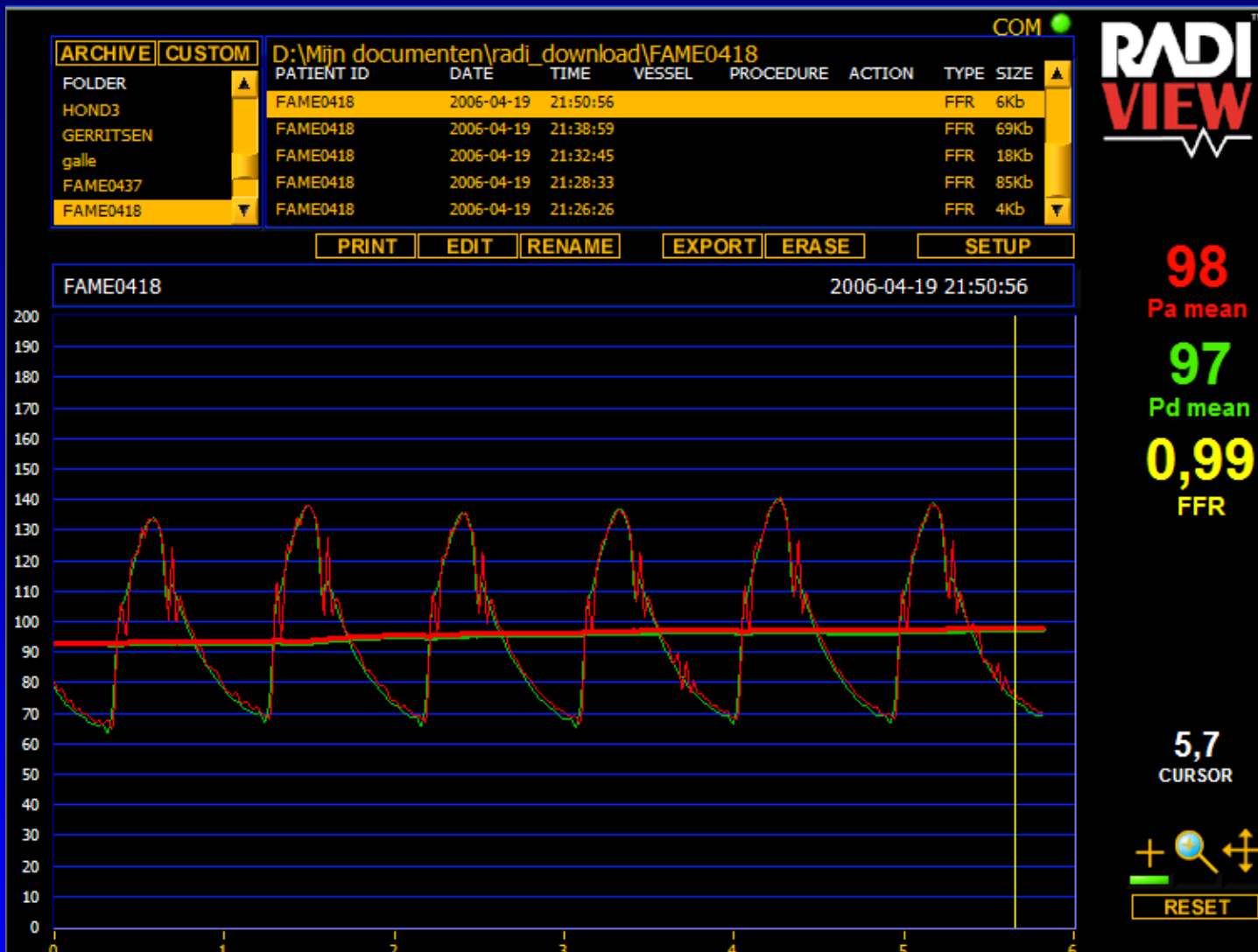


pullback across stent & across proximal stenosis
58 → ~ 0 mmHg 5 → 22 mmHg



RCA after 2 stents:
FFR = 0.87

*(pullback shows
diffuse disease but
no gradient across
any of the stents)*



Pressure sensor back at the ostium of the RCA

FFR post PCI

What is a “normal” (or “acceptable”) gradient across a well-deployed stent ?

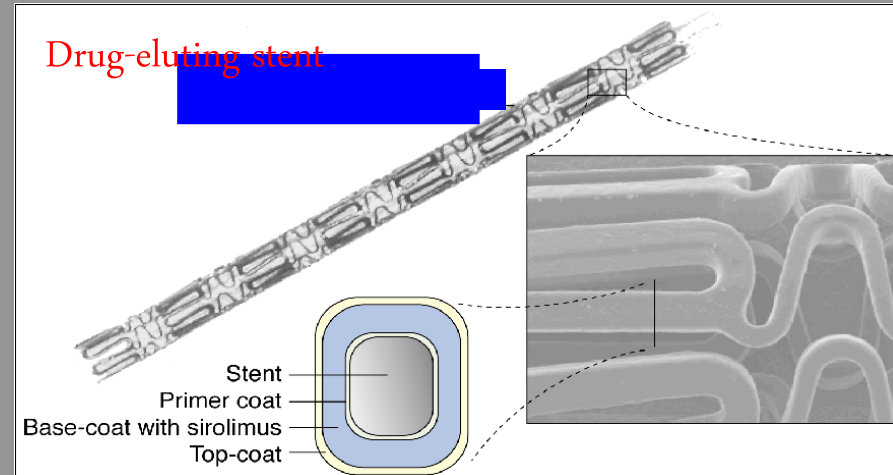
- immediately after implantation
- at follow up

→ Mechanistic study by Van 't Veer et al:
“Hemodynamic Characteristics of DES at Implantation and at 6-m Follow-up”

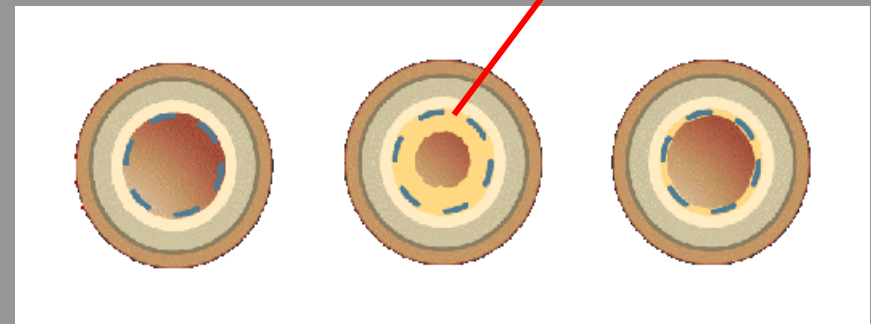
Eur Heart J 2006;27:1811-1817

Sirolimus study (Van 't Veer et al, Eur Heart J 2006)

- 20 patients
- 2 stenoses
- comparable
(diameter / length)
- 1 DES (Cypher)
- 1 'normal' stent
(BX Velocity)
- assigned randomly



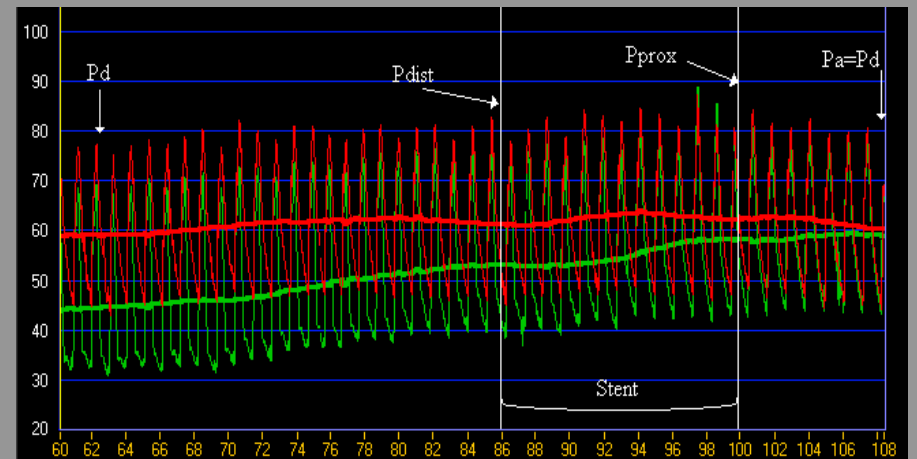
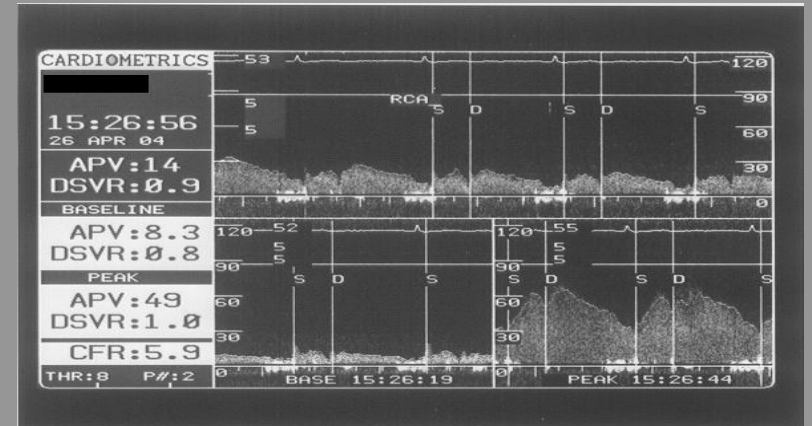
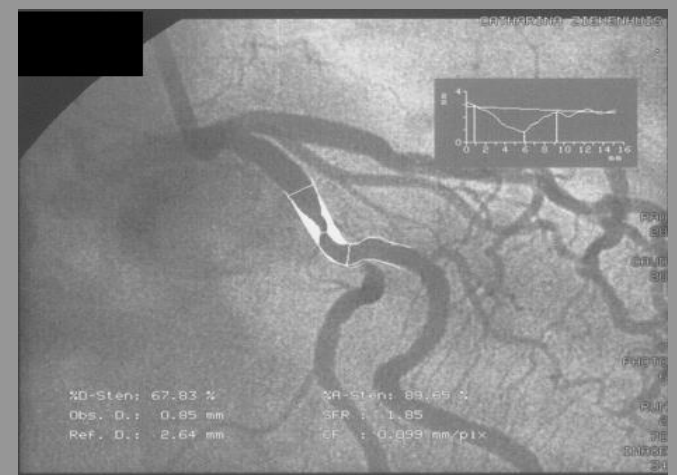
Neointimal hyperplasia



Sirolimus study

(Van 't Veer et al, Eur Heart J 2006)

- quantitative coronary angiography (QCA)
 - % diameter (area) stenosis
 - Minimal Luminal Diameter (MLD)
 - Late loss
- Physiologic measurements
 - Pressure
 - Blood flow velocity
 - Wall shear stress
- all measurements repeated after 6 months



FFR and hyperemic Pd/Pa before & immediately after stenting, and at 6-month follow-up

| <u>FFR</u> | <i>DES</i> | <i>Bare metal</i> | <i>P value</i> |
|--------------------------|------------------|-------------------|------------------|
| <i>before</i> | <i>0.61±0.20</i> | <i>0.61±0.16</i> | <i>NS</i> |
| <i>immediately after</i> | <i>0.90±0.06</i> | <i>0.88±0.07</i> | <i>NS</i> |
| <i>Follow- up</i> | <i>0.91±0.05</i> | <i>0.83±0.10</i> | <i>P<0.01</i> |

Hyperemic pressure ratio across stent

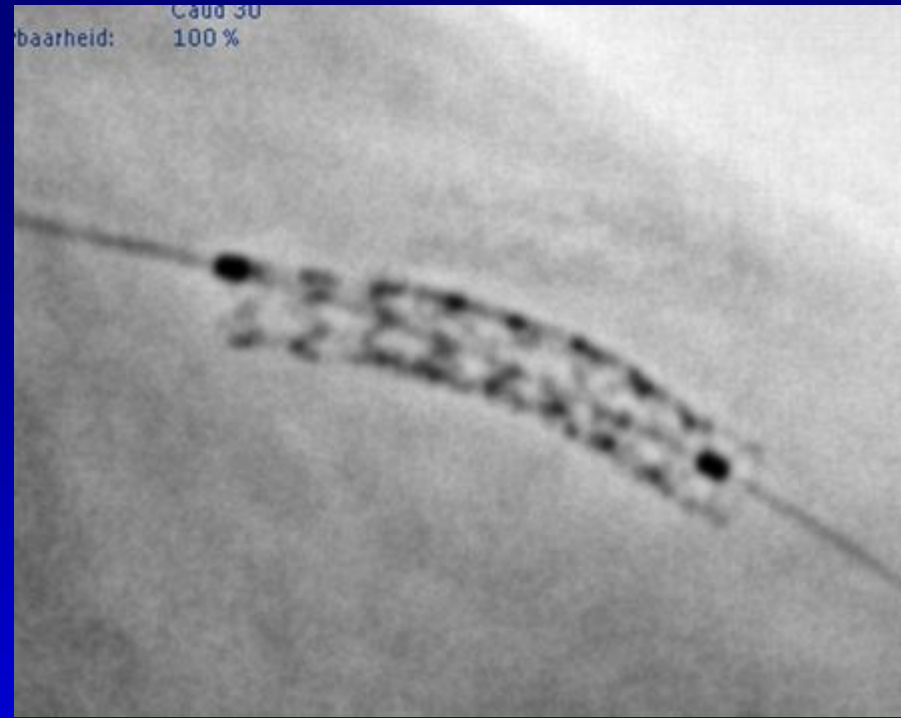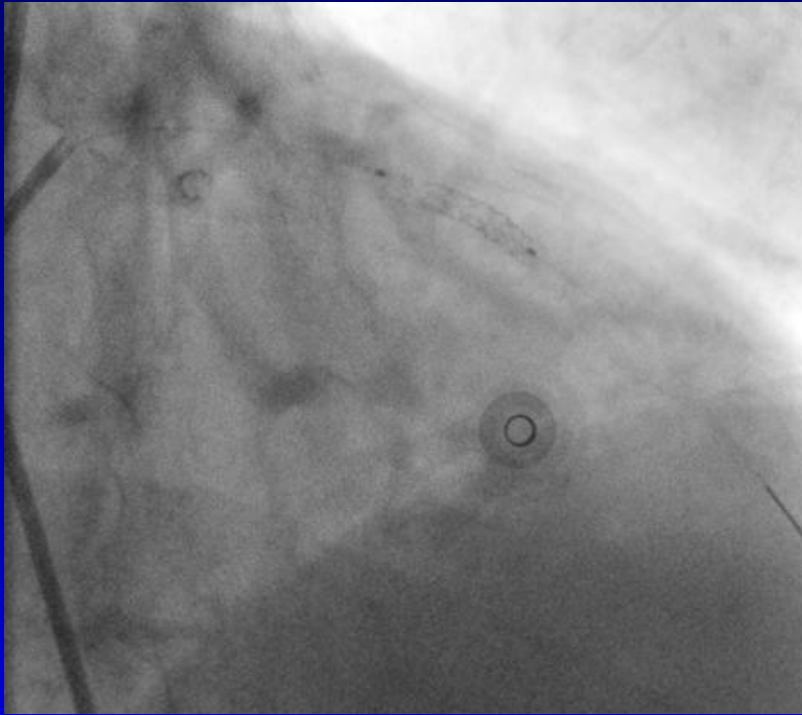| | | | |
|--------------------------|--------------------|------------------|------------------|
| <i>immediately after</i> | <i>0.97 ± 0.02</i> | <i>0.96±0.04</i> | <i>NS</i> |
| <i>Follow - up</i> | <i>0.99± 0.01</i> | <i>0.91±0.09</i> | <i>P<0.01</i> |

FFR and hyperemic Pd/Pa before & immediately after stenting, and at 6-month follow-up

| <u>FFR</u> | <i>DES</i> | <i>Bare metal</i> | <i>P value</i> |
|--------------------------|-----------------|-------------------|----------------|
| <i>before</i> | 0.61 ± 0.20 | 0.61 ± 0.16 | <i>NS</i> |
| <i>immediately after</i> | 0.90 ± 0.06 | 0.88 ± 0.07 | <i>NS</i> |
| <i>Follow-up</i> | 0.91 ± 0.05 | 0.83 ± 0.10 | $P < 0.01$ |

Hyperemic pressure ratio across stent

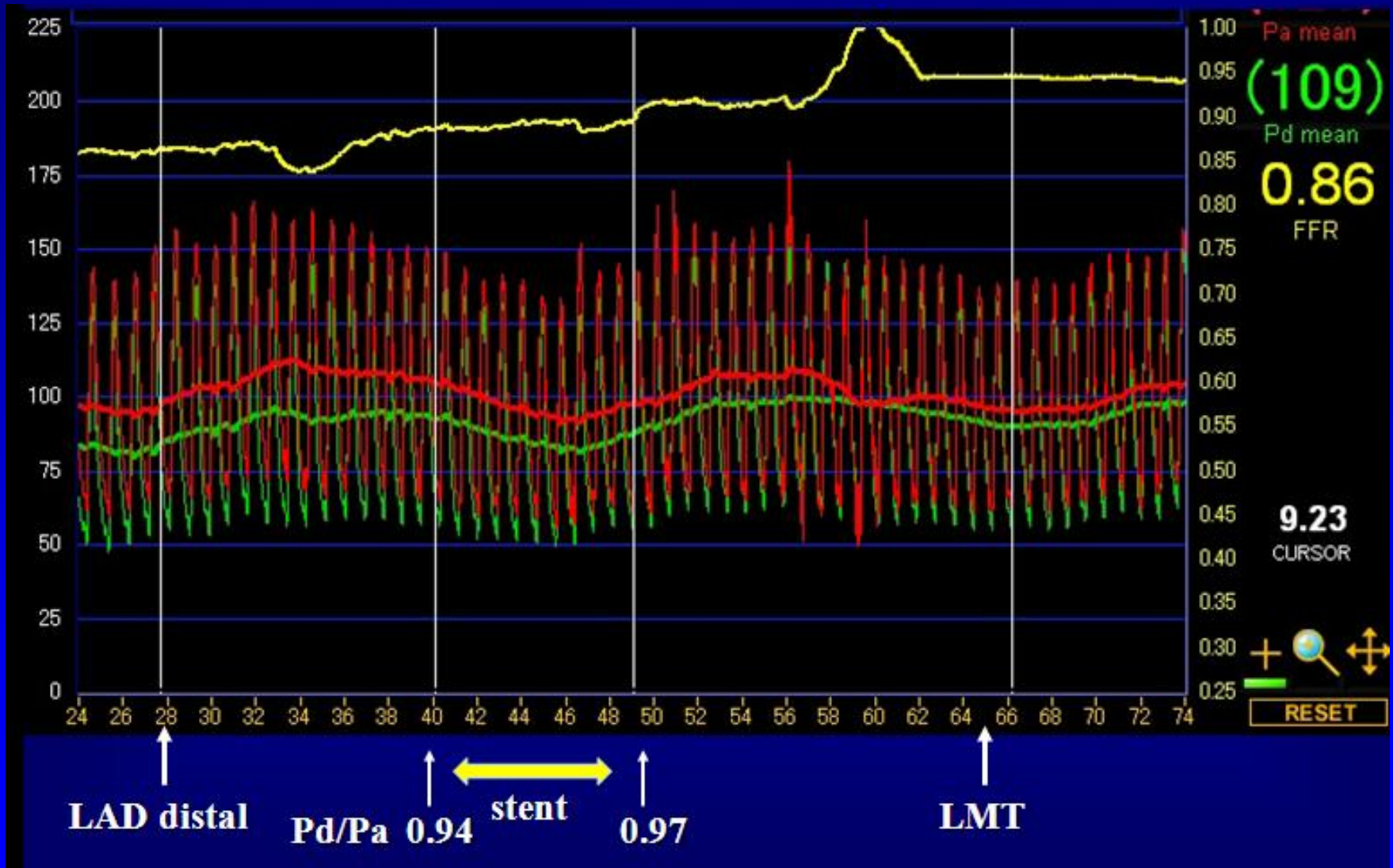
| | | | |
|--------------------------|-----------------|-----------------|------------|
| <i>immediately after</i> | 0.97 ± 0.02 | 0.96 ± 0.04 | <i>NS</i> |
| <i>Follow-up</i> | 0.99 ± 0.01 | 0.91 ± 0.09 | $P < 0.01$ |

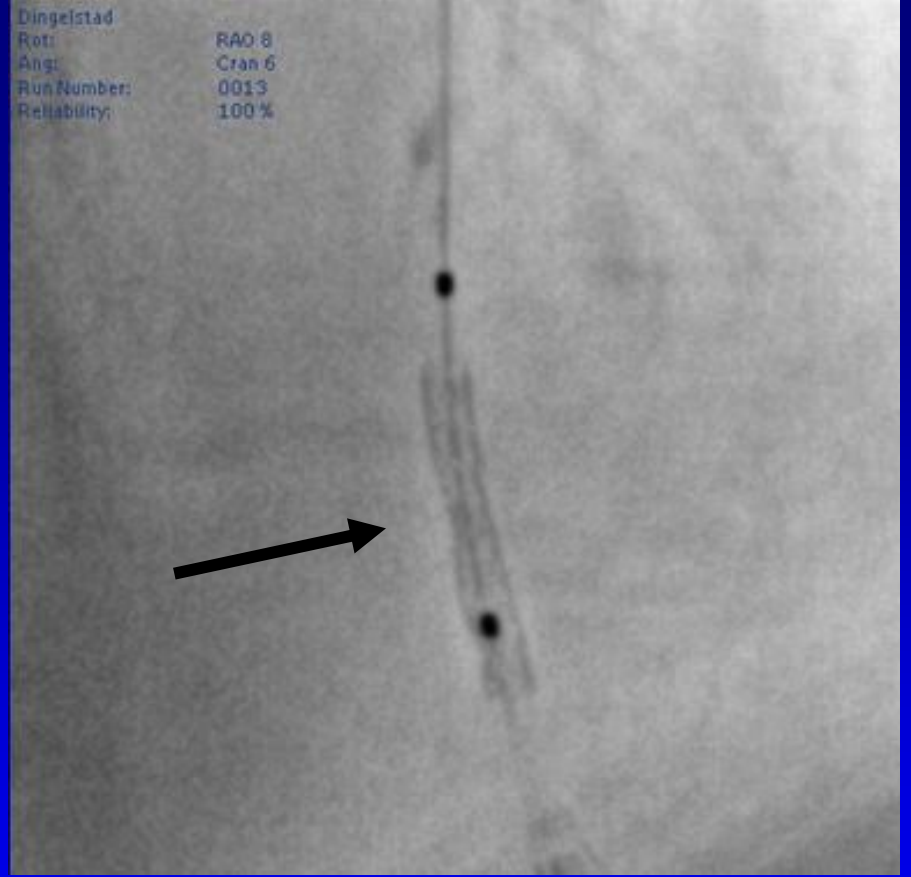
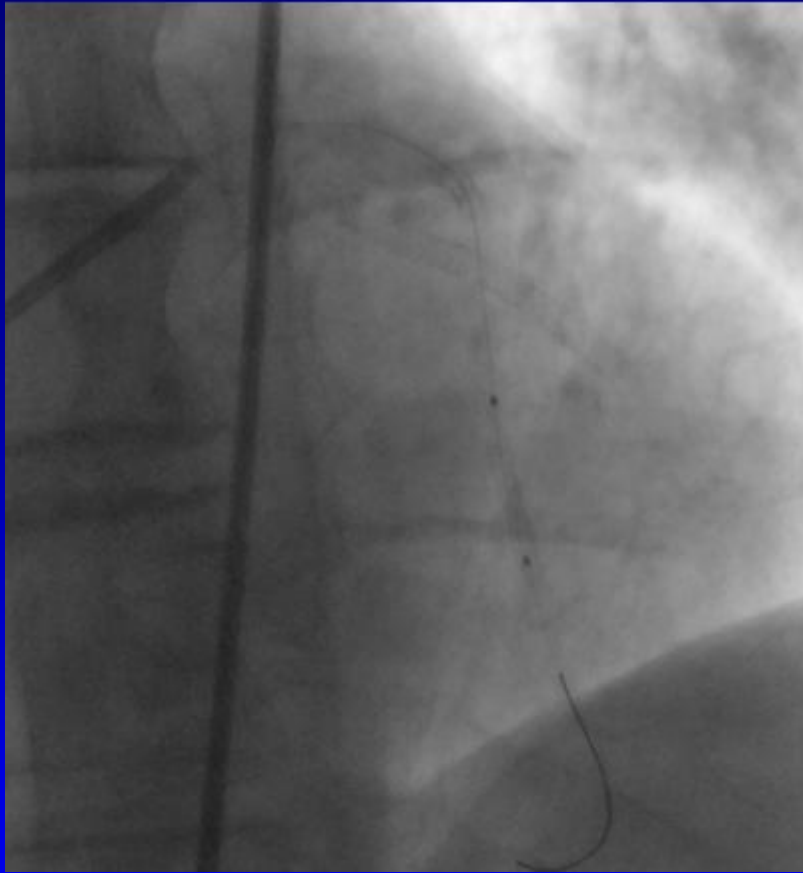


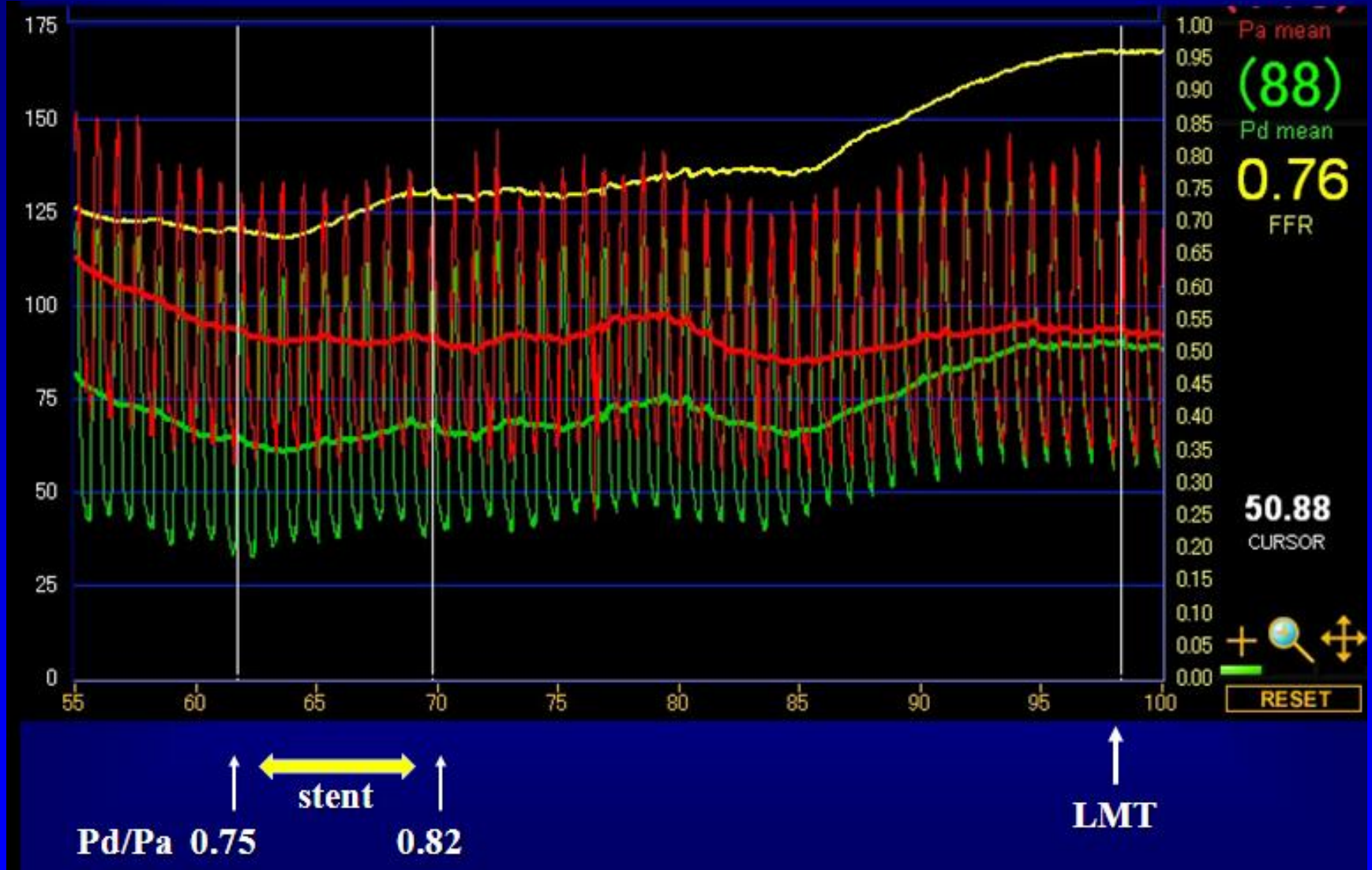
Stent boost technique

Tanaka et al, Japan Circulation J, 2012:
Stent boost vs FFR post-stenting

Imperfect stent boost → hyperemic grad ≥ 5 mmHg in 90% of cases
Opposite not true: of all cases with hyperemic grad ≥ 5 mmHg,
imperfect stent boost in 50% of cases only







FFR POST PCI: *Practice in Catharina Hospital*

- I. When we use pressure wire for deciding whether or not to stent, we use it as primary guidewire and standardly measure FFR post stenting
- II. After angiographically succesful stenting, place the sensor in distal third part of the artery (and at least distal to stented lesion(s) and induce hyperemia for pullback recording:
 - *i.v. adenosine infusion, preferably central line*
 - *i.v. peripheral bolus injection of 400 µg regadenoson*
 - *12-20 mg of i.c. papaverine*
- III. Perform manual pullback recording under fluoroscopy:
and check if remaining gradient is across stent or elsewhere in the coronary artery, accepting the consequences

FFR post PCI: CONCLUSIONS (1)

- If a stent is deployed adequately, only a negligible hyperemic gradient should be present across the stent
- if a hyperemic gradient of $>$ than 5 mm Hg persists **across** the stent, there is definitely a problem and IVUS or preferably OCT is indicated
- The opposite is not true: even without an hyperemic gradient, a stent can be insufficiently deployed (5 % of cases).
- Therefore, FFR post-stent cannot replace IVUS or OCT

FFR post PCI: CONCLUSIONS (2)

- FFR post PCI is *extremely useful to detect residual lesions or diffuse disease* with direct consequence for further treatment or preventing unnecessary repeat procedures when recurrent chest pain or ischemia occurs
- The hyperemic pressure pullback recording is the most accurate method to analyse the remaining disease along the coronary artery and cannot be replaced by any other technology

EINDE

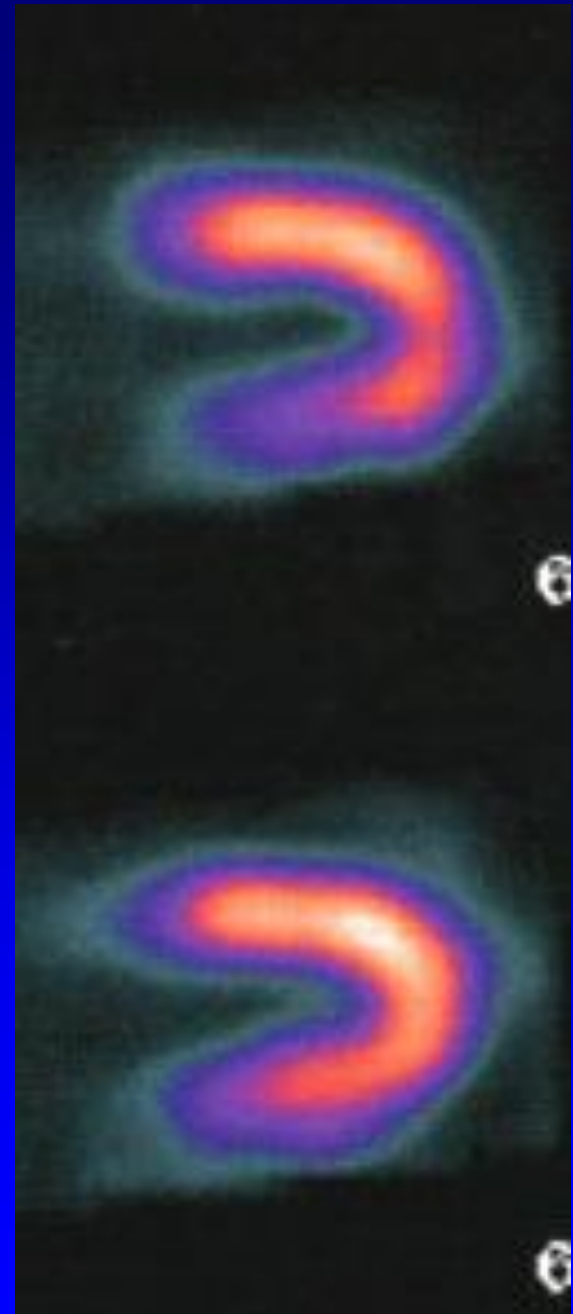
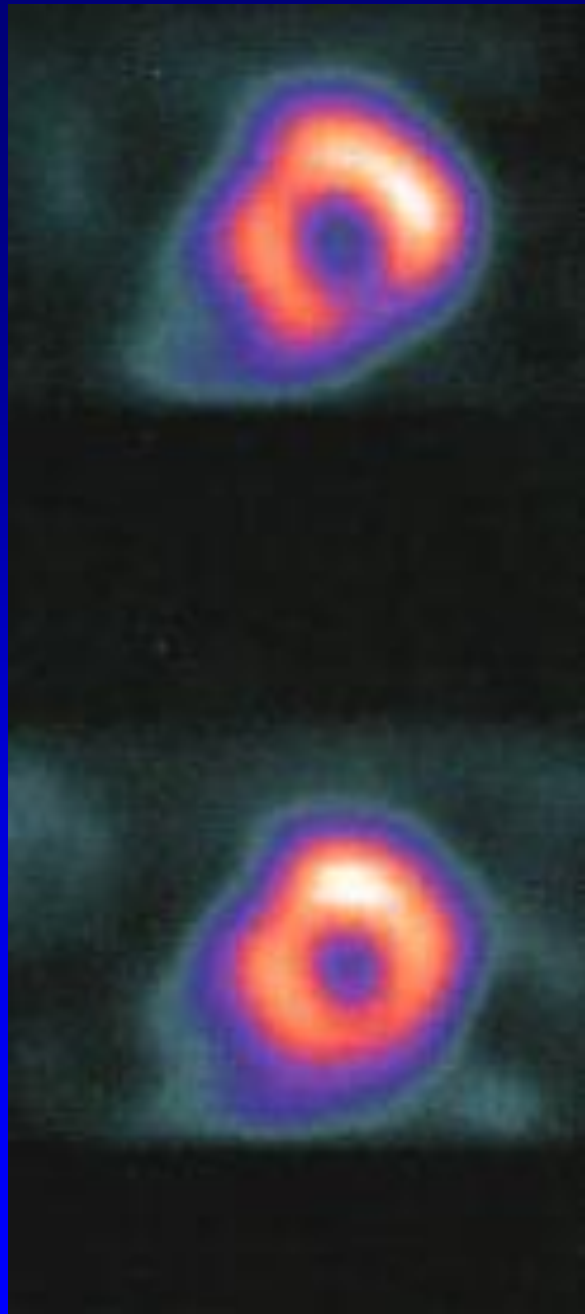
FFR: The Pressure Pull-back Curve

Pressure pull-back curve at maximum hyperemia:

- place sensor in distal coronary artery
- induce sustained maximum hyperemia by i.v. adenosine, or i.c. papaverine or peripheral bolus of regadenoson
- pull back the sensor slowly under fluoroscopy
- the individual contribution of every segment and spot to the extent of disease can be studied in this way

Coronary pressure is unique in this respect and such detailed spatial information cannot be obtained by any other invasive or non-invasive method

roughly
identical MIBI
in all 3
patients:
reversible
defect
inferior wall



Nu voorbeelden:

1x sprongetje over stent waarna verdere inflatie

1x sprongetje elders

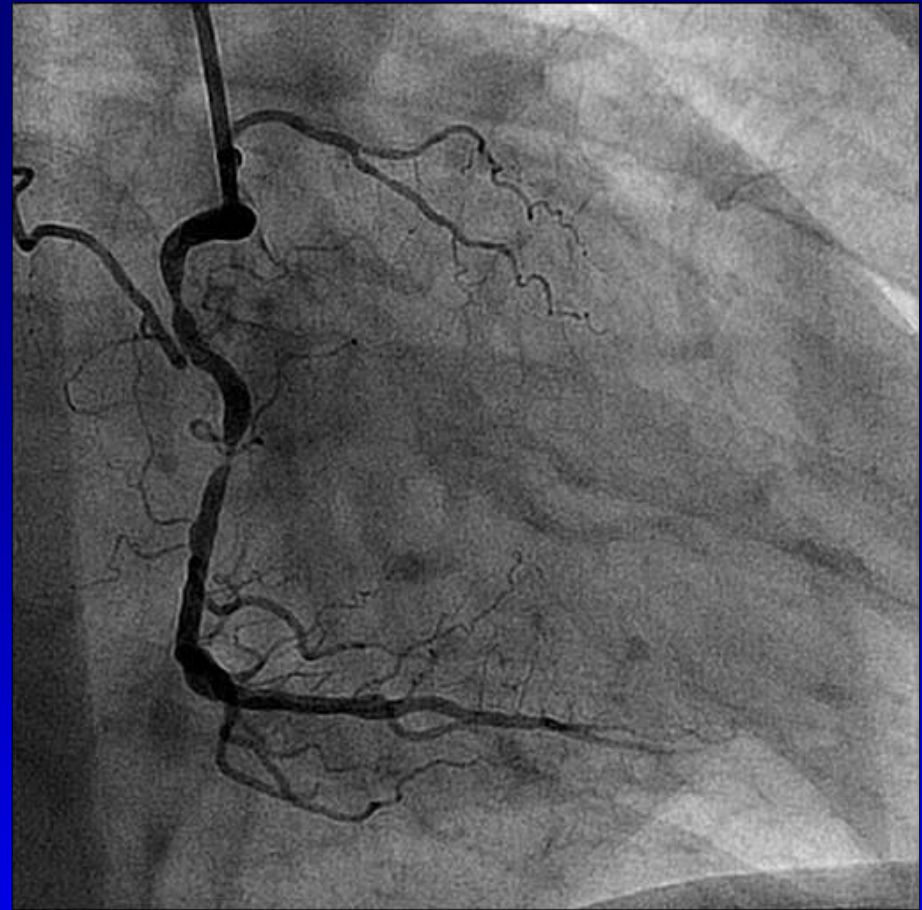
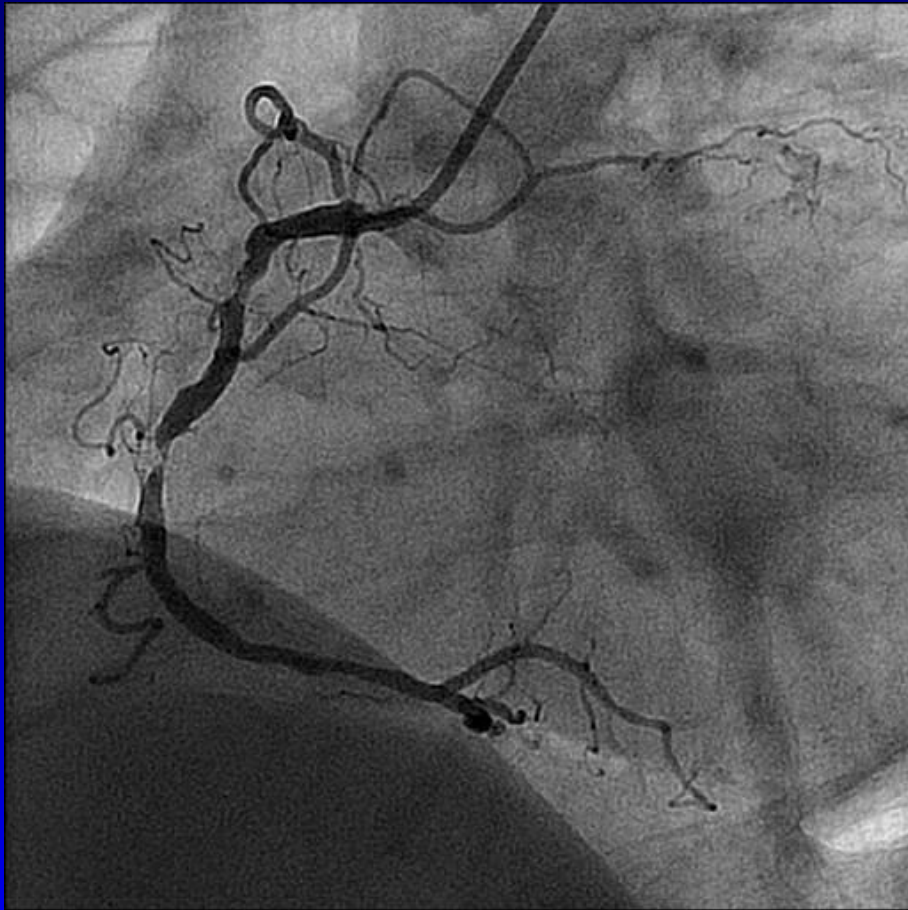
1x diffuse ziekte

CASE # 2

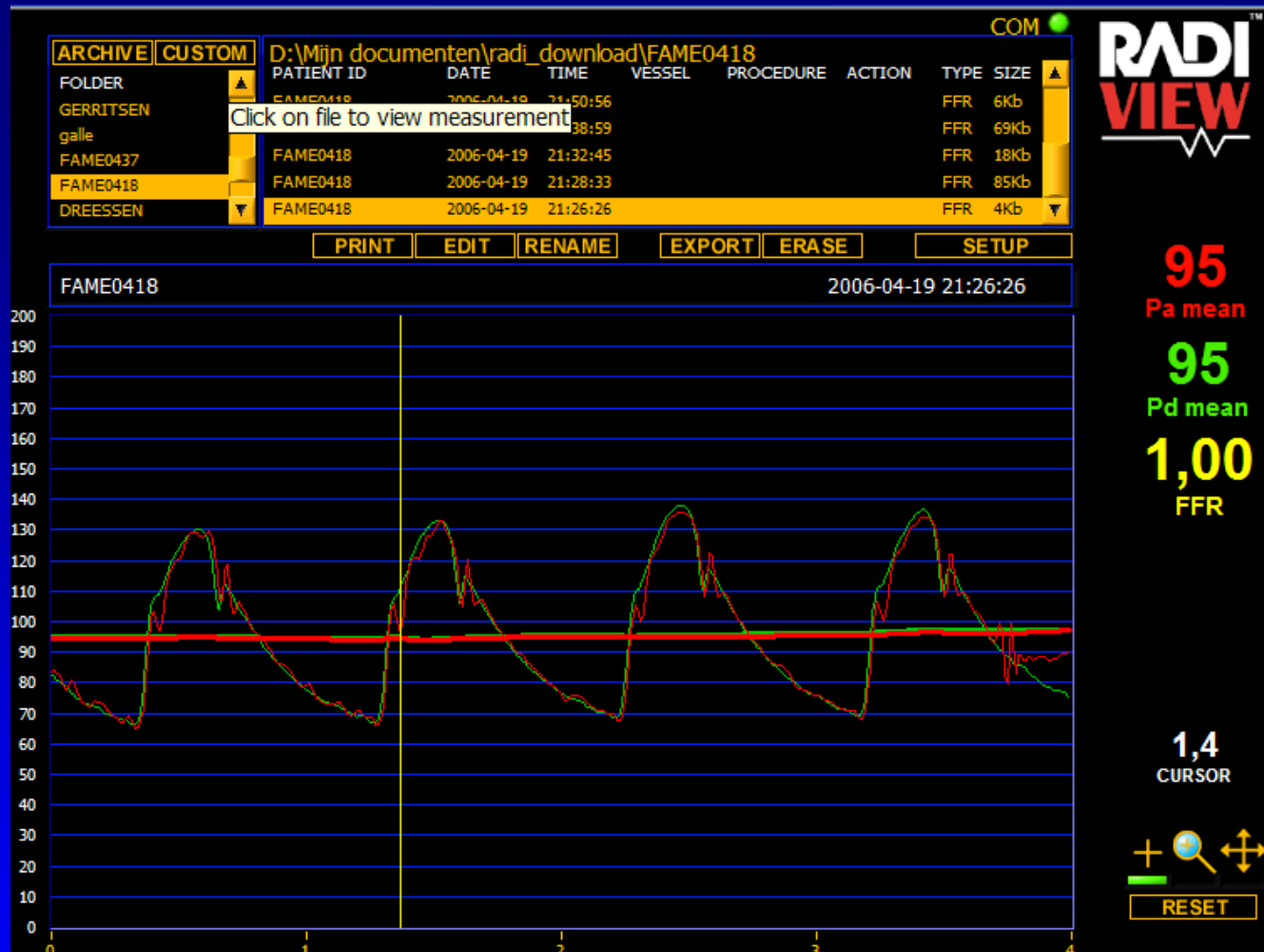Mr. W.G., born 29-07-1941 (65-year-old)

- hypercholesterolemia, borderline hypertension
- typical chest pain at exercise, class III
- normal LV at echo
- frankly positive exercise test at 100 W (= 64 %)

→ *coronary angiography*

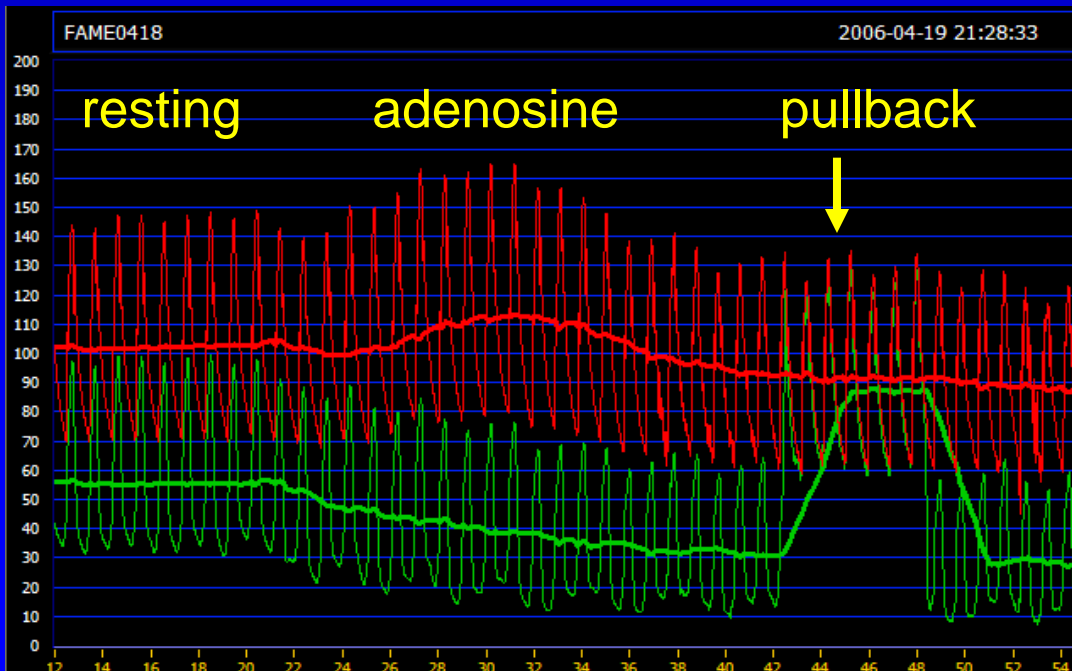
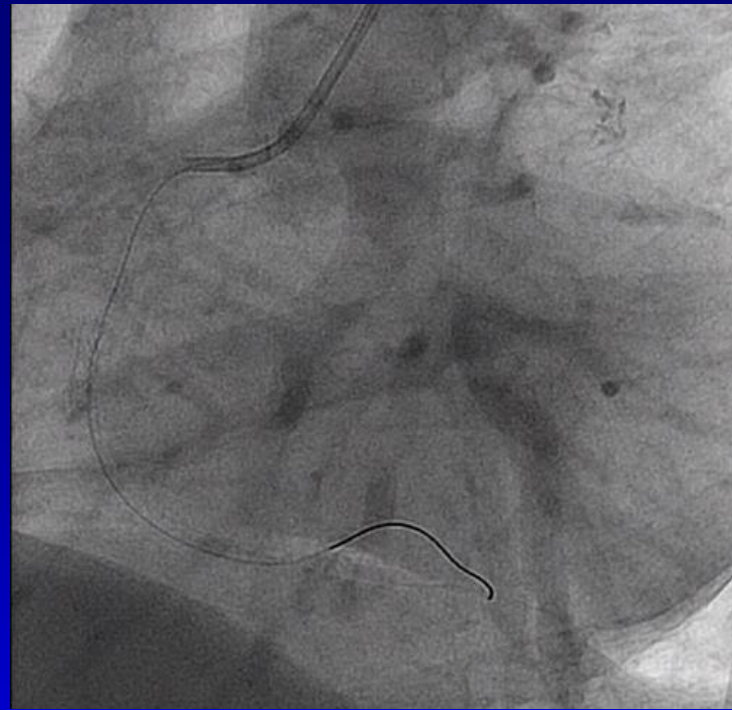
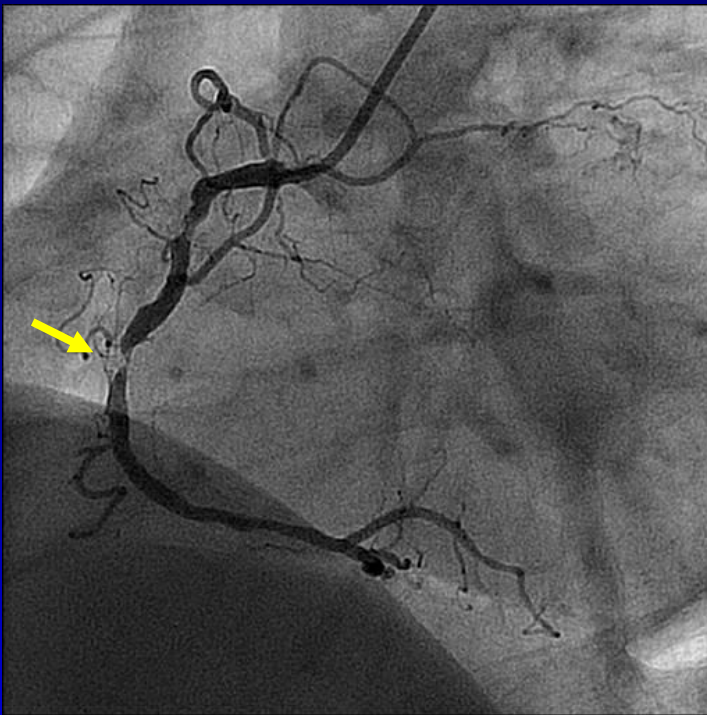


RCA: Tandem lesion



Start of procedure:

sensor close to tip of JR guiding catheter to verify equal pressures at that point



RCA:

FFR = 0.34

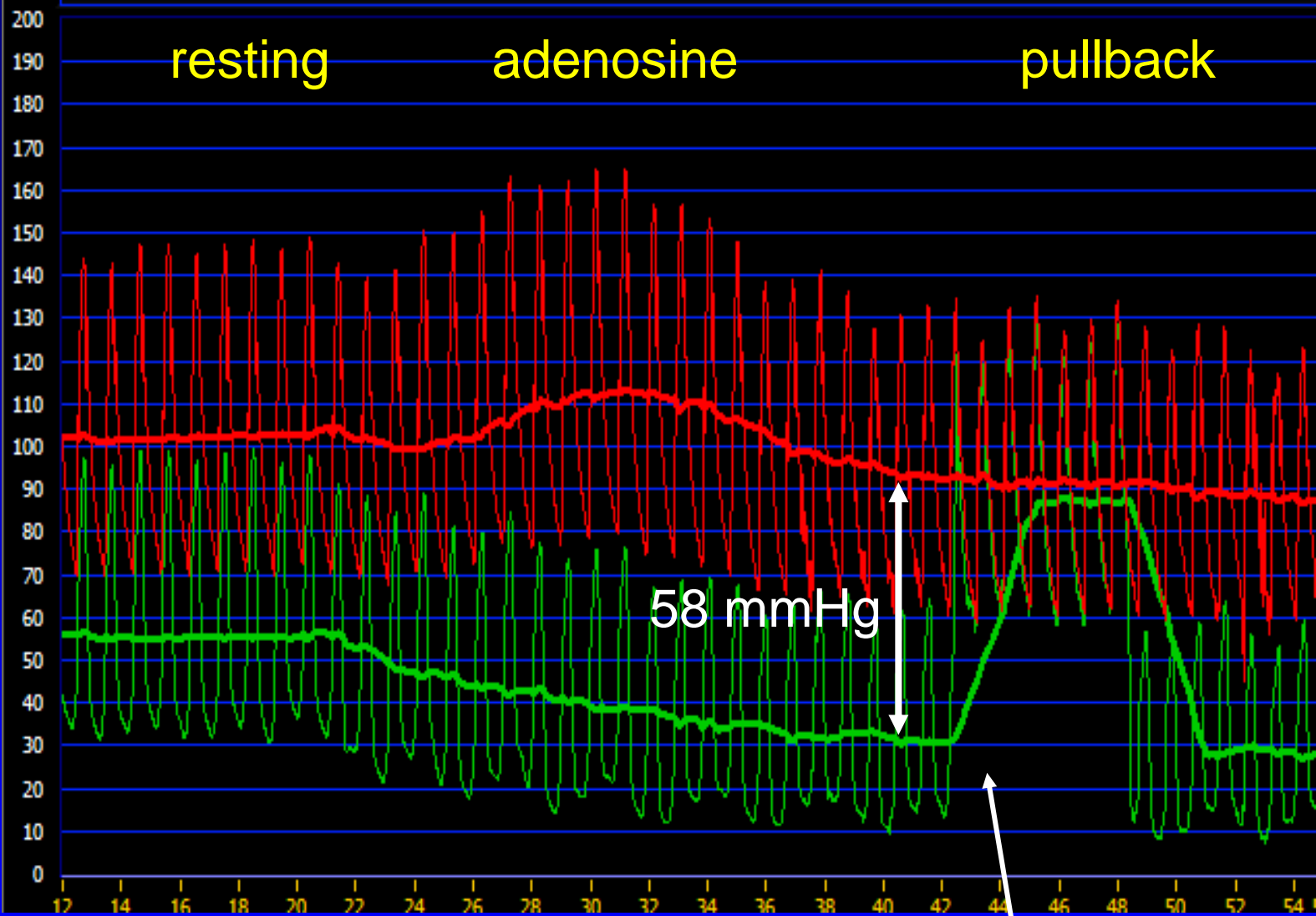
FAME0418

2006-04-19 21:28:33

resting

adenosine

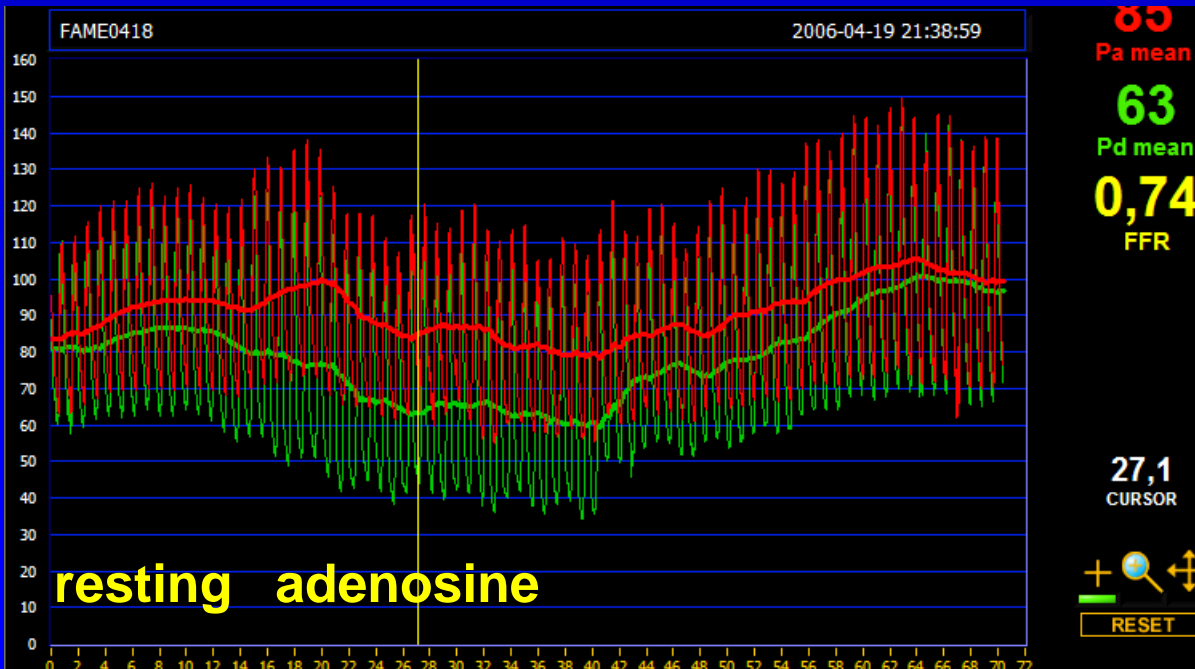
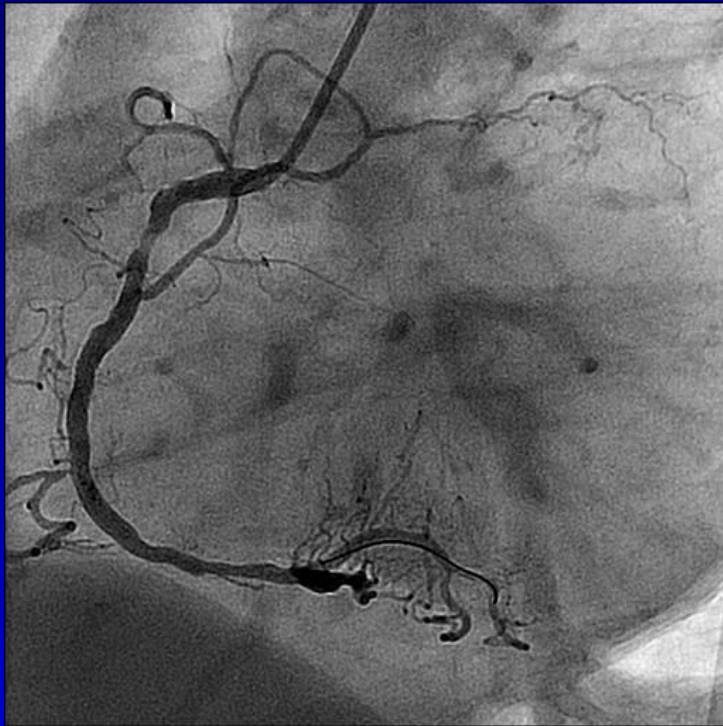
pullback



↕ 5 mmHg

58 mmHg

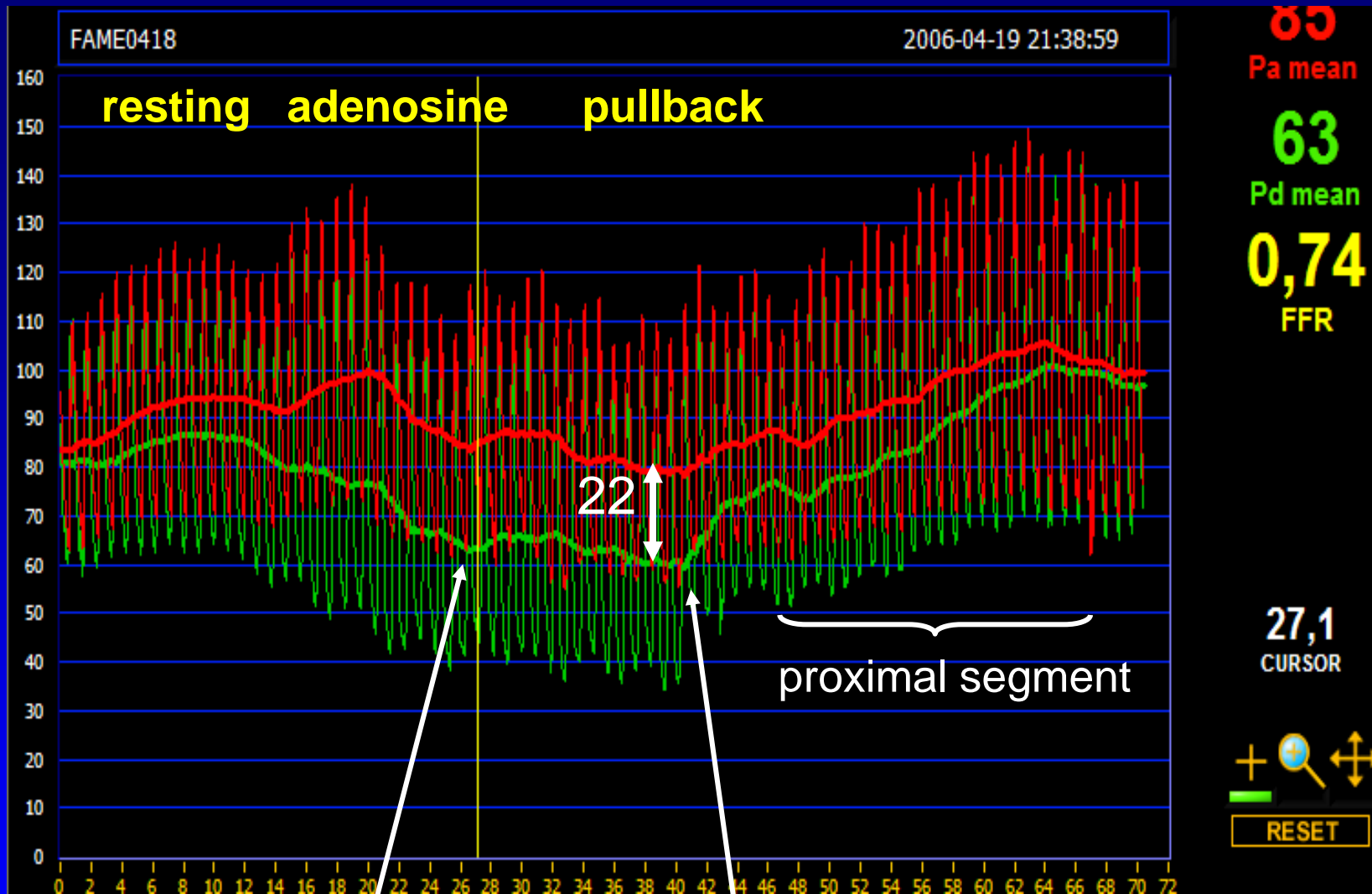
Pull-back across distal stenosis



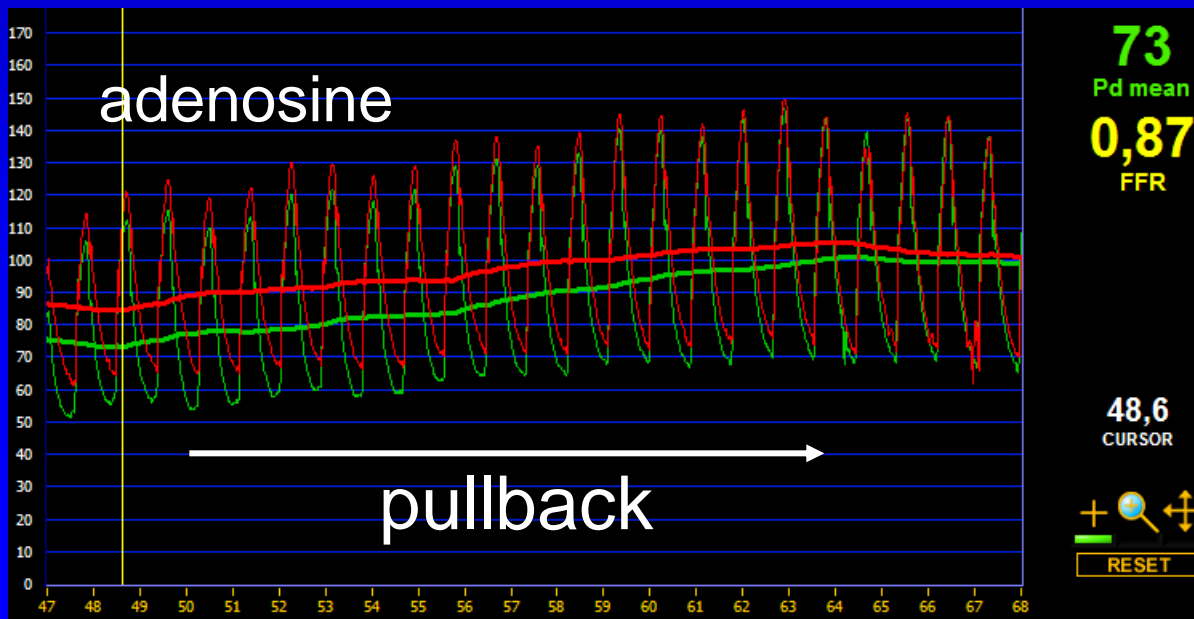
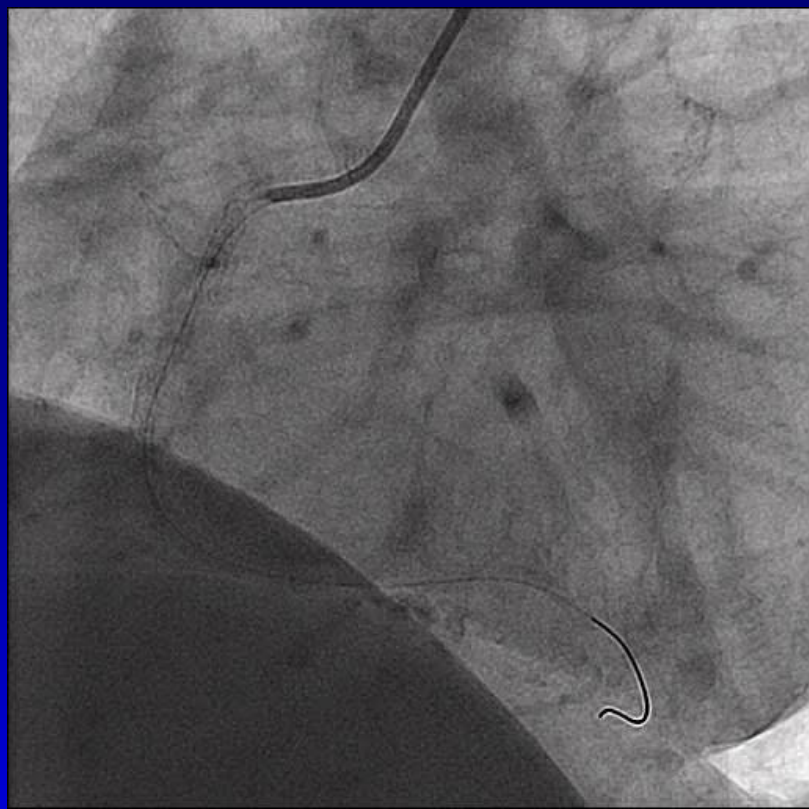
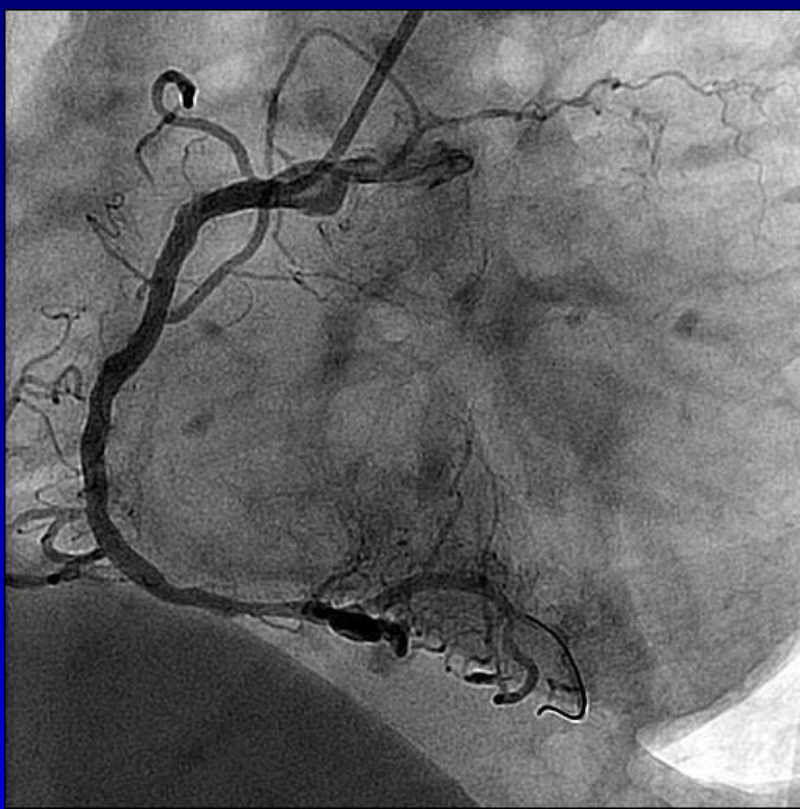
RCA after
one stent:

FFR = 0.74

FFR 0.34 → 0.74

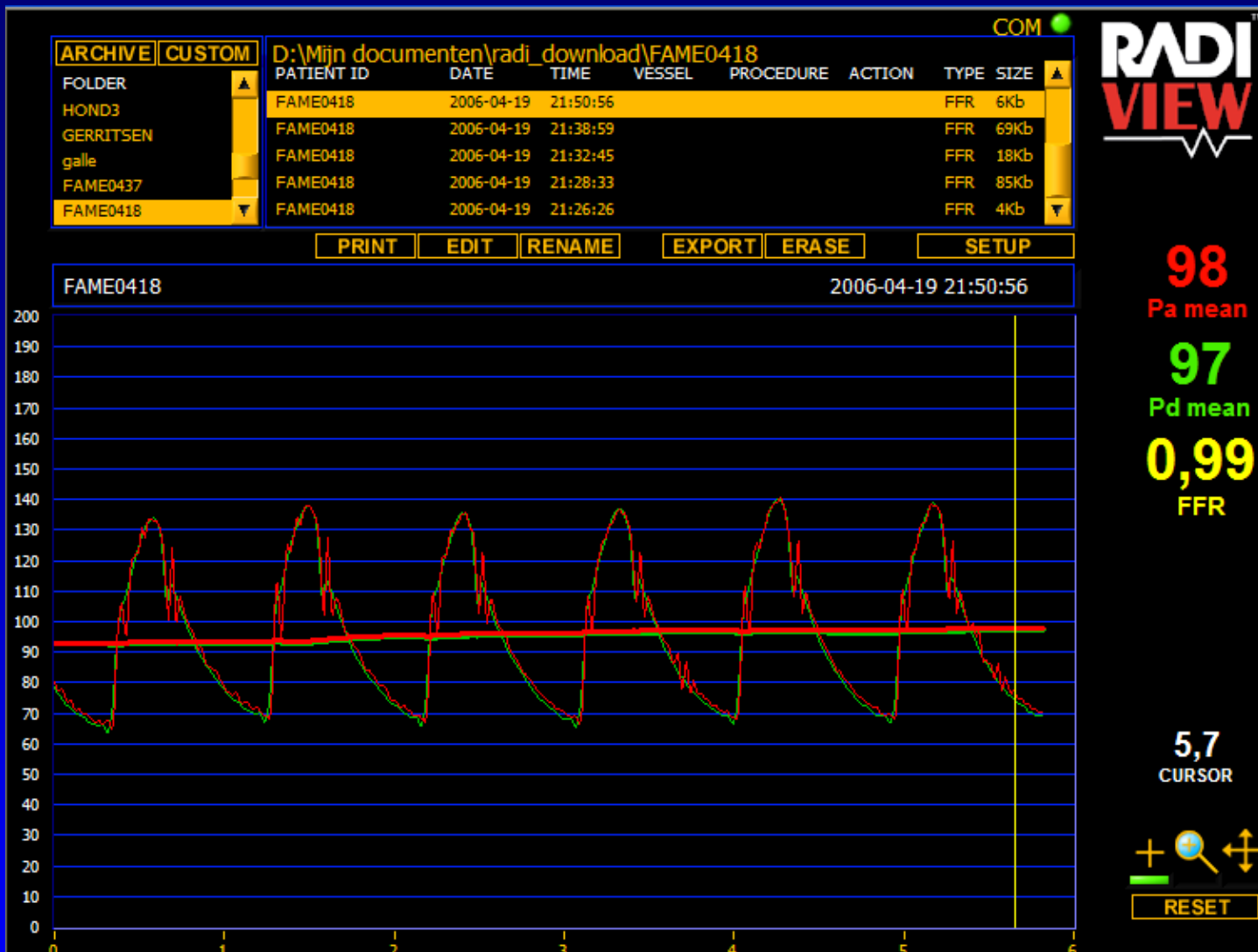


pullback across stent & across proximal stenosis
58 → ~ 0 mmHg 5 → 22 mmHg



RCA
after 2 stents:

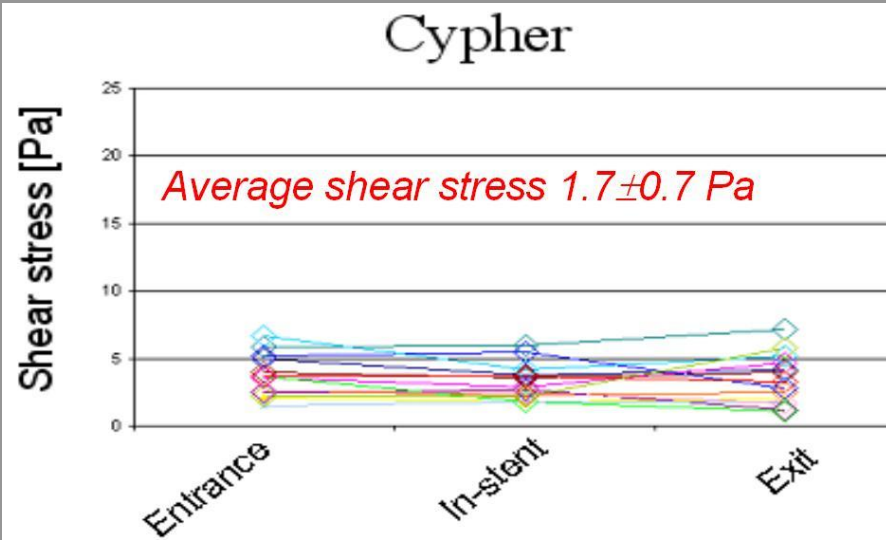
FFR = 0.87



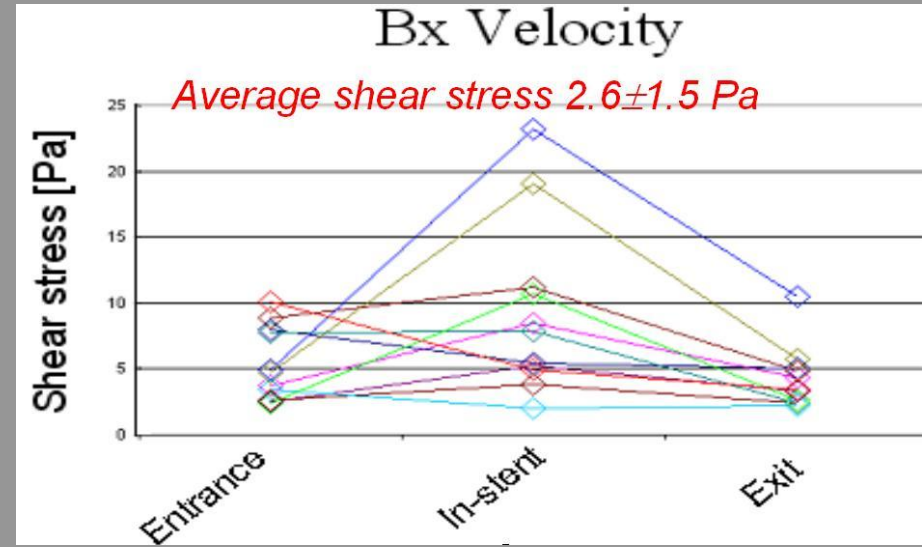
Pressure sensor back at the ostium of the RCA

Shear stress within and hyperemic gradient across stent at baseline and follow-up

DES



Bare metal



| | DES | Bare metal | F-value |
|------------|----------------|----------------|----------|
| Just after | 1 ± 2 mmHg | 2 ± 2 mmHg | $P=NS$ |
| Follow-up | 3 ± 3 mmHg | 9 ± 8 mmHg | $P<0.01$ |