

EP CASE REPORT

Recurrent ventricular tachycardia arising at the treatment borderzone after stereotactic radioablation in a patient with ischemic cardiomyopathy

Pierre C. Qian^{1,2}, Kenneth Quadros^{1,2}, Martin Aguilar^{1,2}, Raymond Mak^{2,3}, Paul Zei^{1,2}, and Usha B. Tedrow^{1,2*}

¹Cardiovascular Division, Department of Medicine, Brigham and Women's Hospital, 75 Francis St, Boston, MA 02115, USA; ²Harvard Medical School, Boston, MA, USA; and ³Department of Radiation Oncology, Dana-Farber Cancer Institute and Brigham and Women's Hospital, Boston, MA, USA

* Corresponding author. Tel: 8573071947; fax: 8573071944. E-mail address: utedrow@bwh.harvard.edu

The patient was a 77-year-old man with ischaemic cardiomyopathy, two prior coronary artery bypass surgeries, left-ventricular ejection fraction 15% with severe mitral regurgitation, and recurrent ventricular tachycardia (VT) causing syncope and implantable cardioverter-defibrillator (ICD) shocks despite amiodarone, quinidine, and mexiletine. He underwent catheter ablation at an outside hospital targeting a clinical VT exiting inferolaterally from a large anteroseptal scar. Catheter manipulation induced poorly haemodynamically tolerated VTs requiring 25 defibrillations. Due to VT recurrence, diffuse substrate, and instability at index procedure, he underwent stereotactic radioablation (SBRT; 1 fraction of 25 Gy) in December 2018 directed at the anteroseptal and apical scar (Figure 1A and B). The basal anteroseptum was intentionally spared to preserve ICD lead, conduction system, and valvular function. Progressive VT cycle length prolongation (440–490 ms to 500–580 ms) was observed 5 days post-SBRT requiring lowering of detection rate. Implantable cardioverter-defibrillator shocks were reduced from 12 to 4, in the 3 months before and after treatment. No further device detected VT occurred by 4 months. His antiarrhythmics were tapered, whereupon frequent non-sustained and device-treated VT recurred,

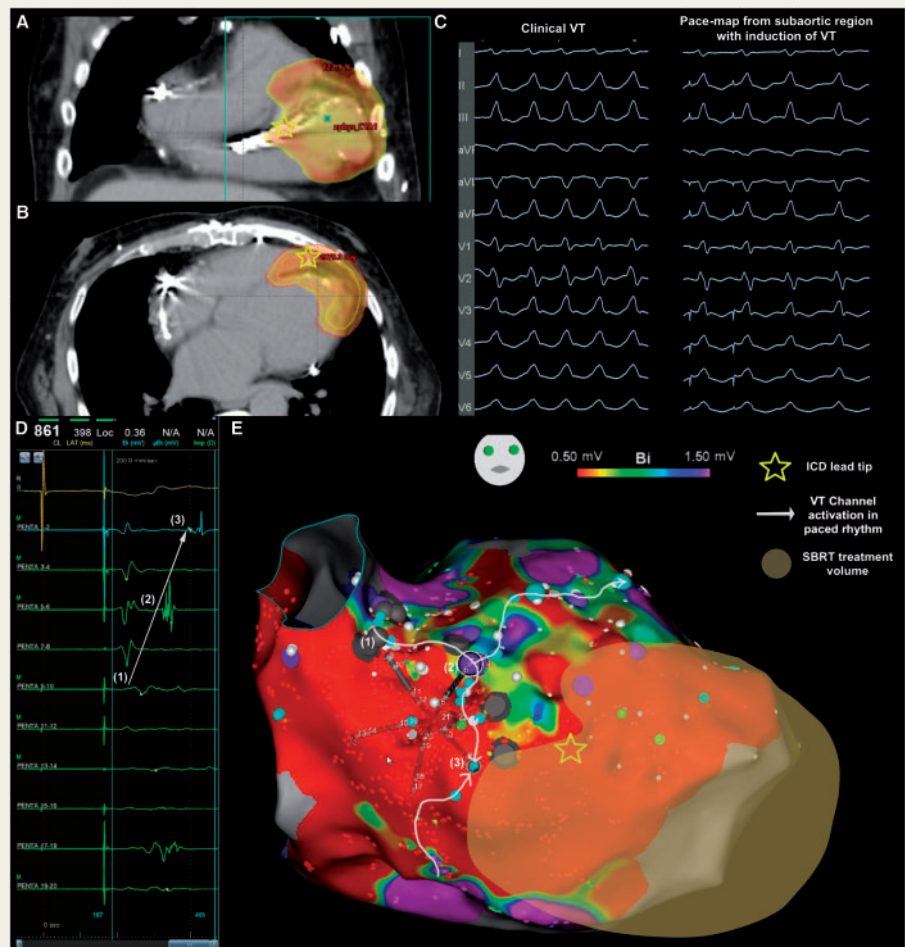


Figure 1 Recurrence of ventricular tachycardia from the basal periaortic region near the radioablation borderzone. Stereotactic radioablation was delivered to an anteroapical scar (orange) with sparing of the periaortic region basal to the ICD lead tip (star, Panel A and B). Panel C shows the clinical tachycardia and excellent pace-maps from the subaortic region near site (2) in Panel E. Activation of the channel in paced rhythm is recorded on the PentaRay (Panel D), along the superior edge of a dense confluent scar consistent with the SBRT treatment zone, projected on the voltage map as an interpolation from planning images (Panel E). ICD, implanted cardiac defibrillator; SBRT, stereotactic radioablation therapy; VT, ventricular tachycardia.

cycle length 460–580 ms, with a periaortic exit (Figure 1C), leading to further ICD shocks. Repeat catheter ablation was performed at our centre. The clinical VT was easily inducible with catheter ectopy and pacing, utilizing a critical channel along the superior boundary of a dense confluent scar corresponding to the SBRT treated area (Figure 1D and E). Radiofrequency ablation was delivered to modify the arrhythmogenic substrate; no reinductions were attempted due to tenuous haemodynamic status. At follow-up, only one brief episode of non-sustained VT was detected on ICD check at 2 months, and all antiarrhythmics were discontinued. He continued to remain free of device-treated VT, however due to progressive and refractory end-stage heart failure was palliated at home and passed away at 4 months post-procedure.

Radioablation was initially successful with late recurrence of new VT at the treatment borderzone in this patient. The mechanism for radioablation-mediated arrhythmia suppression is poorly understood. Myocytes are resistant to radiation induced apoptosis, but capillary injury and microvascular ischaemia leads to replacement fibrosis over many months.¹ However, radioablation treatment effect occurs much earlier, in days to weeks, a time-window that correlates better with myocyte dysfunction associated with increased cell membrane permeability, altered calcium handling, mitochondrial dysfunction, and intercalated disk injury.^{2,3} As the radiobiology of myocardial injury is complex, involving both parenchymal and stromal compartments at varying kinetics, therapeutic dose may differ in myocardial scar compared with normal myocardium. Furthermore, the syncytial nature of myocardium lends itself to 'bystander effects' mediated by diffusion of intracellular signalling from injured myocytes to neighbouring penumbral myocardium. These factors make it plausible that under-dosing or incomplete coverage of myocardial scar could be proarrhythmic from enhanced automaticity or altered conduction properties. This initial report of high-density electroanatomical mapping of myocardial scar after SBRT underscores the need to better understand the radiobiology and electrophysiological changes occurring post-therapy to optimize dosing and treatment delivery for VT.

Conflict of interest: U.B.T. has received speaking honoraria from Abbott Medical, Biosense Webster, Medtronic, and Boston Scientific, and consulting fees from Thermedical Inc. P.Z. has received research support and consulting fees from Biosense Webster, Cyberheart, Inc., and consulting fees from Varian, Inc. All remaining authors have declared no conflicts of interest.

Funding

P.C.Q. has received a Bushell Travelling Fellowship from the Royal Australasian College of Physicians. M.A. has received a George Mines Travelling Fellowship from the Canadian Heart Rhythm Society.

References

1. Fajardo LF, Stewart JR. Capillary injury preceding radiation-induced myocardial fibrosis. *Radiology* 1971;**101**:429–433.
2. Sag CM, Wolff HA, Neumann K, Opiela M-K, Zhang J, Steuer F et al. Ionizing radiation regulates cardiac Ca handling via increased ROS and activated CaMKII. *Basic Res Cardiol* 2013;**108**:385.
3. Cilliers GD, Harper IS, Lochner A. Radiation-induced changes in the ultrastructure and mechanical function of the rat heart. *Radiother Oncol* 1989;**16**:311–326.