

EP CASE REPORT

Cryoballoon ablation performed with a novel EP mapping system

Riccardo Maj*, Gianluca Borio, Alessandro Rizzo, Thiago Guimarães Osório, Carlo De Asmundis, and Gian Battista Chierchia

Heart Rhythm Management Center, UZ Brussel-VUB, Laarbeeklaan 101, 1090 Brussels, Belgium

* Corresponding author. Tel: +39/32 00879472. E-mail address: maj.riccardo@gmail.com

Cryoballoon (CB) ablation is an established tool to perform pulmonary vein isolation (PVI) in patients with atrial fibrillation (AF). Traditionally, PVI is achieved by application of forward pressure to ensure the optimal balloon-to-pulmonary vein (PV) ostium contact and optimal occlusion of the PV.¹ Pulmonary veins occlusion is considered optimal when selective iodine contrast injection shows total contrast retention, without any back-flow into the left atrium (LA); once occlusion is documented, cryoenergy can normally be delivered. Still, to visualize correctly the PVs anatomy, pre-ablation pulmonary venography, or computed tomography (CT)-derived anatomy are needed. We report the case of a 61-year-old man who underwent

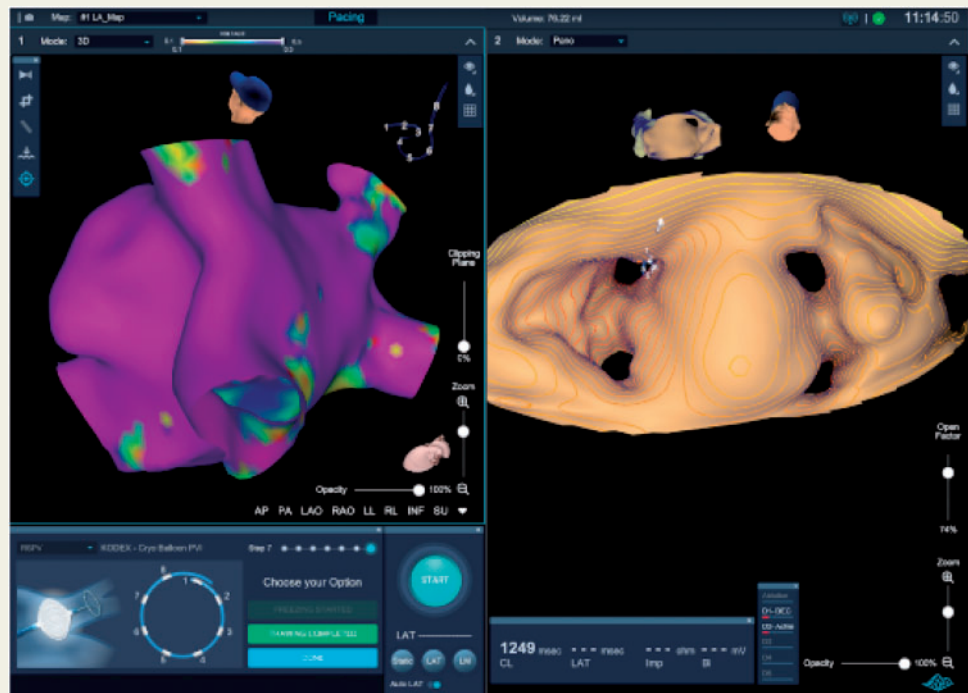


Figure 1 Left atrial anatomy obtained before the ablation using the Achieve spiral catheter, showing normal voltages of the LA (left) and accurate definition of the PVs ostia (right).

CB ablation with a 4th-generation CB for paroxysmal AF, guided by the KODEX-EPD (EPD Solutions, a Philips company, Best, The Netherlands), a novel three-dimensional cardiac imaging, mapping, and navigation system. This mapping system uses a novel di-electric sensing, allowing CT-like visualization of cardiac anatomy from the inside of the heart^{2,3}; no ionizing radiation, contrast medium or contact with the endocardium is required with this technique. Moreover, since the new KODEX-EPD system is an open platform that works with any validated electrophysiology catheter, it can be used for generating high-quality images without the need for pre-acquired imaging or additional material.

In our case, left atrial anatomy was reconstructed by means of a traditional spiral 10-polar mapping catheter with a distal loop diameter of 25 mm (Achieve Advance, SMC2, Medtronic, MN, USA); no additional equipment was needed, neither any change in the customary procedure flow. Voltage map of the LA was created before the ablation, displaying normal voltages (Figure 1, left) and confirming the appropriateness of PVI-only ablation strategy. Furthermore, a detailed anatomy of the PVs ostia was visualized (Figure 1, right). After positioning the spiral mapping catheter at the proximal site in the PV ostium prior to ablation, a baseline measurement representative of normal blood flow from the PVs to the LA was performed. Then, once the CB was inflated and properly positioned, the KODEX-EPD system allowed the quantification of the grade of CB occlusion at each vein by detecting changes in blood flow using dielectric sensing with the Achieve mapping

catheter. The high grade of occlusion was then confirmed by the usual technique (i.e. contrast injection and X-ray). Cryoapplications were then performed according to our usual ablation sequence. Isolation was achieved and documented in all PVs (left superior pulmonary vein: 93 s, -55°C ; left inferior pulmonary vein: 40 s, -36°C ; right inferior pulmonary vein: 114 s, -47°C ; right superior pulmonary vein: 53 s, -47°C), mean nadir temperatures of all cryoapplications was -54.2°C ; no complications occurred. In conclusion, the novel KODEX-EPD system might be of great advantage during CB ablation, allowing the generation of high-definition images without the need for prior CT images, the creation of left atrial voltage maps and the quantification of the grade of CB occlusion.

Conflict of interest: CDA receive compensation for teaching purposes and proctoring from AF solutions, Medtronic, Abbott, Biotronik, Atricure and research grants on behalf of the centre from Biotronik, Medtronic, St Jude Medical Abbot, Livanova, Boston Scientific, Biosense Webster. GBC receive compensation for teaching purposes and proctoring from AF solutions Medtronic and Biotronik.

References

1. Su W, Kowal R, Kowalski M, Metzner A, Svinarich JT, Wheelan K et al. Best practice guide for cryoballoon ablation in atrial fibrillation: the compilation experience of more than 3000 procedures. *Heart Rhythm* 2015;**12**:1658–66.
2. Romanov A, Dichterman E, Schwartz Y, Ibragimov Z, Ben-David Y, Rodriguez H et al. High-resolution, real-time, and nonfluoroscopic 3-dimensional cardiac imaging and catheter navigation in humans using a novel dielectric-based system. *Heart Rhythm* 2019;**16**:1883–9.
3. Nicholls M. KODEX-EPD mapping for AF ablation. *Eur Heart J* 2019;**40**:3003–5.