

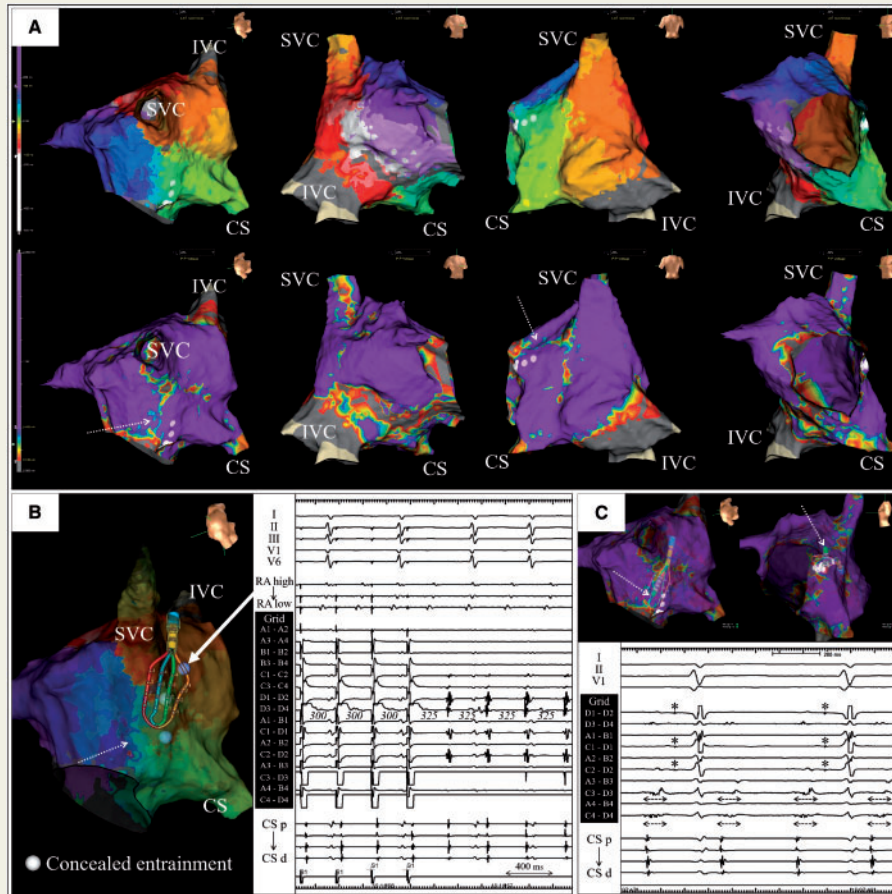
## EP CASE REPORT

# Upper loop re-entry atrial flutter with its critical isthmus identified in the vicinity of his bundle

Tomoki Watanabe, Nobuhiro Takasugi \*, Genki Naruse, and Hiroyuki Okura

Division of Cardiovascular Medicine, Gifu University Hospital, 1-1 Yanagido, Gifu 501-1194, Japan

\* Corresponding author. Tel: +81 58 230 6523; fax: +81 58 230 6524. E-mail address: sunanezumi417@yahoo.co.jp



**Figure 1** (A) Right atrial activation (upper panel) and voltage maps (lower panel) during the flutter demonstrating its re-entry circuit rotating around the SVC and a linear scar along the anteroseptal wall, with a small area of preserved voltage and conduction near the tricuspid valve annulus (dashed arrows). From left to right, cranial–caudal, right anterior oblique, posterior–anterior, and left anterior oblique views of the RA. White tags represent sites where the His-bundle potential was recorded. (B) (Left panel) Bipolar activation map of the RA in the left anterior oblique cranial view, demonstrating sites of concealed entrainment (white tags). Dashed arrow indicates an area of the linear scar. (Right panel) Body surface ECG (I, II, III, V1, and V6) and intracardiac electrograms demonstrating concealed entrainment from the site near SVC (white solid arrow). Numbers in italic denote cycle length (ms). (C) (Upper panel) Bipolar voltage maps of the RA in the cranial–caudal (left) and left lateral (right) views, showing electrode catheters position (a site of successful radiofrequency ablation). White tags represent sites where the His-bundle potential was recorded. (Lower panel) Body surface ECG (I, II, and V1) and intracardiac electrograms during atrial flutter. Note that the low-voltage fractionated potentials lasting 100 ms (double-headed arrows) and the His-bundle potentials (asterisks) were simultaneously recorded in the grid mapping catheter. CS d, coronary sinus distal; CS p, coronary sinus proximal; CS, coronary sinus; ECG, electrocardiogram; IVC, inferior vena cava; RA, right atrium; SVC, superior vena cava.

A 62-year-old man with a history of mitral valve repair and cavotricuspid isthmus ablation underwent radiofrequency (RF) catheter ablation for persistent atrial flutter. A 12-lead electrocardiogram showed atrial flutter with 2:1 atrioventricular conduction (flutter cycle length, 325 ms). The F-wave amplitude was higher in the precordial leads (horizontal plane) than in the limb leads (frontal plane) (data not shown). The right atrial activation and voltage maps during the flutter demonstrated its re-entry circuit rotating around the superior vena cava (SVC) and a linear scar in the anteroseptal wall (Supplementary material online, *Movie S1* and *Figure 1A*). The scar contained a small area of preserved voltage near the tricuspid valve annulus (dashed arrows in *Figure 1A–C*). The low-voltage fractionated potentials lasting 100 ms, suggesting a critical area of slow conduction, and the His-bundle potentials were simultaneously recorded in the grid mapping catheter (*Figure 1C*). Concealed entrainment was demonstrated by pacing from multiple sites around the SVC (*Figure 1B*). Thus, a diagnosis of upper loop re-entry (ULR) atrial flutter was made. A single RF application at the area of slow conduction, 15 mm superolateral to the site recording the His-bundle potential (*Figure 1C*), successfully terminated the flutter.

Upper loop re-entry is a rare form of atypical atrial flutter<sup>1</sup> and an area of slow conduction exists in the upper portion of crista terminalis (CT) where ablation is successful in eliminating the circuit.<sup>2</sup> Our case suggests that an area of slow conduction in the ULR circuit does not always exist in the CT and that a detailed voltage map may be helpful to determine the site at which RF ablation should be performed.

## Supplementary material

Supplementary material is available at *Europace* online.

**Conflict of interest:** none declared.

## References

1. Bun SS, Latcu DG, Marchlinski F, Saoudi N. Atrial flutter: more than just one of a kind. *Eur Heart J* 2015;**36**:2356–63.
2. Huang JL, Tai CT, Lin YJ, Huang BH, Lee KT, Higa S et al. Substrate mapping to detect abnormal atrial endocardium with slow conduction in patients with atypical right atrial flutter. *J Am Coll Cardiol* 2006;**48**:492–8.