

## EP CASE REPORT

### Atrial fibrillation cryoablation in cor triatriatum dexter

Stylianos Tzeis<sup>1</sup>\*, Dimitrios Asvestas<sup>1</sup>, Eleftherios Sakadakis<sup>1</sup>, Chrisanthi Trika<sup>2</sup>, and Panos Vardas<sup>1</sup>

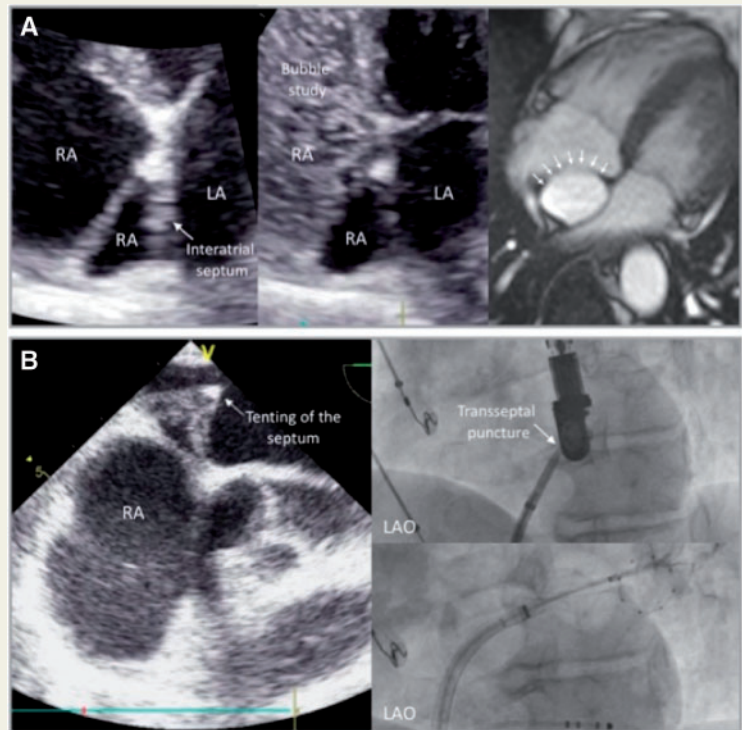
<sup>1</sup>Department of Cardiology, Mitera General Hospital, Hygeia Group, 6, Erithrou Stavrou, Maroussi, Athens 15123, Greece; and <sup>2</sup>Department of Cardiology, Henry Dunant Hospital Center, Athens, Greece

\* Corresponding author. Tel: +30 210 6869777; fax: +30 210 6869761. E-mail address: stzeis@otenet.gr

A 62-year-old male patient with symptomatic paroxysmal atrial fibrillation (AF) was scheduled for cryoablation. A preprocedural transthoracic echocardiogram was performed and demonstrated a membranous structure dividing the right atrium into two parts. Intravenous injection of agitated saline mixed with air (bubble study) from the left arm revealed blood flow from the superior vena cava to the right ventricle opacifying one of the two chambers. A diagnosis of cor triatriatum dextrum was confirmed by magnetic resonance imaging (Figure 1A). Due to this malformation, the transeptal puncture was guided intraprocedurally by transoesophageal echocardiogram. During the transeptal puncture, the wire and the long transeptal sheath/dilator were advanced from the inferior vena cava to the superior vena cava without difficulty. Access to the left atrium was achieved and pulmonary vein isolation was performed without complications (Figure 1B). The patient remains free of AF recurrences during the last 18 months.

Cor triatriatum dexter is a rare cardiac abnormality characterized by subdivision of the right atrium into two chambers, usually an anterior or distal chamber, communicating with the tricuspid valve and the coronary sinus and a posterior or proximal chamber including the fossa ovalis and receiving blood flow from the superior and inferior vena cava.<sup>1</sup> Cor triatriatum dexter is caused by the persistence of the right valve of the sinus venosus. Normally, between the 6th and 8th week of embryogenesis, the right sinus valve separates the right atrium into two chambers. On the 12th week, the valve regresses into the crista terminalis, the eustachian valve, and the thebesian valve. Failure of the normal regression of this valve can lead to subdivision of the right atrium into two chambers, varying from partial partition by the presence of a prominent eustachian valve to complete right atrial division.<sup>1,2</sup> Cor triatriatum dextrum can occur as an isolated anomaly or can be associated with other complex right-sided cardiac defects, such as abnormalities of the tricuspid valve, atresia or pulmonary artery stenosis, and Ebstein's anomaly. Moreover, cor triatriatum dexter has varying clinical manifestations, depending on the degree of flow obstruction produced by the fibromuscular membrane, which is usually fenestrated. When the partition is incomplete, it can be asymptomatic and might be detected incidentally by echocardiographic examination or other imaging diagnostic test.<sup>3</sup>

In our case, the right atrium was divided into two components by a persisting right sinus valve, leading the blood flow from the inferior vena cava to the posterior component, while the superior vena cava drained to the distal component.



**Figure 1** Preprocedural imaging for documentation of cor triatriatum dexter (1A). TEE-guided transeptal puncture followed by pulmonary vein cryoablation (1B).

To the best of our knowledge, this is the first case report describing the feasibility of left atrial access and cryoablation in cor triatriatum dextrum.

**Conflict of interest:** none declared.

## References

1. Bharucha T, Spicer DE, Mohun TJ, Black D, Henry GW, Anderson RH. Cor triatriatum or divided atriums: which approach provides the better understanding? *Cardiol Young* 2015;**25**:193–207.
2. Moral S, Ballesteros E, Huguet M, Panaro A, Palet J, Evangelista A. Differential diagnosis and clinical implications of remnants of the right valve of the sinus venosus. *J Am Soc Echocardiogr* 2016;**29**:183–94.
3. Trakhtenbroit A, Majid P, Rokey R. Cor triatriatum dexter: antemortem diagnosis in an adult by cross sectional echocardiography. *Br Heart J* 1990;**63**:314–6.