

EP CASE REPORT

Left subclavian approach for ablation of persistent left superior vena cava in a patient with cardiac resynchronization therapy: a case report

Kazuto Hayasaka¹, Akira Mizukami^{1*}, Shunsuke Kuroda¹, Tatsuya Hayashi¹, Akihiko Matsumura¹, and Kenzo Hirao²

¹Department of Cardiology, Kameda Medical Center, 929 Higashicho, Kamogawa, Chiba 296-8602, Japan; and ²Department of Cardiovascular Medicine, Tokyo Medical and Dental University, 1-5-45 Yushima, Bunkyo, Tokyo 113-8510, Japan

* Corresponding author. Tel: +81 4 7092 2211; fax: +81 4 7099 1198. E-mail address: akmizukami@gmail.com

Introduction

Persistent left superior vena cava (PLSVC) is a potential arrhythmogenic source of atrial fibrillation (AF).¹ However, in patients with cardiac resynchronization therapy (CRT), PLSVC ablation through the coronary sinus (CS) risks left ventricular (LV) lead dislodgement.

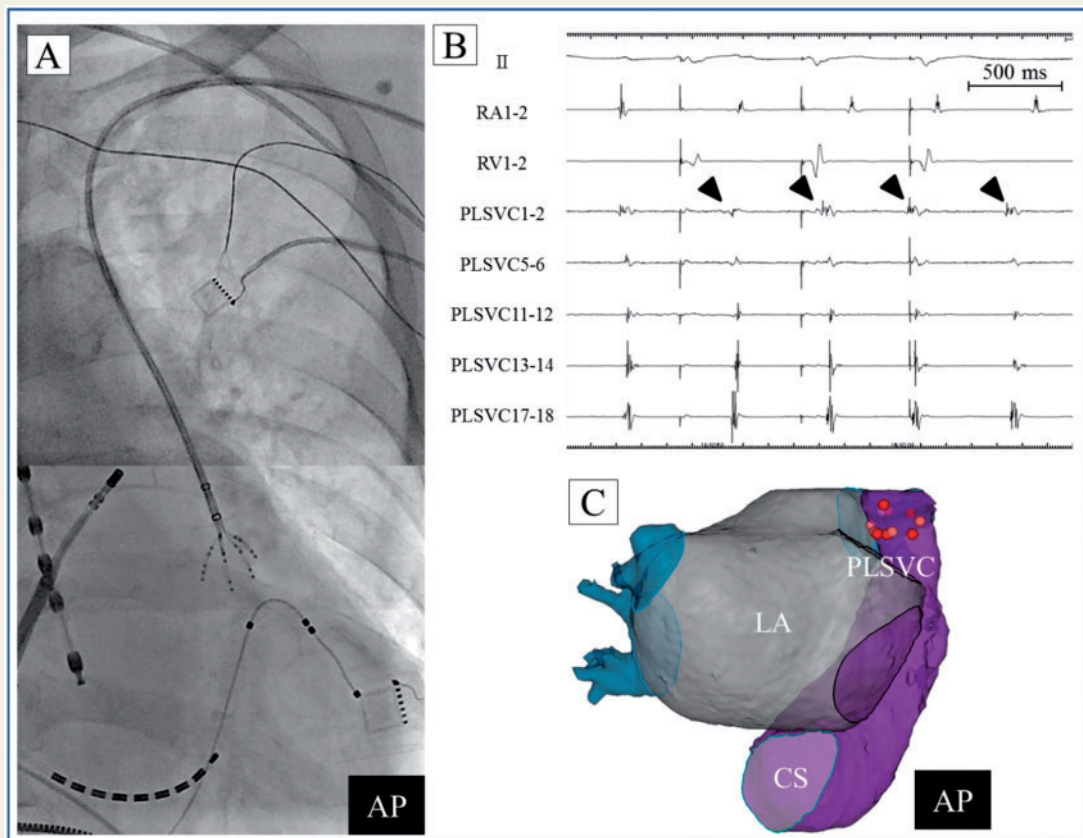


Figure 1 (A) PentaRay (Biosense Webster) was placed at the distal portion of the left ventricular lead in the PLSVC through the left subclavian vein. The ablation catheter in the left superior pulmonary vein, oesophageal temperature probe (SensiTherm, Abbott), and mapping catheter in RA with its tip at the CS ostium (BeeAT, Japan LifeLine) are also observed. (B) PentaRay (Biosense Webster) demonstrated APC potentials preceding potentials in the RA (arrow head). (C) Distal PLSVC isolation was completed via relatively simple ablation catheter handling. AP, anterior posterior; APC, atrial premature contraction; CS, coronary sinus; LA, left atrium; ms, milliseconds; PLSVC, persistent left superior vena cava; RA, right atrium; RV, right ventricle.

Case report

An 81-year-old man with dilated cardiomyopathy and heart failure was referred to our hospital for persistent AF ablation. Due to the presence of PLSVC, a right-sided implantable cardioverter-defibrillator had been implanted, which was upgraded to CRT with a defibrillator with an additional LV lead from the same side to manage heart failure. However, AF development exacerbated heart failure, resulting in catecholamine dependence and necessitating catheter ablation. Electrocardiogram revealed AF with a biventricular pacing rhythm, and echocardiography demonstrated diffuse hypokinesia with an LV ejection fraction of 20%. Computed tomography showed PLSVC connecting the left subclavian vein (LSCV) to the CS.

Catheter ablation for AF was performed with the CARTO 3 system (Biosense Webster). After pulmonary vein isolation, PLSVC arrhythmogenicity was assessed with isoproterenol infusion. Approaching the PLSVC through the CS risked interference with the LV lead; therefore, we approached through the LSCV. A PentaRay (Biosense Webster) was inserted into the PLSVC through the LSCV. Even though there was no induction of AF, frequent premature contractions originating from the PLSVC was documented (*Figure 1A and B*). To minimize the risk of AF recurrence, PLSVC ablation was cautiously performed preserving the left phrenic nerve using ThermoCool SmartTouch (Biosense Webster) catheter, which was exchanged with the PentaRay catheter through the same access. We succeeded in distal PLSVC isolation without LV lead dislodgement (*Figure 1C*). After the procedure, congestive heart failure and catecholamine dependence resolved; moreover, the patient was free from AF recurrence and heart failure hospitalization for the follow-up period of 1 year.

Discussion

We showed that distal PLSVC isolation can be completed safely using an approach through the LSCV in patients with CRT. To the best of our knowledge, this is the first case report of an effective approach to PLSVC ablation in a patient with CRT.

Persistent left superior vena cava is known to be an arrhythmogenic source of AF; ablation of PLSVC has been reported to be effective in such patients.² However, PLSVC isolation necessitated ablation from CS.² Approaching through CS may interfere with the LV lead in patients with CRT. Left ventricular lead dislodgement requiring reoperation has been reported even in the long-term.³ In our case, distal PLSVC isolation was completed safely through the LSCV. Moreover, this approach can be effective in all patients who need PLSVC isolation because of its simplicity in catheter handling.

In conclusion, we present an effective approach to distal PLSVC isolation. This approach is a feasible option for PLSVC isolation.

Conflict of interest: none declared.

References

1. Liu H, Lim KT, Murray C, Weerasooriya R. Electrogram-guided isolation of the left superior vena cava for treatment of atrial fibrillation. *Europace* 2007;**9**:775–80.
2. Elayi CS, Fahmy TS, Wazni OM, Patel D, Saliba W, Natale A. Left superior vena cava isolation in patients undergoing pulmonary vein antrum isolation: impact on atrial fibrillation recurrence. *Heart Rhythm* 2006;**3**:1019–23.
3. Forieo GB, Mantica M, Di Biase L, Panattoni G, Della Rocca DG, Paravasileiou LP et al. Clinical and procedural outcome of patients implanted with a quadripolar left ventricular lead: early results of a prospective multicenter study. *Heart Rhythm* 2012;**9**:1822–8.