

## EP CASE REPORT

# Smartphone electrocardiograms reveal painful left bundle branch block syndrome and illustrate associated electrophysiological phenomena

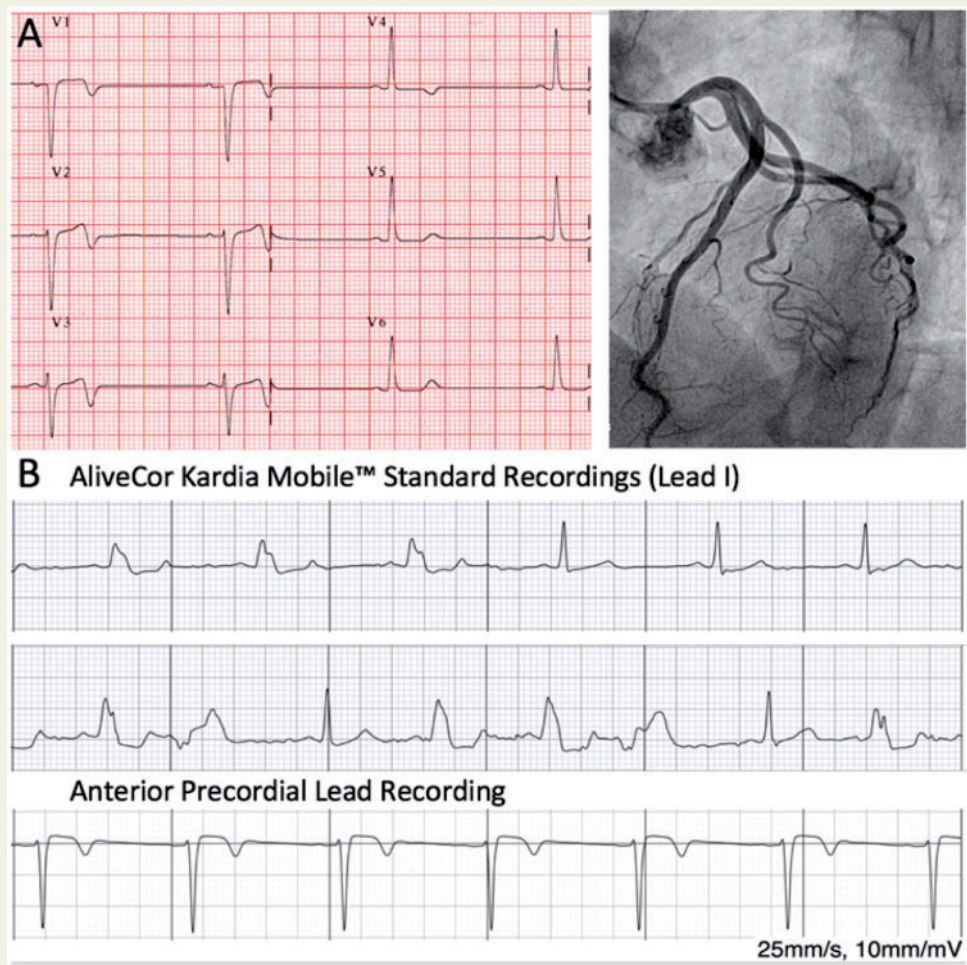
Javier García-Niebla<sup>1</sup>, Derek Crinion <sup>2</sup>, Gilmar Gutierrez<sup>2</sup>, Sanoj Chacko<sup>2</sup>, Juan Lacalzada-Almeida <sup>3</sup>, and Adrian Baranchuk <sup>2\*</sup>

<sup>1</sup>Servicios Sanitarios del Área de Salud de El Hierro, Valle del Golfo Health Center, El Hierro, Spain; <sup>2</sup>Arrhythmia Service, Kingston General Hospital, Queen's University, Kingston, ON K7L 2V7, Canada; and <sup>3</sup>Department of Cardiology, Hospital Universitario de Canarias, Tenerife, Spain

\* Corresponding author. Tel: 613 549 6666; Fax: 613 548 1387. E-mail address: Adrian.Baranchuk@kingstonhsc.ca

A 69-year-old Caucasian lady was referred for assessment of exertional chest pain (Canadian Cardiovascular Society Angina Grade II), on a background history of dyslipidaemia. Anteroseptal T wave inversion (TWI) (V1–V4) was evident (Figure 1A, left), which raised the suspicion of Wellens' syndrome. However, cardiac catheterization demonstrated widely patent coronary arteries, with no evidence of myocardial bridging or anomalous anatomy (Figure 1A, right). An echocardiogram indicated normal structure and function. On follow-up, her chest discomfort persisted and she purchased a smartphone-based electrocardiogram (ECG) recorder (AliveCor Kardia Mobile™, USA).

The smartphone EGMs revealed that her chest pain coincided with the sudden onset and resolution of left bundle branch block (LBBB) (Figure 1B, top). 'Painful LBBB syndrome' is an increasingly recognized clinical entity,<sup>1</sup> that can easily be missed following a reassuring ischaemic evaluation. The exact mechanism is debated but LBBB, particularly when accompanied by an inferior axis, induces a pattern of abnormal ventricular activation that induces pain in individuals with heightened interoceptive awareness.<sup>1</sup> The prognosis is generally favourable, although a high proportion develops



**Figure 1** (A, left) ECG precordial leads showing anteroseptal TWI, (A, right) angiogram showing normal coronary arteries. (B, top and bottom) depicting Smartphone EGMs (see text). EGM, smartphone-based electrocardiograms; TWI, T-wave inversion.

permanent LBBB, which can paradoxically improve symptoms.<sup>1</sup> Treatment strategies have reported variable success and include exercise regimes, beta-blockade, and pacemaker implantation.<sup>1</sup>

In addition to revealing the diagnosis, the KardiaMobile™ single lead recordings illustrate associated electrophysiological phenomena. The onset and resolution of the BBB are rate related (*Figure 1B*, top EGM), suggesting a phase 3 (relative refractory period) block.<sup>2</sup> The 'critical rate' is dependent on the preceding change in cycle length: the faster the acceleration the lower the critical heart rate, and vice versa.<sup>2</sup> In addition, LBBB resolves at a lower rate than that of onset (*Figure 1B*, top EGM).<sup>2</sup> This is due to 'linking phenomenon' whereby concealed retrograde invasion of the bundle occurs from the contralateral side, thereby rendering it refractory to antegrade activation.<sup>2</sup> Premature ventricular contractions (PVCs) repeatedly caused the LBBB to transiently resolve (*Figure 1B*, middle EGM). This observation is consistent with aforementioned explanations for 'functional' block, as the PVC provided the LBB sufficient time to recover.<sup>2</sup> Anteroseptal TWI on the 12-lead ECG can also be demonstrated on the KardiaMobile™ by recording an anterior precordial lead (the device is placed on the lower left side of the chest, below the pectoral muscle, with the bottom of the smartphone pointing towards the centre of the body) (*Figure 1B*, bottom EGM). The TWI was interpreted as a harbinger of ischaemia, but it was in fact a result of 'cardiac memory'.<sup>3</sup> Rosenbaum *et al.*<sup>3</sup> was the first to use this term to describe the transient TWI that occurs after a period of abnormal ventricular activation. The TWI in sinus rhythm follows (remembers) that of the QRS during abnormal activation, occurs more quickly following repeated episodes (memory), with greater amplitude and persistence (accumulation).<sup>3</sup> Causes include intermittent BBB, pacing (Chatterjee phenomenon), pre-excitation, and ventricular tachycardia.<sup>3</sup> In summary, this case demonstrates the increasing contribution of smartphone-based EGMs. Furthermore, despite the limited lead recordings, complex electrophysiological phenomena can be appreciated.

**Conflict of interest:** none declared.

## References

1. Shvilkin A, Ellis ER, Gervino EV, Litvak AD, Buxton AE, Josephson ME. Painful left bundle branch block syndrome: clinical and electrocardiographic features and further directions for evaluation and treatment. *Heart Rhythm* 2016;**13**:226–32.
2. Bazoukis G, Tsimos K, Korantzopoulos P. Episodic left bundle branch block: a comprehensive review of the literature. *Ann Noninvasive Electrocardiol* 2016;**21**:117–25.
3. Rosenbaum MB, Blanco HH, Elizari MV, Lázzari JO, Davidenko JM. Electronic modulation of the T wave and cardiac memory. *Am J Cardiol* 1982;**50**:213–22.