

EP CASE REPORT

Leadless pacemaker implantation via azygos vein in a patient with absence of the hepatic segment of the inferior vena cava

Mário Oliveira*, Dinis Mesquita, Pedro S. Cunha, Ana S. Delgado, and Rui C. Ferreira

Arrhythmology Unit, Santa Marta Hospital, Rua Santa Marta, 1169-024, Lisbon, Portugal

* Corresponding author. Tel: 351 213594311; fax: 351 213531983. E-mail address: m.martinsoliveira@gmail.com

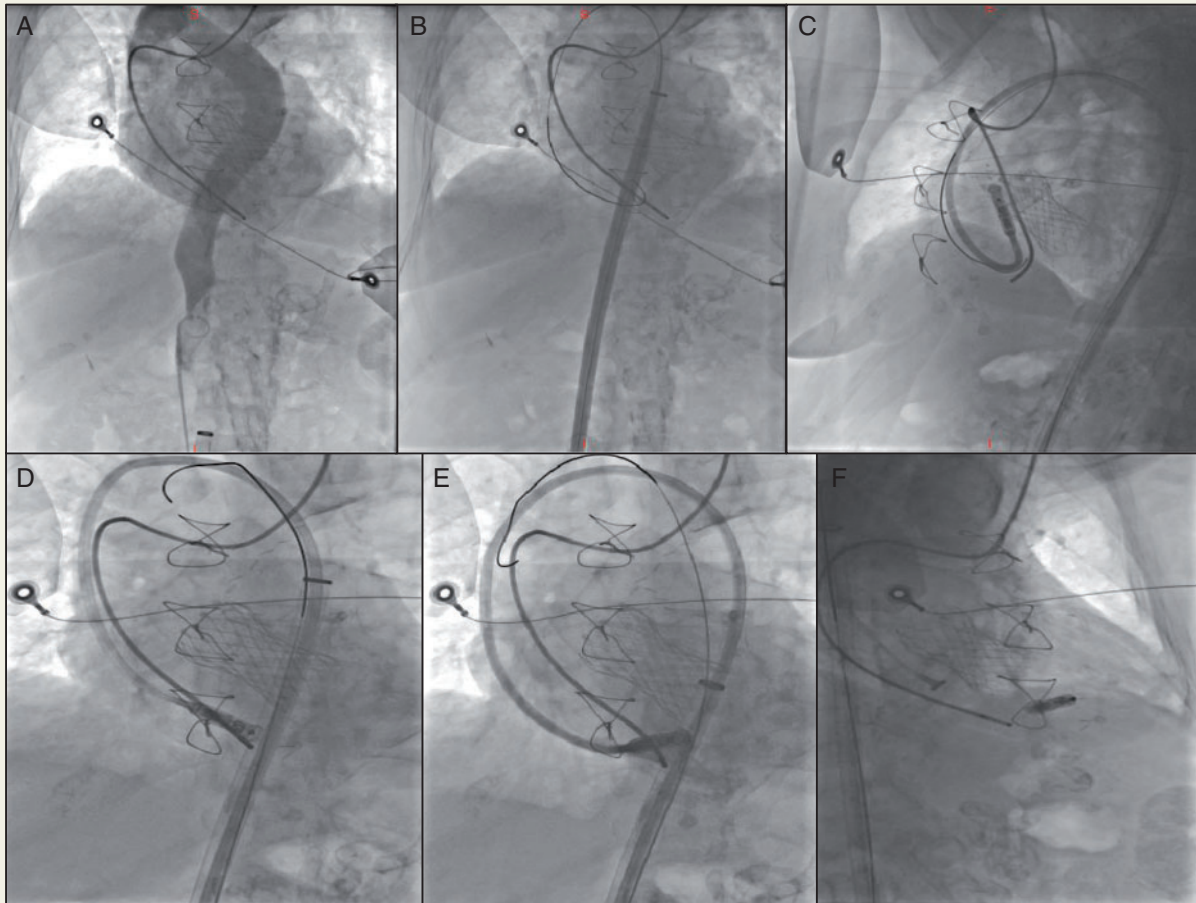


Figure 1 (A) Angiogram showing an enlarged azygos vein with continuation to superior vena cava (anteroposterior view). (B) Guidewire passing from the azygos vein through superior vena cava, right atrium, and right ventricle, with the 27-Fr sheath and dilator failing to track across the curve (anteroposterior view). The transcatheter aortic valve, wires of sternotomy closure, and the temporary pacing wire (inserted via left jugular vein) are also shown. (C) Leadless pacemaker delivery catheter deflected and advanced to the right ventricle maintaining the extra stiff guidewire (left anterior oblique view). (D) Leadless pacemaker delivery catheter passing through the tricuspid valve (anteroposterior view). The transcatheter aortic valve, wires of sternotomy closure, and the temporary pacing wire (inserted via left jugular vein) are also shown. (E) Leadless pacemaker delivery catheter advanced to the right ventricle in an apical-septum position (left anterior oblique view). (F) Final position of the Micra leadless pacemaker (right anterior oblique view). The transcatheter aortic valve, wires of sternotomy closure, and the temporary pacing wire (inserted via left jugular vein) are also shown.

Case report

An 82-year-old woman with atrial fibrillation and chronic renal failure underwent a transcatheter aortic valve implantation and percutaneous coronary intervention of left anterior descending artery. She had *de novo* left bundle branch block, without bradyarrhythmia and was discharged. Due to asystole during a dialysis session, a temporary transvenous pacing was placed via left internal jugular vein (unsuccessful progression through right internal jugular vein), and she was referred to urgent pacemaker implantation due to asystole and intermittent failure of capture. Since the patient was in haemodialysis using arteriovenous fistulae on either arm, the decision was to implant the Micra transcatheter leadless pacemaker (LPM) (Medtronic Inc., Minneapolis, MN, USA). Because the readmission occurred via the emergency care department, the operator was not aware of the azygos continuation of the inferior vena cava showed in a previous contrast enhanced computed tomography. A large and tortuous azygos vein draining to the superior vena cava was, therefore, detected during the implant. A stiff support wire inserted via the right femoral vein showed a tortuous course and inability to advance through the inferior vena cava. A cine-angiogram documented an enlarged azygos vein with a very tortuous path draining to the superior vena cava (Figure 1A). An extra stiff guidewire was used, but the 27-Fr sheath and dilator failed to track across (Figure 1B). With gentle but sustained pushing and pulling on the extra stiff guidewire, combined with transient withdraw of the temporary pacing, allowed final advancement of the sheath to the right ventricle (RV) (Figure 1C, D). The final position was on the apical septum (Figure 1E, F). The pacing threshold was 0.5 V (at 1 ms), the R-wave amplitude was 10.7, and the pacing impedance was 680 Ω . No procedural complications occurred. On discharge, and when seen at 1 month, the device, in VVIR mode at 80 b.p.m., had stable parameters, with 34.7% and 79.3% of right ventricular pacing, respectively, and no oversensing or undersensing.

Discussion

LPM provides an alternative to transvenous pacemakers, particularly useful in patients with increased risk of infection or lack of venous access to the heart. It requires large and stiff delivery sheaths that may compromise the procedure in the presence of complex or difficult venous anatomies. We report a case of a successful LPM implantation through an enlarged azygos vein with a very tortuous path. The venous passage of the delivery sheath into the RV was achieved after difficult manoeuvres using a stiff support wire, with a push and pull technique. With careful positioning and contrast injections the Micra capsule could be safely implanted without complications.

This case report demonstrates that LPM may be used in the presence of abnormal venous anatomies. Difficult iliac venous access caused by an external endovascular abdominal aortic stent, and abnormal venous anatomy in a complex congenital heart disease have been previously described in LPM implantation.^{2,3} This is the first report of a successful LPM in a patient with an enlarged and tortuous azygos vein. We believe that this may contribute to the use of this technique in patients with difficult and limited vein anatomy who require pacemaker implantation.

Conflict of interest: none declared.

References

1. Reddy VY, Exner DV, Cantillon DJ, Doshi R, Bunch TJ, Tomassoni GF et al. Percutaneous implantation of an entirely intracardiac leadless pacemaker. *N Engl J Med* 2015;**373**:1125–35.
2. Ferrero P, Yeong M, D'Elia E, Duncan E, Graham Stuart A. Leadless pacemaker implantation in a patient with complex congenital heart disease and limited vascular access. *Indian Pacing Electrophysiol J* 2016;**16**:201–4.
3. Mohananey D, Jobanputra Y, Kumar A, Krishnaswamy A, Mick S, White JM et al. Clinical and echocardiographic outcomes following permanent pacemaker implantation after transcatheter aortic valve replacement: meta-analysis and meta-regression. *Circ Cardiovasc Interv* 2017;**10**:e005046.