

EP CASE REPORT

Hybrid cardiac resynchronization with leadless pacemaker and transvenous coronary sinus lead

Sit-Yee Kwok¹ and Hung-Fat Tse^{2*}

¹Department of Paediatric Cardiology, Queen Mary Hospital, University of Hong Kong, Hong Kong, China; and ²Cardiology Division, Department of Medicine, University of Hong Kong, Queen Mary Hospital, Room 1928, Block K, Hong Kong, China

* Corresponding author. Tel: +852 2255 4694; fax: +852 28186304. E-mail address: hftse@hkucc.hku.hk

We describe the novel use of leadless pacemaker to replace a malfunctioning right ventricular (RV) lead in a 74-year-old woman implanted with cardiac resynchronization therapy pacemaker (CRT-P) system (Medtronic Consulta CRT-P C3TR01). Her CRT-P was implanted for atrial fibrillation, complete heart block and RV pacing induced heart failure. She presented with worsening of dyspnoea due to progressive RV lead failure (increased threshold to 3 V/0.4 ms; and decreased impedance to 171 ohm) with loss of cardiac resynchronization therapy. Echocardiogram showed impaired left ventricular (LV) ejection fraction of 40% with dilated right ventricle and severe tricuspid regurgitation (TR). With anticipatory difficulty in replacing a new transvenous RV lead due to multiple transvenous leads, and potential worsening of TR, a Micra™ transcatheter pacemaker system (Medtronic) was implanted. The device was deployed on the RV septum away from the old RV lead, as shown in the *Figure 1*. The output of transvenous RV lead was kept to be minimal. With intact sensing function of the transvenous RV lead (sensed R wave = 4.3 mV), ventricular sense response (VSR) feature of Medtronic CRT-P device allowed simultaneous LV pacing once the system sensed the RV Micra™ pacing. The QRS duration was 140 ms on Micra™ pacing (see *Supplementary material online, Figure S1*) and was shortened to 110 ms on biventricular pacing (see *Supplementary material online, Figure S2*). At 3-month post-implantation, the performance of the hybrid biventricular pacing system was satisfactory.

Leadless pacing system has marked a revolutionary change in cardiac pacing. The large scale Micra™ post-approval registry demonstrated a high implant success rate of 99.6% and low (1.51%) major complication rate through 30-days post-implantation. Compromised venous access, risk of infection, or valvular issues as shown in our case are reasons to avoid the use of a transvenous pacing system.¹ In this reported case, one may argue the *in situ* transvenous RV lead could be the culprit of TR. The conventional approach of lead extraction and replacement may result in less severe TR. On the other hand, the extraction procedure may also damage the tricuspid valve, necessitating surgical repair. Due to the old age of the woman, our novel approach using leadless pacing was offered as a less invasive approach. Currently,

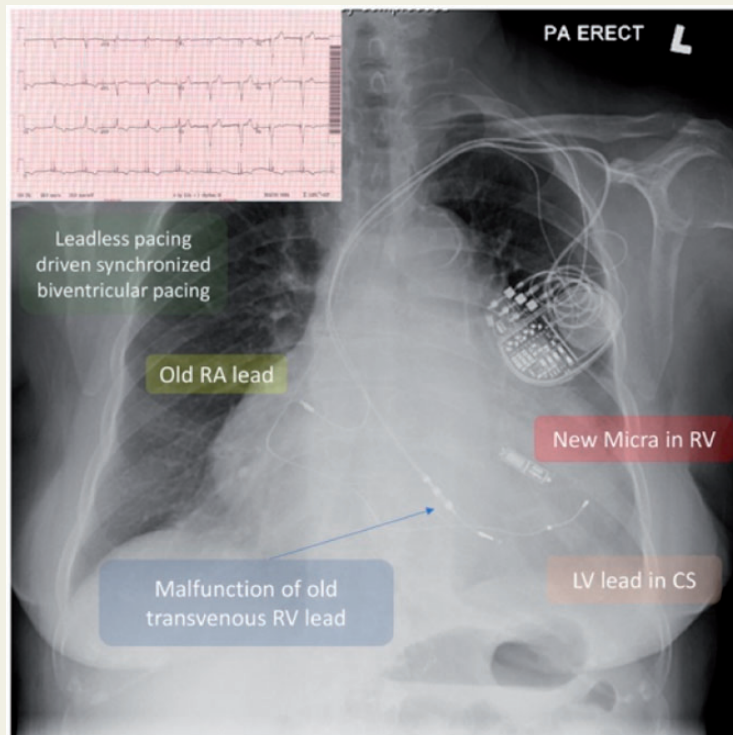


Figure 1 Micra™ was implanted over right ventricular septum, on top of existing CRT-P system. Triggered biventricular pacing could be performed using ‘Ventricular Sensed Response’ function of CRT-P.

leadless pacing is advocated mainly in patients with VVI pacing indication. To expand the benefits of leadless pacing, efforts are being made to develop multicomponent, communicating leadless systems capable of performing dual chamber pacing and cardiac resynchronization therapy.² Herein, we describe the use of leadless pacemaker to replace a malfunctioning RV lead in a CRT-P system. Utilization of VSR feature of the CRT-P device, we achieved a triggered biventricular pacing using the leadless pacemaker and transvenous LV lead. To our knowledge, this hybrid approach has not been reported.

Supplementary material is available at *Europace* online.

Conflict of interest: none declared.

References

1. Roberts PR, Clementy N, Al Samadi F, Garweg C, Martinez-Sande JL, Iacopino S *et al*. A leadless pacemaker in the real-world setting: the micra transcatheter pacing system post-approval registry. *Heart Rhythm* 2017;**14**:1375–9.
2. Tjong FV, Reddy VY. Permanent leadless cardiac pacemaker therapy: a comprehensive review. *Circulation* 2017;**135**:1458–70.