

EP CASE REPORT

Critical isthmus of Fallot ventricular tachycardia easily identified by linear multipolar diagnostic catheter

Filippo Maria Cauti*, Pietro Rossi, Luigi Iaia, and Stefano Bianchi

Arrhythmology Unit, Ospedale S. Giovanni Calibita, Fatebenefratelli Isola Tiberina, Rome, Italy

* Corresponding author. Tel: 0039 06 6837348. E-mail address: filippocauti@hotmail.it

A 41-year-old man with tetralogy of Fallot, was surgically corrected at the age of three with the standard radical technique that includes patch of the perimembranous ventricular septal defect (VSD), longitudinal resection of the hypertrophic infundibulum, and subsequent insertion of a right ventricular outflow tract (RVOT) patch to augment the restrictive RVOT (transannular RVOT patch).

Afterwards the patient suffered recurrent episodes of ventricular tachycardia (VT) leading to a dual chamber implantable cardioverter-defibrillator.

Due to VT recurrences the patient was referred to our department for catheter radiofrequency ablation.

As our institutional protocol Amiodarone was stopped 1 month before the EP procedure.

Previous studies elegantly¹⁻³ have shown anatomical and functional isthmus of repaired Fallot patients across the surgically sutured Dacron patches.

The electroanatomical map of the right ventricle (EnSite Precision, Abbott) was performed by the use of a linear multipolar catheter (Livewire Duodecapolar 2-2-2, Abbott), a steerable ablation catheter (FlexAbility F curve, Abbott), and a steerable sheath (Agilis L NxT Abbott), to improve stability of the catheters during the procedure. Once substrate mapping was performed (identifying LPs area, scar zones), programmed ventricular stimulation induced the clinical VT (haemodynamic tolerated left bundle branch block morphology with inferior frontal axis, CL 375 ms). Ventricular tachycardia activation mapping using a linear high-density mapping catheter was thus performed to confirm the slow conduction isthmuses.

The VT circuit isthmus was clearly identified in only two cycles of the tachycardia by the Livewire catheter while located in a posterolateral position to the Dacron VSD patch (anatomical isthmus between the VSD patch and the pulmonary valve).

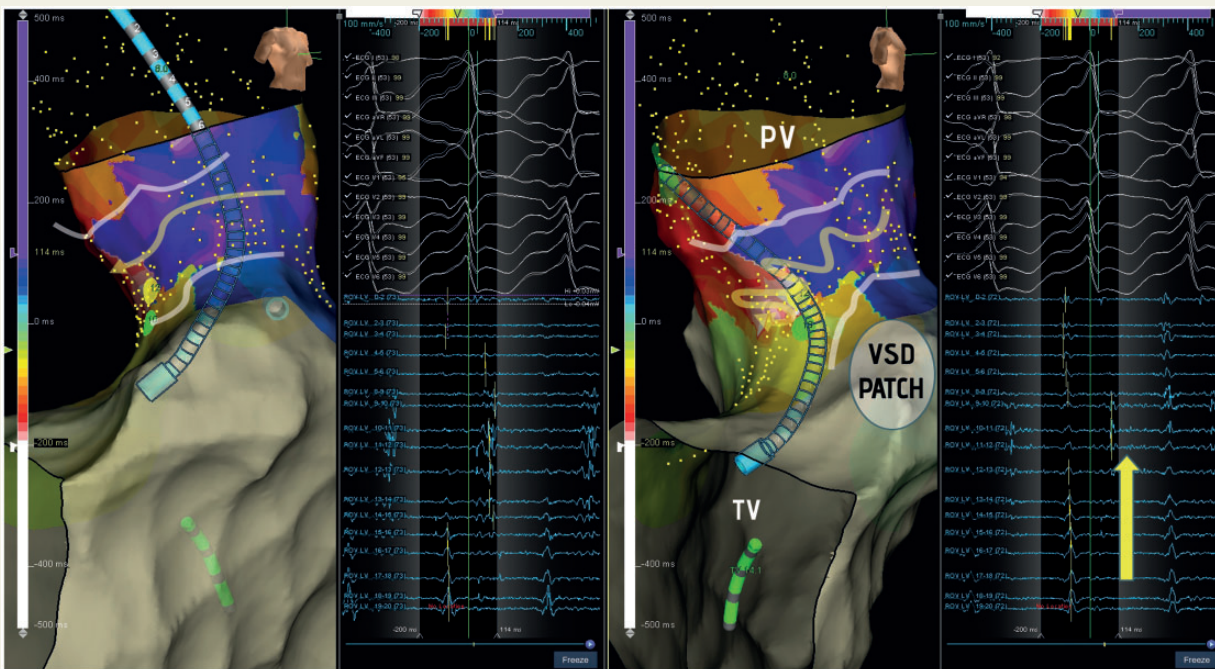


Figure 1 Critical VT Isthmus. Yellow Arrow indicate the mid diastolic activation of the circuit.

The high-density VT activation map, facilitated by using the Livewire catheter, allowed termination of the clinical tachycardia by applying one single radiofrequency delivery (35 W, 43°C). Endpoints in this particular setting were: termination of the clinical VT (radiofrequency delivery on mid diastolic potential during VT), complete abolition of late potentials in sinus rhythm, non-inducibility of all the VT induced with aggressive protocol (four extrastimuli).

The image in the panel reports the operative utility of the high density mapping to discriminate the precise critical VT isthmus implicated in the VT re-entry in operated Fallot patients.

Nowadays, linear multipolar catheter in high-density mapping could be used in order to visualize in real time the VT isthmus pathways.

Additional prospective studies are required to prove the utility and efficacy of this multipolar catheter based approach.

Supplementary material is available at *Europace* online.

Conflict of interest: none declared.

References

1. Zeppenfeld K, Wijnmaalen AP. Clinical aspects and ablation of ventricular arrhythmias in tetralogy of Fallot. *Card Electrophysiol Clin* 2017;**9**:285–94.
2. Zeppenfeld K, Schalij MJ, Bartelings MM, Tedrow UB, Koplan BA, Soejima K et al. Catheter ablation of ventricular tachycardia after repair of congenital heart disease: electro-anatomic identification of the critical right ventricular isthmus. *Circulation* 2007;**116**:2241–52.
3. Kapel GF, Sacher F, Dekkers OM, Watanabe M, Blom NA, Thambo JB et al. Arrhythmogenic anatomical isthmuses identified by electroanatomical mapping are the substrate for ventricular tachycardia in repaired tetralogy of Fallot. *Eur Heart J* 2017;**38**:268–76.