

EP CASE REPORT

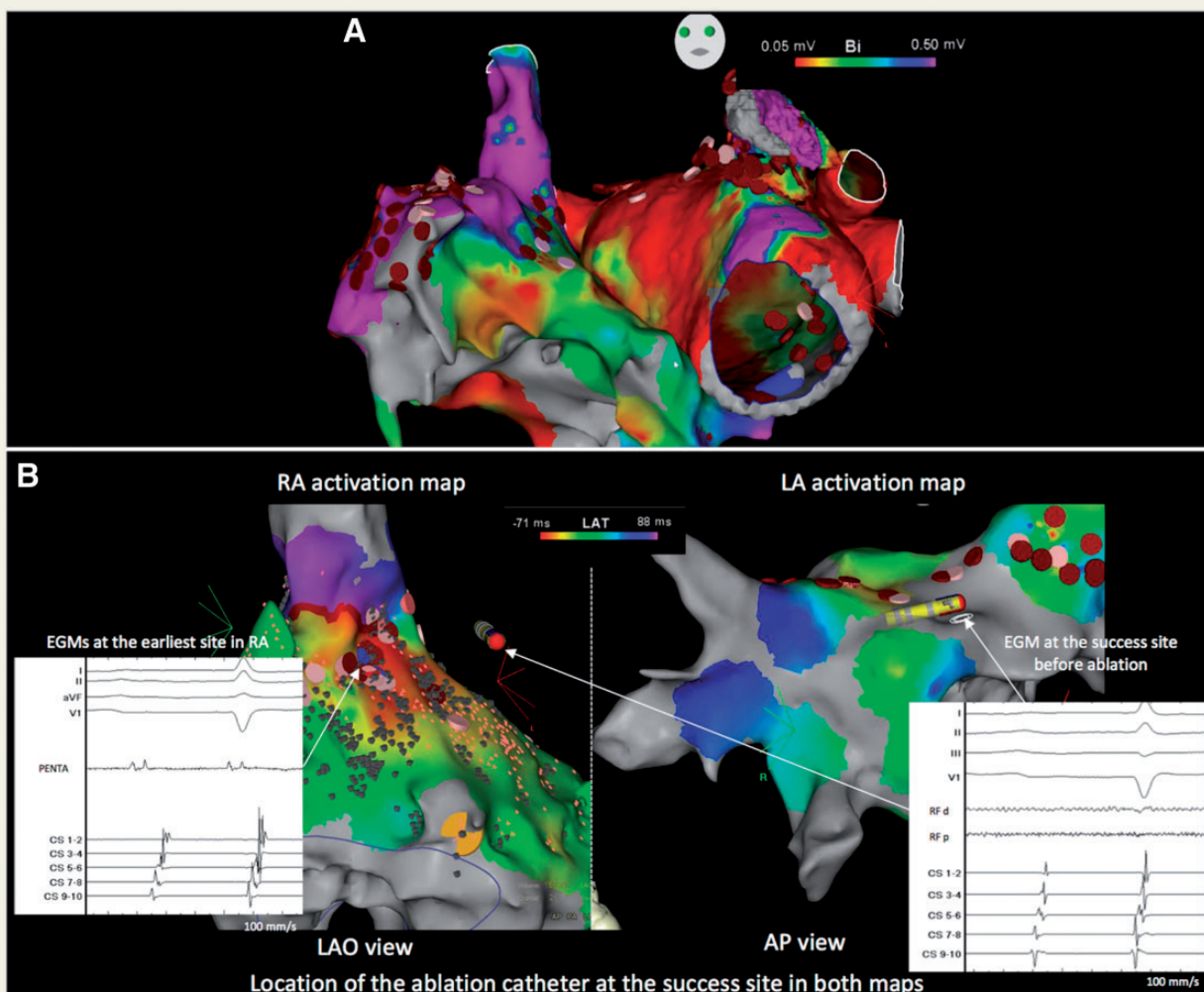
Atrial tachycardia originating from deep septum following catheter ablation for persistent atrial fibrillation

Takeshi Kitamura*, Ruairidh Martin, Antonio Frontera, and Pierre Jais

Service de Rythmologie, Hôpital Cardiologique du Haut-Lévêque, Centre Hospitalier Universitaire de Bordeaux, Avenue de Magellan, 33604 Bordeaux-Pessac, France

* Corresponding author. Tel: + 33 5 57 65 65 65; fax: + 33 5 57 65 64 19. E-mail address: take1124@hotmail.co.jp

A 46-year-old man, who had undergone catheter ablation (CA) for persistent atrial fibrillation (AF), presented with recurrence of AF and was referred for CA. The index ablation lesions included pulmonary vein isolation, roof line, mitral isthmus, and cavotricuspid isthmus, and extensive defragmentation of the anterior left atrium (LA), LA septum (LAS), and right atrial septum (RAS). A voltage map during AF demonstrated extensive low voltage areas, with particularly low voltage on the LAS (Figure 1A). Ablation was based on the local AF cycle length (CL) and non-invasive electrocardiographic imaging. After ablation, AF was terminated by cardioversion. Following this ablation session, he had a recurrence with an atrial tachycardia (AT) with CL of 344 ms. A redo procedure was performed 6 months after the index procedure. Mapping demonstrated a centrifugal pattern with the earliest activation on the RAS. However, this earliest activity was clearly from a far-field electrogram (EGM) (Figure 1B). The LA activation map revealed no obvious EGMs at LAS, even opposite the earliest site in RAS (Figure 1B). We couldn't entrain from the ablation site as no consistent capture could be achieved. Activation maps of both atria showed a



centrifugal pattern and did not complete the entire CL of the AT so that the AT was likely to have a non-reentrant focal mechanism. We delivered a radiofrequency (RF) application at the LAS on the opposite side of the earliest site in right atrium (RA), because we speculated that the origin was located deeply in the interatrial septum. This RF application restored sinus rhythm with AT termination in 65 s following CL prolongation. No recurrences were observed during a 5-month follow-up.

Atrial tachycardia originating from interatrial septum without a history of AF ablation has been well described.¹ On the other hand, focal AT originating from LAS makes up only 1.2% of AT after AF ablation.² Interestingly, we could not identify the earliest signal as near-field EGMs on either side of the septum, particularly the LAS where there were no potentials left. Commonly, one or other septum demonstrates the earliest potential in this type of AT.¹ The lack of clear near-field EGMs on either septum and the duration of RF application required for AT termination, indicate that the origin of the AT was likely to be located in deeper septum, possibly between the RA and LA surface musculature layers. Regarding anatomical aspects, detailed anatomical studies have shown the higher septum forms a deep infolded atrial wall as the septum secundum.^{2,3} Therefore, the present case shows AT originating from the deeper high septum may occur without any obvious near-field EGMs recordable after extensive AF ablation and may require long RF application to achieve deep enough lesion.

References

1. Kaneko Y, Kato R, Nakahara S, Tobiume T, Morishima I, Tanaka K *et al.* Characteristics and catheter ablation of focal atrial tachycardia originating from the interatrial septum. *Heart Lung Circ* 2015;**24**:988–95.
2. Chae S, Oral H, Good E, Dey S, Wimmer A, Crawford T *et al.* Atrial tachycardia after circumferential pulmonary vein ablation of atrial fibrillation. *J Am Coll Cardiol* 2007;**50**:1781–7.
3. Anderson RH, Brown NA. The anatomy of the heart revisited. *Anat Rec* 1996;**246**:1–7.