

EP CASE REPORT

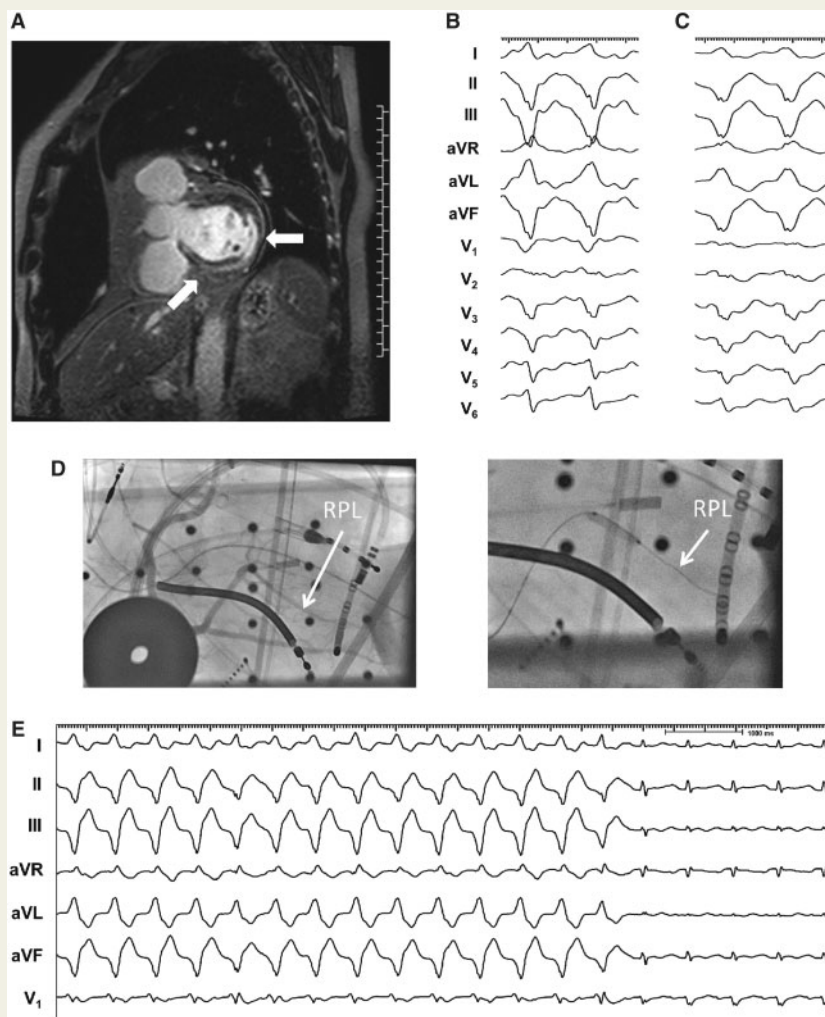
Treatment of intramural ventricular tachycardia in cardiac sarcoidosis with transcatheter ethanol ablation

Steven M. Markowitz*, Robert M. Minutello, Luke K. Kim, James E. Ip, George Thomas, and Bruce B. Lerman

From the Division of Cardiology, Department of Medicine, Starr 4, Weill Cornell Medical College, Cornell University Medical Center, 525 East 68th Street, New York, NY, 10065, USA

* Corresponding author. Tel: 212-746-2158; fax: 212-746-6951. E-mail address: smarkow@med.cornell.edu

The patient is a 67-year-old man who had recurrent ventricular tachycardia (VT) despite treatment with amiodarone. Cardiac magnetic resonance imaging (MRI) demonstrated delayed enhancement of the mid-myocardium in the basal inferolateral wall and septum (Figure, Panel A). Cardiac Positron emission tomography–computed tomography (PET–CT) showed a perfusion defect with increased 18F-fluorodeoxyglucose uptake in the inferolateral wall, consistent with active myocardial inflammation. During electrophysiologic study, two different VT morphologies were induced, with left bundle branch block and right bundle branch block, left superior axes, respectively (Figure, Panels B and C). The VT cycle lengths were 330–400 ms. The earliest activation during VT (35 ms pre-QRS) and the best pace and entrainment maps were at the cardiac crux along the inferior interventricular septum near the posterior descending artery. The patient underwent four attempts at radiofrequency (RF) catheter ablation, including epicardial ablation, and bipolar transmural RF ablation.



Because of VT storm, another procedure was performed with transcatheter ethanol ablation. Angiography of the right coronary artery showed a posterolateral branch (RPL) that supplied this area on the epicardial surface (Figure, Panel D). Balloon occlusion of the distal RPL during VT was repeated three times, each resulting in VT termination within 3050 s (Figure, Panel E). Transcatheter ethanol ablation was performed with 1.2 mL injected twice in the RPL, after which the clinical VT became non-inducible. Peak troponin after this procedure was 9.4 ng/mL.

During a 2-year follow-up period, the patient had sporadic episodes of VT and underwent another procedure, during which VT was mapped to a more lateral location and treated with endocardial RF ablation. Subsequently, he had only one episode of VT treated with anti-tachycardia pacing.

This case illustrates a strategy for ablating refractory intramural VT from the posterior cardiac crux that did not respond to conventional unipolar or bipolar transmural ablation. Most cases of VT from the cardiac crux are idiopathic, but cases have been reported in patients with inferior myocardial infarction. In this case, crux VT arose in a patient with cardiac sarcoidosis. RF catheter ablation of VT in sarcoidosis can be challenging because of intramural location of arrhythmogenic tissue.¹ In addition, ablation of VT from the cardiac crux is often not successful, despite efforts to ablate from within the middle cardiac vein or on the epicardial surface.² Transcatheter ethanol ablation has been successfully employed for a variety of VT substrates that could not be treated successfully with endocardial or epicardial ablation.³ In our case, balloon inflation in the target vessel reproducibly terminated VT and identified this vessel as the appropriate target, and the clinical VT became non-inducible after ethanol ablation. We propose that this approach may be considered in patients with sarcoidosis who have intramural VTs that fail conventional ablation.

(A) Magnetic resonance imaging (MRI) shows delayed contrast enhancement of the inferior and lateral walls of the left ventricle and the mid septum (arrows). (B and C) 12-lead ECGs of VT from two different procedures showing both left bundle branch block and right bundle branch block patterns with a superior axis. (D) Fluoroscopic image shows anatomy of the distal right coronary artery with a posterolateral branch (RPL), which was targeted for ethanol ablation due to proximity to earliest epicardial electrograms during VT. Image on right shows balloon occlusion of this artery, during which VT reproducibly terminated (E).

References

1. Papageorgiou N, Providencia R, Bronis K, Dechering DG, Srinivasan N, Eckardt L et al. Catheter ablation for ventricular tachycardia in patients with cardiac sarcoidosis: a systematic review. *Europace* 2017. doi:10.1093/europace/eux077.
2. Kawamura M, Gerstenfeld EP, Vedantham V, Rodrigues DM, Burkhardt JD, Kobayashi Y et al. Idiopathic ventricular arrhythmia originating from the cardiac crux or inferior septum: epicardial idiopathic ventricular arrhythmia. *Circ Arrhythm Electrophysiol* 2014; **7**: 1152–8.
3. Tokuda M, Sobieszcyk P, Eisenhauer AC, Kojodjojo P, Inada K, Koplán BA et al. Transcatheter ethanol ablation for recurrent ventricular tachycardia after failed catheter ablation: an update. *Circ Arrhythm Electrophysiol* 2011; **4**: 889–96.