

EP CASE REPORT

Termination mode of a broad QRS complex tachycardia: is the surface electrocardiogram the key?

Labadet Carlos*, Hadid Claudio, Di Toro Dario, Celano Leonardo, Chavez Edgar Antezana, and Lopez Carlos

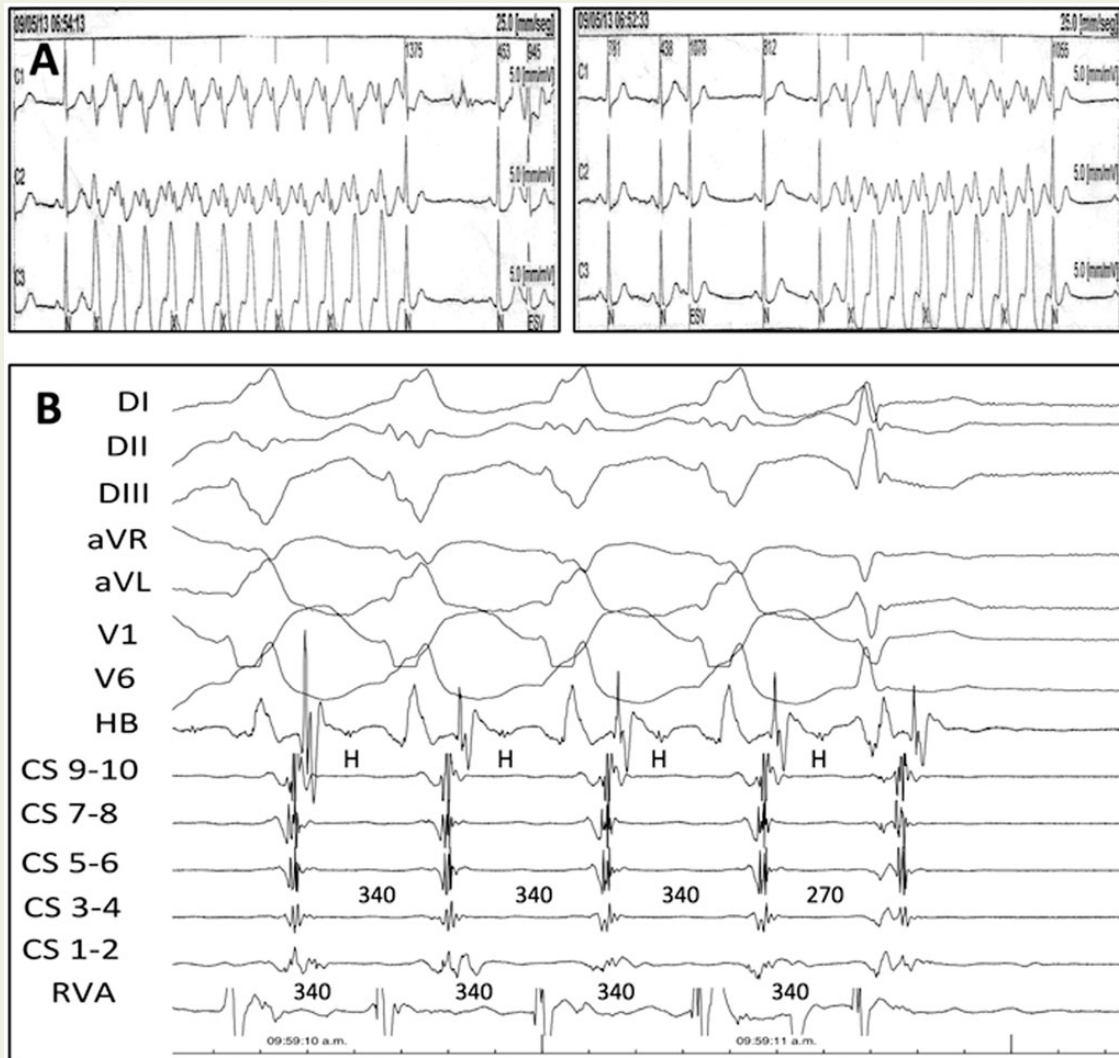
Electrophysiology Section, Cardiology Division, Hospital de la Ciudad de Buenos Aires, Dr Cosme Argerich, Pi y Margall 750. Ciudad de Buenos Aires 1157, Argentina

* Corresponding author. Tel: +541141210821; fax: +54114-300-3742. E-mail address: clabadet@gmail.com

Case presentation

A 45-year-old man with a long history of palpitations and absence of pre-excitation in baseline electrocardiogram underwent a Holter recording, revealing several episodes of regular non-sustained broad QRS complex tachycardia that terminated following the occurrence of a narrow QRS. (Panel A). The analysis of the last narrow QRS showed a signal compatible with a retrograde P wave. An electrophysiological study was performed.

During the procedure, short episodes of orthodromic tachycardia (OT) with functional left bundle branch block (LBBB) were reproduced and consistently interrupted following the occurrence of a single narrow QRS complex with exactly the same cycle length as that of the tachycardia (Panel B). The intracardiac recordings showed a 40 ms shortening of the ventriculo-atrial interval in the narrow beat and an-



terograde conduction block at the atrioventricular (AV) node level. The HV interval shortened 10 ms in the narrow QRS. A left free wall accessory pathway (AP) was successfully ablated.

Comment

Several electrocardiographic criteria have been proposed to distinguish between Orthodromic tachycardia and other forms of supraventricular tachycardia (SVT), especially AV nodal re-entrant tachycardia (AVNRT).^{1,2}

The interruption of a broad QRS tachycardia following the resolution of a functional BBB is a rare phenomenon that has not been reported as diagnostic of the tachycardia mechanism. Thus, this observation strongly suggests an OT.

As expected, the disappearance of a LBBB in this case reduced the left ventricular (LV) activation time.³ The VV interval on the right ventricular apex (RVA) did not change after the occurrence of the narrow QRS. In contrast, the last VV interval measured on the coronary sinus (CS) catheter (far field LV potential) was shortened by 70 ms. This induced an earlier atrial activation, which triggered an anterograde conduction block at the AV node.

Another possible mechanism, absent in this case, is the conduction block at the AP, which terminates the tachycardia without an atrial depolarization.

Still, other differential diagnostics of broad QRS tachycardia must be considered. In AVNRT and ectopic atrial tachycardia, BBB does not influence VA conduction or cannot advance AA interval. A ventricular tachycardia could be terminated by a capture beat without fusion, which is expected to be anticipated. In our case, the tachycardia cycle length did not change before termination, ruling out this mechanism.

In conclusion, the interruption of SVT following the resolution of an ipsilateral BBB to an AP is highly suggestive of an OT and it may represent one of the causes of self-terminating SVT in the clinical practice.

Conflict of interest: none declared.

References

1. Di Toro D, Hadid C, López C, Fuselli J, Luis V, Labadet C. Utility of the aVL lead in the electrocardiographic diagnosis of atrioventricular node reentrant tachycardia. *Europace* 2009;**11**:944–8.
2. Katritsis DG, Josephson ME. Differential diagnosis of regular narrow-QRS tachycardias. *Heart Rhythm* 2015;**12**:1667–763.
3. Kerr CR, Gallagher JJ, German LD. Changes in ventriculoatrial intervals with bundle branch block aberration during reciprocating tachycardia in patients with accessory atrioventricular pathways. *Circulation* 1982;**66**:196–201.