

EP CASE REPORT

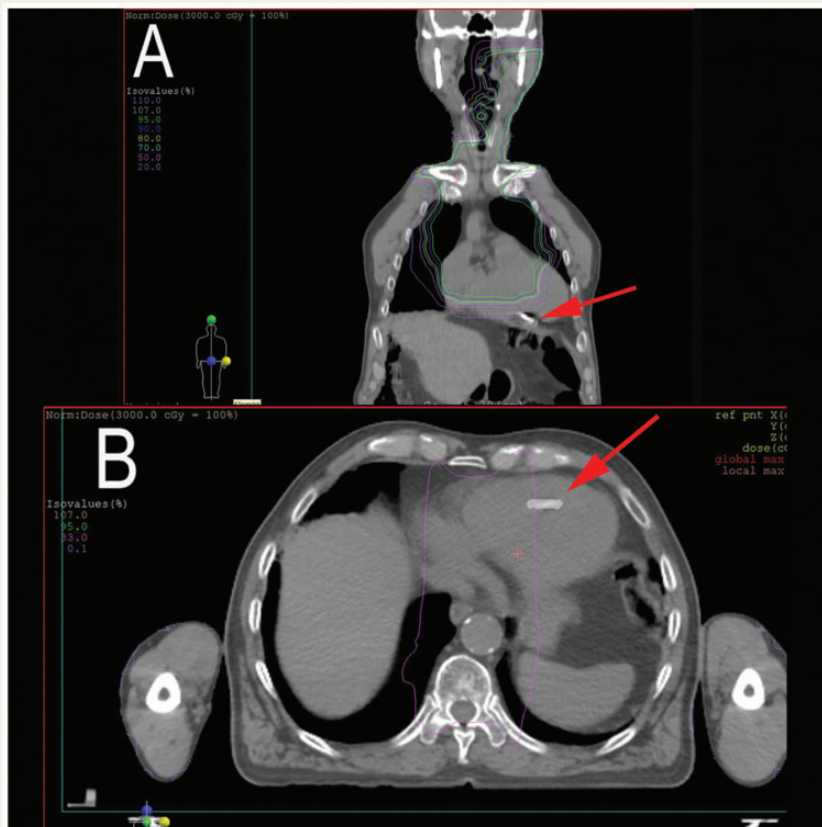
Safe delivery of radiotherapy in a patient with a leadless pacemaker exposed to the radiation beam

José Luis Martínez-Sande*, Javier García-Seara, and Moisés Rodríguez-Mañero

Unidad de Arritmias y Electrofisiología Cardíaca, Servicio de Cardiología y Unidad Coronaria. Hospital Clínico Universitario de Santiago de Compostela. IDIS. CIBERCV, Travesía Choupana s/n 15706, Santiago de Compostela, A Coruña, Spain

* Corresponding author. Tel: +34 981 950 674; fax: +34 981 950 000. E-mail address: luismartinezsande@gmail.com

Radiation therapy (RT) can have significant effects on the function of cardiac pacemakers.¹ Leadless pacemakers have been suggested as a promising alternative for patients with tumours of the upper chest/head as it is often feasible to keep them outside the field of interest. Nevertheless, the effects of higher energy RT in patients with leadless pacemakers that remain within the irradiation field is unknown. No formal recommendations are currently available when the device is directly exposed to the radiation beam. If photon beam energy exceeds 10 MV, Medtronic recommends interrogating the device immediately after RT and identifying the potential occurrence of oversensing, device damage, and device operational errors.



We report on an 85-year-old man with a history of atrial fibrillation with slow ventricular response, implanted with a leadless pacemaker (Micra, Medtronic Ibérica S.A., Madrid, Spain) in an uneventful procedure.² Six months post-implantation, the patient was diagnosed with Hodgkin's lymphoma, with a large mediastinal mass that required RT. The pacemaker (arrow) is shown (Figure 1) to be in contact with the treatment fields in the coronal (Panel A) and axial (Panel B) planes. As is evident, the device was partially immersed within the radiation field with beam range intersecting it. Although patient was not pacemaker dependent (ventricular pacing was 63%), in an effort to prevent inhibition by electromagnetic interference, the device was programmed to V00 prior to every session and evaluated after completion of RT in order to assess for latent damage. Electrocardiographic (ECG) monitoring was performed throughout RT exposure. Estimated maximum

proton doses were 30 Gy in 15 sessions. Distribution of photon beam was 6 MV in the anteroposterior and 15 MV in the posteroanterior fields. Ultimately, the patient completed all the scheduled sessions without any remarkable dysfunction (see Supplementary material online, Figure S1).

In conclusion, in this first experience of RT in a patient with a leadless pacemaker exposed within the radiation field, ECG monitoring and continuous monitoring of the device excludes remarkable damage to the device, endorsing its potential use in patients with RT requirement.

Supplementary material

Supplementary material is available at *Europace* online.

Conflict of interest: none declared.

References

1. Zaremba T, Jakobsen AR, Søgaard M, Thøgersen AM, Riahi S. Radiotherapy in patients with pacemakers and implantable cardioverter defibrillators: a literature review. *Europace* 2016;**18**:479–91.
2. Martínez-Sande JL, García-Seara J, Rodríguez-Mañero M, Fernández-López XA, González-Melchor L, Redondo-Diéguez A *et al*. Micra leadless transcatheter pacemaker. Implant and mid-term follow-up results in a centre. *Rev Esp Cardiol* 2016 Dec 28 [Epub ahead of print].