

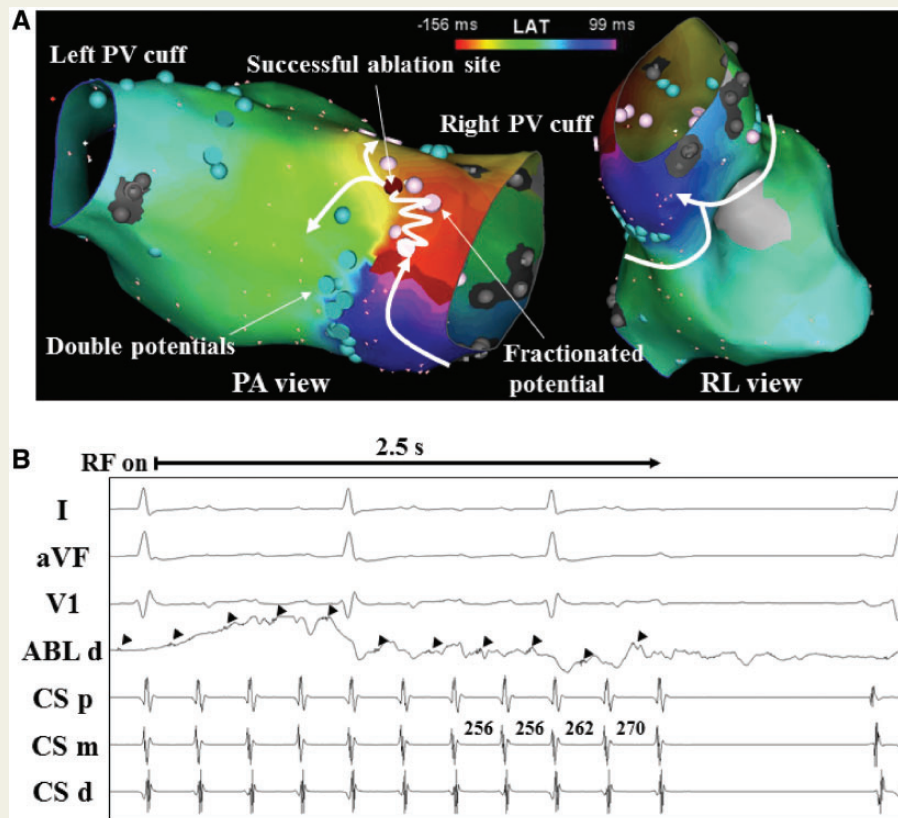
EP CASE REPORT

Left atrial and pulmonary vein flutter associated with double electrical connections after a lung transplantation

Taihei Itoh and Takumi Yamada*

Division of Cardiovascular Disease, University of Alabama at Birmingham, FOT 930A, 510 20th Street South, Birmingham, AL 35294-0019, USA

* Corresponding author. Tel: +1 205 975 2404; fax: +1 205 996 5857. E-mail address: takumi-y@fb4.so-net.ne.jp



A 53-year-old man with a history of a bilateral lung transplantation (LT) at the age of 39 underwent electrophysiological testing of supraventricular tachycardia (SVT). At baseline, the SVT persisted, and exhibited positive P waves in the inferior leads and lead V1. The activation map in the left atrium (LA) revealed a centrifugal pattern from the right pulmonary vein (RPV) cuff (Panel A). Further mapping within the RPV cuff revealed that the activation propagated from the RPV cuff to the LA through a first conduction gap located at the superior aspect of the RPV cuff and from the LA back to the RPV cuff through a second conduction gap located at the inferior aspect of the RPV cuff (Panel A). It was noted that double potentials or scar were recorded along the presumed suture line between the donor PV cuff and recipient LA (Panel A). These findings suggested that the SVT should be a figure-of-eight type macroreentrant atrial flutter (AFL) associated with two conduction gaps between the donor PV cuff and recipient LA. The results of entrainment pacing from both the anterior and posterior LA wall along the RPV cuff supported this mechanism. A single irrigated radiofrequency application was delivered at the first conduction gap with a fractionated mid-diastolic potential, resulting in a prolongation of the SVT cycle length followed by termination of the SVT (Panel B). A couple of irrigated radiofrequency applications were delivered at the second conduction gap, resulting in the isolation of the RPV cuff. A single electrical connection between the left pulmonary vein cuff and LA was observed at the posterior aspect of their junction, but catheter ablation was not performed at that site.

To the best of our knowledge, this is the first report illustrating a macroreentrant AFL associated with two electrical connections between the donor PV cuff and recipient LA after an LT. In an LT, a surgical incision is made at the LA receiving both the superior and inferior pulmonary veins, and this part of the LA is utilized as the donor PV cuff in an LA to LA anastomosis. An electrical connection crossing a suture line between the donor PV cuff and recipient LA after an LT is rare, but can occur.¹ This case report demonstrated such an electrical connection could occur at multiple sites, resulting in the occurrence of a macroreentrant AFL.

Conflict of interest: none declared.

Reference

1. Sacher F, Vest J, Raymond JM, Stevenson WG. Incessant donor-to-recipient atrial tachycardia after bilateral lung transplantation. *Heart Rhythm* 2008;**5**:149–51.