

## EP CASE REPORT

# Inappropriate sinus tachycardia in a heart transplant successfully treated with ivabradine

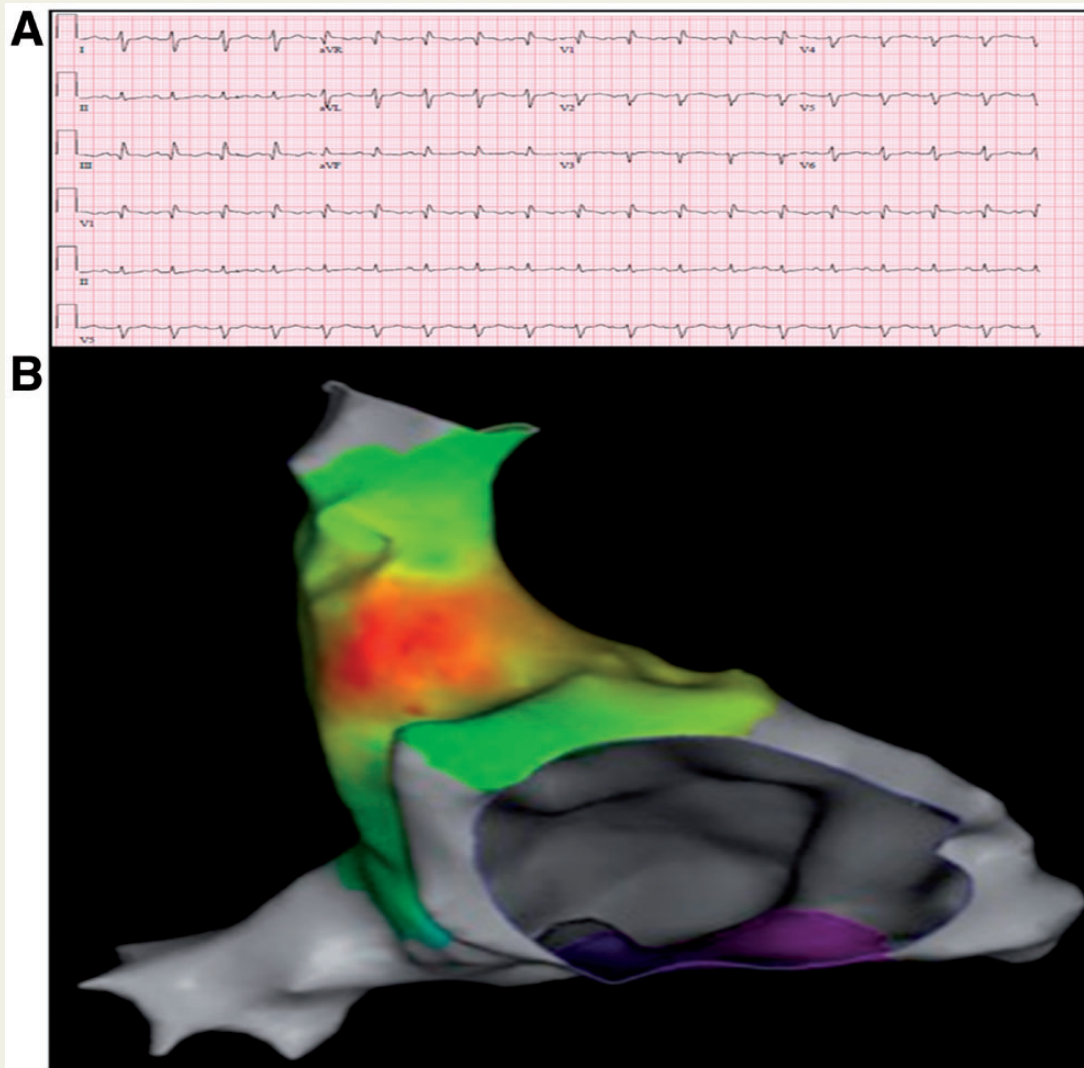
Nishaki Mehta\*, Aneesh Bapat, Usha Tedrow, William Gregory Stevenson, and Bruce Koplan

Department of Cardiology, Brigham and Women's Hospital, 75 Francis Street, PBB-1, Boston, MA 02115, USA

\* Corresponding author. Tel: (617) 732 7144; fax: (617) 732 7134. E-mail address: nmehta0@partners.org

A 55-year old male with familial dilated cardiomyopathy treated with bi-atrial orthotopic heart transplant in 1986, followed by allograft rejection and bi-caval transplantation in 2005, presented to the hospital with 4 months of worsening heart failure symptoms. Workup included transthoracic echocardiography (TTE), which revealed a newly depressed left ventricular ejection fraction (LVEF) of 45% (previously 65%). Cardiac catheterization revealed elevated filling pressures with no epicardial coronary artery disease, and endomyocardial biopsy was negative for allograft rejection. During the hospitalization, he was tachycardic due to a presumed compensatory sinus tachycardia in the 130s (Panel A) which persisted even when he was euvolemic.

He represented 3 months later with similar symptoms and TTE revealed a further decrement in his LVEF to 35%. Repeat endomyocardial biopsy was negative for allograft rejection. Owing to his persistent long-RP tachycardia, a basic workup, including basic metabolic panel and thy-



roid testing, was done and was unrevealing. Electrophysiology was consulted for concern of an atrial tachycardia; he underwent electrophysiology study demonstrating atrial activation in the sinoatrial nodal region (*Panel B*). There was no evidence of atrio-atrial tachycardia. During the study, cavotricuspid isthmus dependent atrial flutter was induced and ablated. He was optimized from a volume standpoint, and his home dose of metoprolol was cautiously increased owing to borderline blood pressure. He was discharged with outpatient Holter monitoring, which revealed a mean heart rate of 127 bpm (range 116–147 bpm). Attempts to escalate beta blocker therapy were hindered by symptomatic hypotension. The patient returned with heart failure symptoms a month later. Given the persistent long-RP tachycardia concerning for inappropriate sinus tachycardia (IST) and the worsening LV function with no other precipitating factors, a diagnosis of IST related tachycardia induced cardiomyopathy (TCM) was entertained. Ivabradine, which reduces heart rate by acting on  $I_f$  ion channels of the sinoatrial node, was started. Within 24 h, his resting heart rate improved to 90–110 bpm. His heart failure symptoms improved, and he was discharged on a stable ivabradine dose. Follow-up echocardiography 6 weeks later showed recovery of LVEF to 50%. At 5-month follow-up, he has been tolerating ivabradine well with no cardiac or extra-cardiac adverse effects, and has had no recurrent heart failure exacerbations.

To our knowledge, this is the first reported case of the successful use of ivabradine to treat IST-related cardiomyopathy in a transplanted heart. IST is a rare cause of TCM, and anecdotally ivabradine has previously been used to reverse systolic dysfunction in IST-related TCM. There is a prior report of transplant patient with IST-related TCM successfully managed with sinoatrial nodal modification and  $\beta$ -blockers.<sup>1</sup> Previous studies have demonstrated that ivabradine can be safely used in heart transplant patients to reduce their baseline elevated heart rate, which can portend poor long term prognosis. Ivabradine use in the transplant population has also been associated with beneficial effect on LV remodelling. Long-term studies up to 48 months have established efficacy of ivabradine in this population.<sup>2</sup> Given the emerging use and data regarding ivabradine, it offers a promising management strategy for IST related TCM in the transplant population.

**Conflict of interest:** none declared.

## References

1. Ho RT, Ortman M, Mather PJ, Rubin S. Inappropriate sinus tachycardia in a transplanted heart. Further insights into pathogenesis. *Heart Rhythm* 2011;**8**:781–83.
2. Zhang R, Bobylev D, Stiefel P, Haverich A, Bara C. Lasting reduction of heart transplant tachycardia with ivabradine is effective and well tolerated: Results of 48-month study. *Clin Res Cardiol* 2012;**101**:631–36.