

## EP CASE REPORT

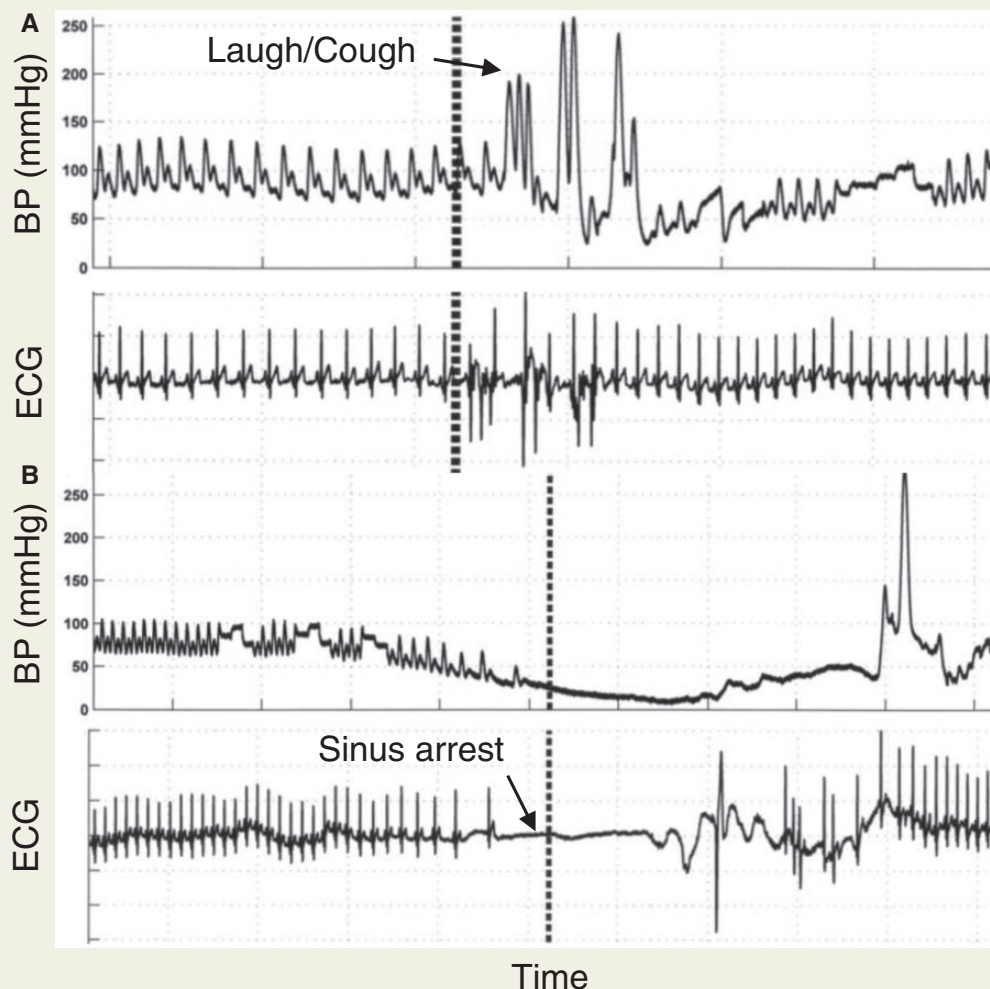
# Cardioinhibitory and vasodepressor responses to different stressors on head-up tilt

Arunashis Sau<sup>1</sup>, Patricia Taraborrelli<sup>2</sup>, Philip Moore<sup>3</sup>, and Phang Boon Lim<sup>1,2\*</sup>

<sup>1</sup>Imperial College London, London, UK; <sup>2</sup>Department of Cardiology, Hammersmith Hospital, Imperial College Healthcare NHS Trust, Du Cane Road, London W12 0HS, UK; and <sup>3</sup>Department of Cardiology, West Hertfordshire Hospitals NHS Trust, London, UK

\* Corresponding author. Tel: +44 203 313 4967; fax: +44 203 313 4232. E-mail address: p.b.lim@imperial.ac.uk

We describe the case of an overweight 37-year-old man with a history of laughter-induced syncope, which caused him to crash his car. The patient was a non-smoker with a history of obesity with a body mass index of 33.5, obstructive sleep apnoea, gastro-oesophageal reflux and depression. 24-h Holter monitoring showed sinus rhythm throughout, with a mean heart rate of 87 bpm, without any significant tachy or bradyarrhythmias. He was referred to our tertiary head-up tilt table (HUT) testing service to determine the cause of syncope.



The patient underwent HUT using the Italian protocol with glyceryl trinitrate (GTN) provocation.<sup>1</sup> At 10 min, the patient was asked to laugh which ended in a spontaneous vigorous cough. He started to feel lightheaded immediately following the cough, when the systolic BP dropped to 65 mmHg, before recovering back to baseline levels within 10 s with a slight increase in heart rate (*Panel A*). He was asked to laugh three further times, 15 min into tilt, 3 and 8 min after GTN. All instances ended in a cough, resulted in a sweaty and dizzy feeling and had a drop in systolic BP to 90 mmHg, 70 mmHg and 59 mmHg, respectively, each with a rise in heart rate.

At 32 min into tilting, he became unresponsive, during which time there was a period of asystole for 12 s due to sinus arrest and loss of consciousness for 40 s (*Panel B*). He began to make anoxic movements with his arms tensed up in flexion. Recovery was prolonged, taking 20 min after regaining consciousness, which was completely unfamiliar to him.

This tilt test was consistent with a diagnosis of vasovagal syncope with a VASIS 2B (strong cardioinhibitory) collapse pattern. However, given the presenting complaint, the more relevant clinical diagnosis was cough/laughter-induced syncope, which was a pure vasodepressor response without reduction in heart rate.

This patient represents the first description to our knowledge of a patient with different reflex responses depending on the stressor. Our previous study has shown that cough syncope causes syncope predominantly via the vasodepressor mechanism.<sup>2</sup> In this case, the vasodepressor response to coughing/laughing coexisted with a distinct non-clinical cardioinhibitory response to orthostatic stress. This case supports the hypothesis that there are distinct reflex mechanisms for syncope depending on the triggering mechanism. Therefore, in patients with specific types of situational syncope (e.g. cough and laugh) clinical decisions should be made on only the response to the clinically provoking factor. Due to the vasodepressor nature of the response of cough syncope, there is no role for pacemaker insertion to treat this condition. Even with an asystolic response correlating with the spontaneous clinical event, we have previously shown that cardioinhibitory syncope is often benign.<sup>3</sup>

The patient was advised to increase fluid and salt intake and reduce caffeine intake, reduce weight. He was taught isometric counter-pressure manoeuvres to use if he does recognize prodromal symptoms and advised to cease driving. After 1-year follow-up, he has lost a significant amount of weight, and there have been no further occurrences of pre-syncope or syncope.

**Conflict of interest:** none declared.

## Funding

P.B.L. is in receipt of research grants from Medtronic, St. Jude Medical and Boston Scientific.

## References

1. Bartoletti A, Alboni P, Ammirati F, Brignole M, Del Rosso A, Foglia Manzillo G *et al.* "The Italian Protocol": a simplified head-up tilt testing potentiated with oral nitroglycerin to assess patients with unexplained syncope. *Europace* 2000;**2**:339–342.
2. Mereu R, Taraborrelli P, Sau A, Di Toro A, Halim S, Hayat S *et al.* Diagnostic role of head-up tilt test in patients with cough syncope. *Europace* 2016;**18**:1273–9.
3. Sau A, Mereu R, Taraborrelli P, Dhutia NM, Willson K, Hayat SA *et al.* A long-term follow-up of patients with prolonged asystole of greater than 15s on head-up tilt testing. *Int J Cardiol* 2016;**203**:482–485.