

Respiratory cycle-dependent left atrial tachycardia in a former Tour de France cyclist

Andreas Müssigbrodt*, Gerhard Hindricks, and Andreas Bollmann

Department of Electrophysiology, Heart Centre, University Leipzig, Strümpellstrasse 39, Leipzig 04289, Germany

* Corresponding author. Tel: +49 341 865 1413; fax: +49 341 865 1460. E-mail address: andreas.muessigbrodt@gmail.com

Palpitations in a former world class cyclist, caused by respiratory cycle-dependent left atrial tachycardia, is described in this case report. Electrophysiological study revealed an irregular atrial tachycardia, originating from the left superior pulmonary vein (LSPV). Deep

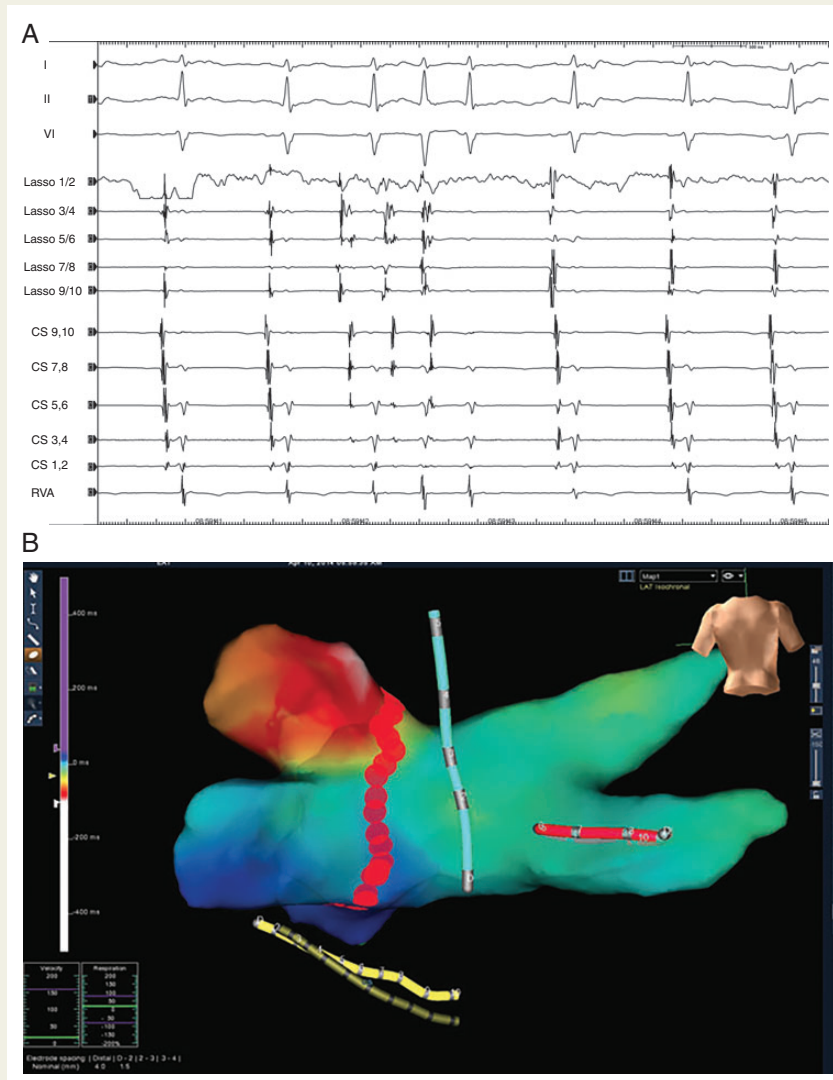


Figure 1 (A) First two and last three beats are sinus beats, the other three beats are ectopic beats; surface electrocardiogram: I, II, V1; intracardiac electrograms from circular decapolar catheter (Lasso) in left superior pulmonary vein, coronary sinus (9/10 proximal, 1/2 distal), right ventricular apex; paper speed 50 mm/s. Artefacts and baseline shifts in the surface electrocardiogram leads I, II, and V1 are due to deep respiration. (B) Posterior–anterior view of the left atrium with a colour-coded activation map, using the Ensite NAVx three-dimensional mapping system (St Jude Medical, St Paul, MN, USA). Red colour indicates the origin of the AT from the left superior pulmonary vein with the earliest signals compared with coronary sinus reference. Blue and green colours indicate regions with later activation of the atrium. The red dots around the left pulmonary vein indicate radiofrequency catheter ablation lesions, using an irrigated tip catheter (Therapy Coolflex, St Jude Medical, St Paul, MN, USA).

inspiration triggered the 'firing' of the ectopic atrial focus. The patient underwent isolation of the LSPV and remained symptom-free during the follow-up.

Palpitations in athletes and former athletes can indicate potentially life-threatening ventricular arrhythmias but can also indicate easily treatable supraventricular tachycardia (SVT).^{1,2} A common SVT in endurance athletes is atrial fibrillation (AF); however, many other different kinds of SVT can also be diagnosed.^{1,2} Recurring palpitations justify electrophysiological study (EPS), even without electrocardiographic (ECG) documentation.¹

Respiratory cycle-dependent atrial tachycardia is a rare form of SVT. To date, only a few case reports and one case series dealing with such respiratory cycle-dependent arrhythmias have been published.³ To our knowledge, no respiratory cycle-dependent atrial tachycardia in an athlete has been described in the literature.

A 48-year-old still physically very active, former elite cyclist presented with symptomatic palpitations. Electrophysiological study revealed an irregular atrial tachycardia with eccentric activation of the coronary sinus, 280–420 ms cycle length. Pacing manoeuvres excluded an atrio-ventricular reentrant tachycardia. Varying cycle length and ventriculo-atrial intervals indicated a focus in the left atrium. After trans-septal access activation mapping was performed, using the Ensite NavX (St Jude Medical, St Paul, MN, USA) system. Herewith an originating from the left superior pulmonary vein (LSPV) was shown. Deep inspiration triggered the 'firing' of the ectopic atrial focus as shown in *Figure 1A* and Supplementary material online, *Video S1*. The patient underwent isolation of the LSPV by radiofrequency catheter ablation (RFCA) (*Figure 1B*), using an irrigated tip catheter (Therapy Coolflex, St Jude Medical, St Paul, MN, USA) and remained symptom-free during the follow-up.

Respiratory cycle-dependent left atrial tachycardia occur infrequently in patients with symptomatic SVT and can be effectively treated with RFCA.³ As shown with this example, they do also occur in athletes. Whether respiratory cycle-dependent left atrial tachycardia play a role as a trigger for AF in athletes warrants further investigations.

In literature temporal vagal activation or pulmonary vein stretch by an increased venous return has been assumed as the cause of the arrhythmia.³ In contrast to this hypothesis, we believe that adrenergic activation of triggers inside the pulmonary vein(s) is necessary for respiratory cycle-related atrial tachycardia since our patient reported an augmentation of palpitations during competition and exercise. Furthermore, the arrhythmia disappeared during sedation with propofol. Deep inspiration was associated with the arrhythmia only during an awake state. After isolation of the pulmonary vein we did not observe anymore firing inside the pulmonary vein. This might have been due to the sedated state of consciousness or the ablation of ganglia. During follow-up, the patient remained free of symptoms.

Supplementary material

Supplementary material is available at *Europace* online.

References

1. Heidbuchel H, Panhuyzen-Goedkoop N, Corrado D, Hoffmann E, Biffi A, Delise P *et al*. Recommendations for participation in leisure-time physical activity and competitive sports in patients with arrhythmias and potentially arrhythmogenic conditions. Part I: Supraventricular arrhythmias and pacemakers. *Eur J Cardiovasc Prev Rehabil* 2006;**13**: 475–84.
2. Müssigbrodt A, Richter S, Wetzell U, Van Belle Y, Bollmann A, Hindricks G. Diagnosis of arrhythmias in athletes using leadless, ambulatory HR monitors. *Med Sci Sports Exerc* 2013;**45**:1431–5.
3. Yamamoto T, Hayashi M, Miyauchi Y, Murata H, Horie T, Igawa O *et al*. Respiratory cycle-dependent atrial tachycardia: prevalence, electrocardiographic and electrophysiologic characteristics, and outcome after catheter ablation. *Heart Rhythm* 2011;**8**:1615–21.