

Slow automaticity of a Mahaim fibre after radiofrequency ablation

Nikola Pavlović, Michael Kühne, and Christian Sticherling*

Cardiology, University Hospital Basel, Basel, Switzerland

* Corresponding author. Tel: +41 61 265 7526; Fax: +41 61 265 4598. E-mail address: Christian.Sticherling@usb.ch

Atriofascicular accessory pathways (Mahaim fibres) are an uncommon form of pre-excitation. They are usually located on the right side and have similar electrophysiological features as the normal conduction system. We describe a case of a patient with an atriofascicular accessory pathway with Mahaim automaticity recorded at the time of ablation and at 3-month follow-up, but with no recurrence of tachycardia.

A 48-year-old patient underwent electrophysiology study (EPS) for frequent symptomatic wide QRS tachycardia with left bundle-branch morphology, a rate of 150 beats per minute, left axis deviation, and a late precordial transition. During the EPS, atriofascicular accessory pathway (Mahaim fibre) was identified. Pre-excitation occurred with high right atrium pacing and tachycardia could repeatedly be induced with programmed stimulation. Mahaim potential was targeted for ablation at the lateral tricuspid annulus (Figure 1A, arrow). During the

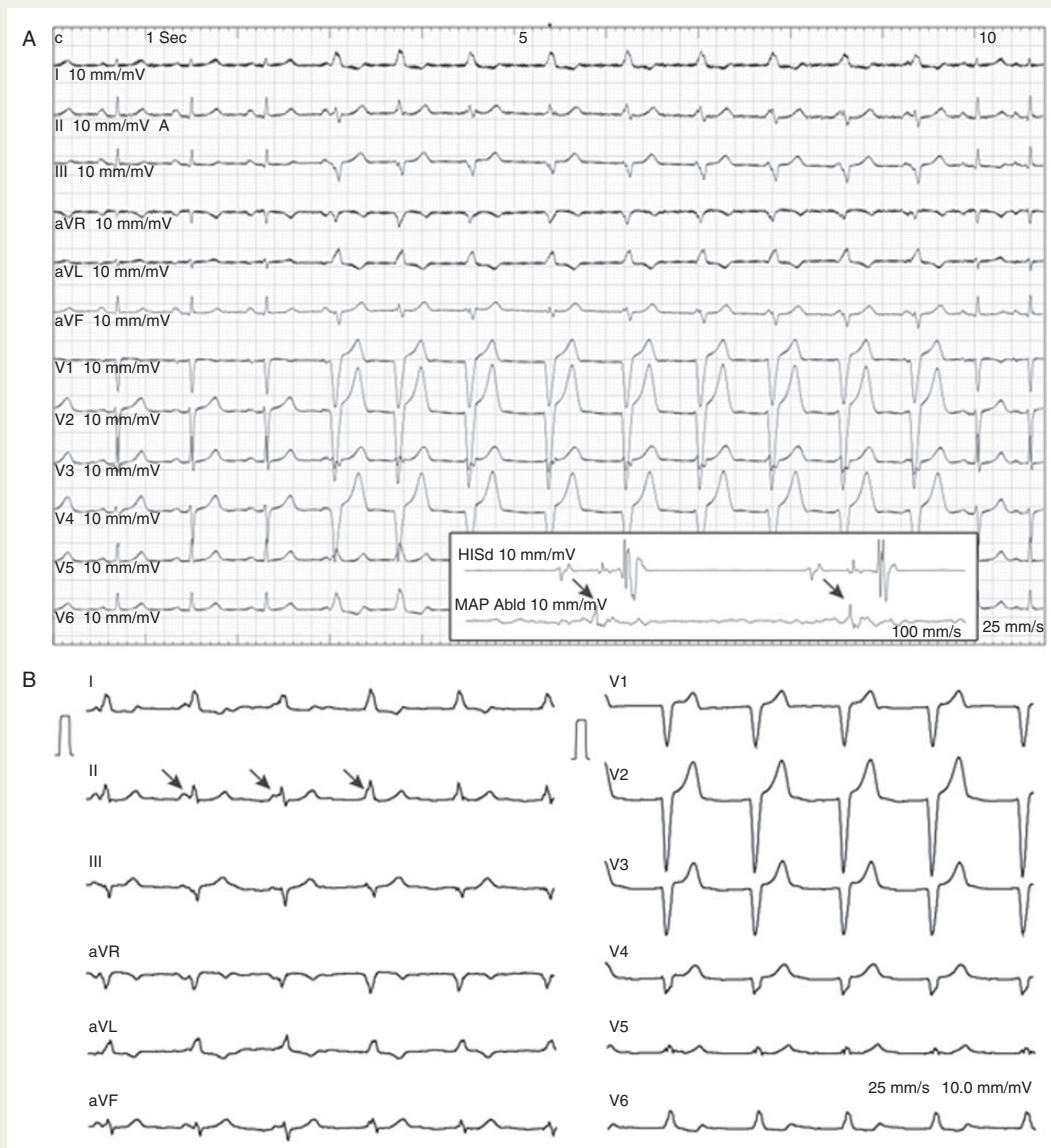


Figure 1 (A) 12 lead ECG during RF ablation showing RF induced automaticity. Inset: Mahaim potential (arrow) at the lateral tricuspid annulus. (B) 12 lead ECG with asymptomatic Mahaim automaticity 3 months after ablation. AV dissociation is shown with the arrows.

radiofrequency (RF) ablation, RF-induced automaticity of a Mahaim fibre was induced and disappeared potentially indicating successful ablation (Figure 1A). After the ablation tachycardia was non-inducible and there was no pre-excitation with atrial pacing. At the 3-month follow-up, the patient was completely asymptomatic and presented with the 12 lead ECG showing slow rhythm identical to the automaticity recorded during RF ablation (Figure 1B). Spontaneous automaticity from Mahaim fibers has been described and was found to occur in 12.5% of 40 patients with Mahaim fibres.¹ Spontaneous automaticity ranges from slow asymptomatic rhythms to fast tachycardia and can occur pre ablation, during the ablation and early after successful RF ablation.^{2,3} Automaticity after RF ablation is rare and its true incidence and clinical relevance are unknown. Since the automaticity was verified in 12 lead ECG where clear AV dissociation could be seen and the patient is asymptomatic reablation was not necessary. However, whether the finding has a long-term arrhythmogenic potential remains speculative. In summary, the rhythm documented during the 3-month follow-up visit is most likely explained by automaticity of the Mahaim fibre distal to the ablation site. Idioventricular rhythm (spontaneous or scar-related after RF ablation) arising from the ventricular myocardium just distal to the ablation site is unlikely, but cannot be ruled out. A slow antidromic rhythm can clearly be excluded due to the presence of atrioventricular dissociation (Figure 1B, arrows).

Conflict of interest: none declared.

References

1. Sternick EB, Sosa EA, Timmermans C, Cruz Filho FE, Rodriguez L-M, Gerken LM et al. Automaticity in Mahaim fibers. *J Cardiovasc Electrophysiol* 2004;**15**:738–44.
2. Strohmer B, Schernthaner C, Hwang C. Spontaneous automaticity arising from a successfully ablated Mahaim fiber. *J Interv Card Electrophysiol* 2007;**20**:25–8.
3. Sternick EB, Gerken LM, Vrandeic M. Appraisal of 'Mahaim' automatic tachycardia. *J Cardiovasc Electrophysiol* 2002;**13**:244–9.