

Left superior pulmonary vein ectopic rhythm mimicking normal sinus rhythm

Jorge Gonzalez¹, Jason G. Andrade^{1,2}, and Laurent Macle^{1*}

¹Electrophysiology Service, Department of Medicine, Montreal Heart Institute, Université de Montréal, Montreal, QC H1T 1C8, Canada and ²The Department of Medicine, The University of British Columbia, British Columbia V6N 3S9, Canada

* Corresponding author. Electrophysiology Service, Montreal Heart Institute, 5000 Belanger St. E. Montreal, QC, Canada, H1T 1C8. Tel: +1 514 376 3330 ext. 4075; fax: +1 514 593 2551. E-mail address: lmacle@mac.com

While spontaneous rapid repetitive discharges of atrial myocardium inside the pulmonary veins (PVs) have been described as a trigger for atrial fibrillation (AF), a stable spontaneous ectopic atrial rhythm originating from the PV is rarely encountered. Herein, we report a case of a patient with paroxysmal AF in whom two different ectopic PV rhythms mimicking sinus rhythm were observed.

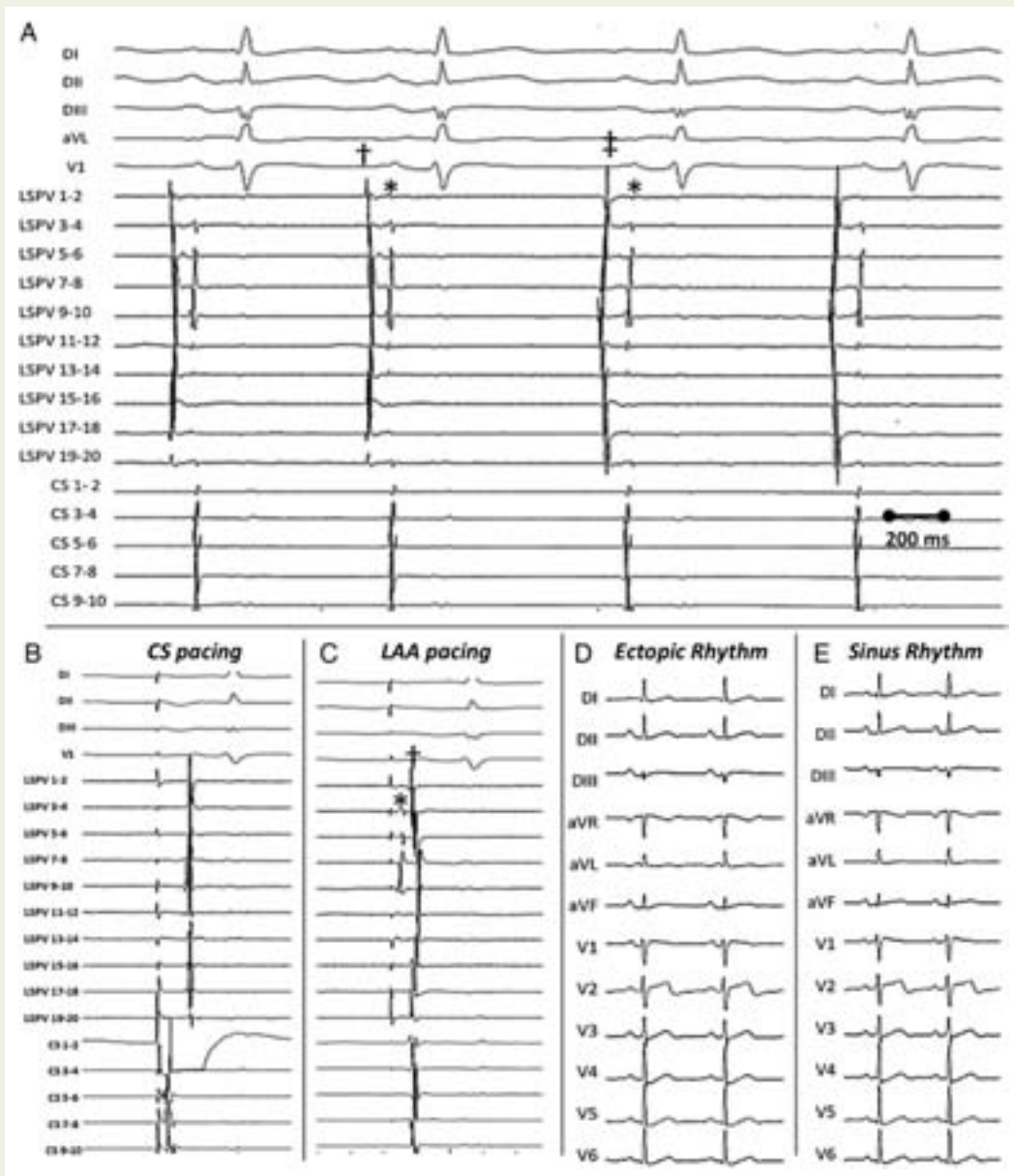


Figure 1 Left Superior Pulmonary Vein. See manuscript text for discussion of panels.

Case report

A 45-year-old man underwent circumferential pulmonary vein (PV) isolation for symptomatic drug-refractory (flecainide and bisoprolol) paroxysmal atrial fibrillation (AF). At the onset of the procedure, two alternating regular ectopic rhythms were recorded on the circular mapping catheter (CMC) positioned at the ostium of the left superior PV (LSPV—*Figure 1A*). The dominant rhythm had a cycle length (CL) of 672 ms. Review of the electrograms (EGMs) demonstrated an initial 'near-field' component (sharp upstroke, narrow width, and a high dv/dt) with a circumferential distribution (\dagger) that preceded the surface P-wave by 40 ms (earliest activation on LSPV bipoles 1–2 and 19–20). This was followed by a far-field EGM with non-circumferential distribution (*). During the second rhythm (CL of 839 ms), the first component also demonstrated near-field characteristics (\dagger); however, the earliest activation was now observed on the CMC bipoles 9–10 and now preceded the surface P-wave by 73 ms. Differential pacing from the distal coronary sinus (CS) and the left atrial appendage (LAA) confirmed the LSPV origin of the underlying rhythm. While distal CS pacing (*Figure 1B*) demonstrated synchronous activation of the far-field and near-field EGM, pacing from the LAA induced a separation of the two EGM components, with the first EGM corresponding to far-field left atrial (LA) signal (*) followed by the PV potential (\dagger —*Figure 1C*). No relation between these ectopic atrial rhythms and AF initiation was observed. During isolation of the LSPV, entrance and exit conduction block was preceded by significant PV to LA conduction delay. Once isolation was achieved, an immediate change was observed in P-wave axis and morphology (*Figure 1D and E*). A stable dissociated PV ectopic rhythm was observed up to 60 min post-LSPV isolation.

Discussion

The rarity of this dysrhythmia, as well as its similarity to sinus rhythm and the absence of this rhythm previously may explain why the ectopic origin of the rhythm was initially overlooked. On careful comparison, subtle differences in the P-wave morphology can be appreciated (*Figure 1D and E*). Specifically, during the ectopic rhythm the P-wave axis was more rightward ($+90^\circ$ in ectopy to $+50^\circ$ in sinus) with a morphology that was more consistent with a posterior LA origin (lower amplitude in lead I, negative in aVL, and 'dome-and-dart' in V1).^{1,2} However, careful EGM interpretation and differential pacing are required for source localization. Specifically, while near-field LSPV EGMs preceded the surface P-wave (making a right atrial origin unlikely), differential pacing was required to differentiate a focal PV source from a posterior LA or LAA origin. In this case, distal CS pacing was less useful given the anatomic proximity of the arrhythmic source and the pacing site. Conversely, LAA pacing provided definitive proof of PV origin. The stable and persistent nature of the ectopic pacemaker sites suggests abnormal automaticity as its mechanism, with the CL of the discharges potentially influenced by the use of Class I antiarrhythmic drugs.

Conflict of interest: none declared.

References

1. Yamane T, Shah DC, Peng JT, Jais P, Hocini M, Deisenhofer I et al. Morphological characteristics of p waves during selective pulmonary vein pacing. *J Am Coll Cardiol* 2001;**38**: 1505–10.
2. Jais P, Hocini M, Macle L, Choi KJ, Deisenhofer I, Weerasooriya R et al. Distinctive electrophysiological properties of pulmonary veins in patients with atrial fibrillation. *Circulation* 2002;**106**:2479–85.