

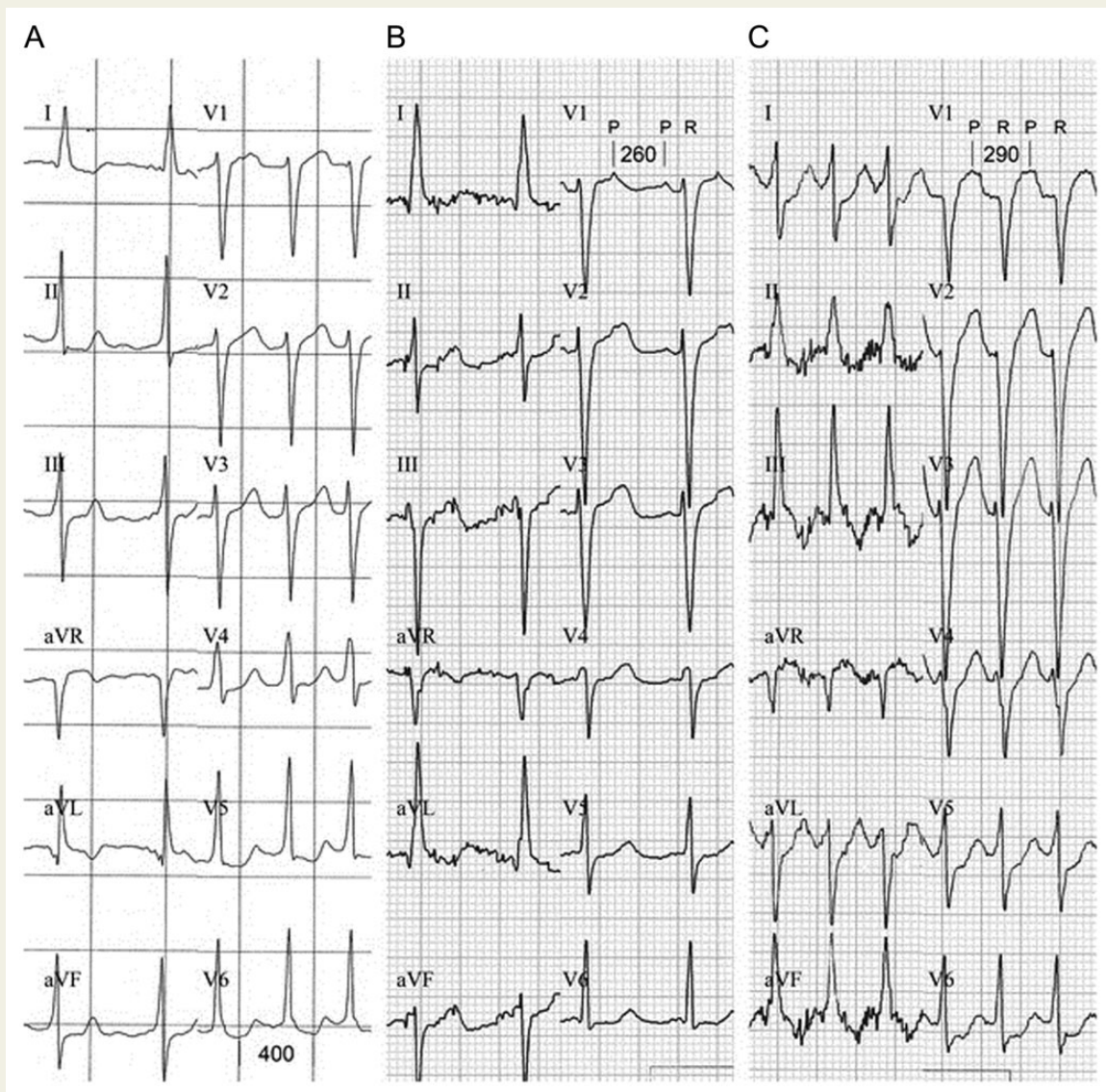
## Atrial flutter with 1 : 1 atrioventricular conduction after administration of vernakalant for atrial fibrillation

Christine Franzini<sup>1\*</sup>, Stephan Andreas Müller-Burri<sup>1</sup>, and Dipen C. Shah<sup>2</sup>

<sup>1</sup>Department of Cardiology, Stadtspital Triemli, Birmensdorferstrasse 497, 8063 Zürich, Switzerland; and <sup>2</sup>Department of Cardiology, Hôpitaux Universitaires de Genève, Rue Gabrielle-Perret-Gentil 4, 1205 Geneva, Switzerland

\* Corresponding author. Tel: +41 44 466 13 49; fax: +41 44 466 27 97, Email: christine.franzini@gmx.ch

A 44-year-old healthy woman presented with atrial fibrillation. Vernakalant was administered. Organization to 2 : 1 with transition to 1 : 1 atrial flutter occurred. Vernakalant is a novel, effective, and relatively safe antiarrhythmic drug used for cardioversion of recent onset atrial fibrillation. Our case demonstrates, that in addition to the well-known adverse events, rapid 1 : 1 atrial flutter should be considered when using vernakalant.



**Figure 1** 12-lead electrocardiogram. (A) Atrial fibrillation with rapid ventricular rates. (B) Atrial flutter (atrial cycle length 260 ms) with 2:1 atrioventricular conduction. (C) Atrial flutter (atrial cycle length 290 ms) with 1:1 atrioventricular conduction.

A previously healthy 44-year-old woman presented with a first episode of recent onset atrial fibrillation (Figure 1A). She denied medication, alcohol, or illicit drug use. Physical examination was unremarkable apart from tachycardia. Electrolytes were within normal range.

Intravenous vernakalant was administered as first-line treatment. As atrial fibrillation persisted after a 15 min observation period, a second infusion was started. Shortly thereafter, organization into atrial flutter [atrial cycle length (aCL) 260 ms] with 2 : 1 atrioventricular (AV) conduction occurred (Figure 1B). Vernakalant administration was continued. Four minutes after completing the second infusion, the aCL prolonged to 290 ms resulting in 1 : 1 AV conduction (Figure 1C). The patient needed immediate electrical cardioversion for haemodynamic instability. A transthoracic echocardiogram revealed a structurally normal heart with normal systolic function, normal sized atria, and no valvulopathy. Electrophysiology study showed dual AV-node physiology, no evidence of accessory pathway, and no inducible arrhythmias.

Vernakalant is a newer antiarrhythmic drug, designed to overcome the safety issues of the currently available drugs for medical cardioversion of atrial fibrillation. Vernakalant is a relatively atrial-selective multi-ion channel blocker. It acts by concentration-dependent blockade of the atria-specific  $K^+$ -channels  $I_{Kur}$  and  $I_{KACh}$ , modest blockade of the atrial and ventricular expressed  $K^+$ -channels  $I_{to}$ ,  $I_{KATP}$ ,  $I_{Kr}$ , and frequency-dependent blockade of the  $Na^+$ -channel  $I_{Na}$ . The net effect results in prolongation of atrial refractoriness, slight prolongation of AV nodal refractoriness, and slight rate-dependent slowing of intra-atrial, AV, and His Purkinje conduction. It has no significant influence on ventricular refractoriness.<sup>1</sup> These properties are accountable for the fact that vernakalant effectively terminates ~50% of recent onset atrial fibrillation without occurrence of rapid conducted atrial flutter or serious ventricular arrhythmias.<sup>2</sup>

The guidelines recommend vernakalant for medical cardioversion of recent onset atrial fibrillation in patients with no or minimal structural heart disease (I A) and with some restrictions in patients with moderate heart disease (IIb B).<sup>3</sup>

To date, one case of vernakalant-related haemodynamically stable atrial flutter with 1 : 1 AV conduction with aberrancy has been reported in a patient undergoing typical atrial flutter ablation. The present case describes the first occurrence of a haemodynamically relevant atrial flutter with 1 : 1 AV conduction after administration of vernakalant in a patient with a structurally normal heart and no evidence of pre-existing arrhythmias. The fact that in this case aberrant conduction was absent even at high ventricular rates, may accentuate vernakalant's atrial selectiveness.

This case emphasizes the importance of careful patient monitoring, even when applying safer drugs for cardioversion, and raises the question if vernakalant should be discontinued when atrial flutter occurs with administration.

**Contributorship:** C.F. wrote the initial manuscript. S.A.M. and D.C.S. edited the manuscript. C.F. and S.A.M. were responsible for the patients care. All authors read and approved the final manuscript.

**Conflict of interest:** none declared.

**Informed consent:** Informed consent was obtained.

## References

1. Dorian P, Pinter A, Mangat I, Korley V, Cvitkovic SS, Beach GN. The effect of vernakalant (RSD1235), an investigational antiarrhythmic agent, on atrial electrophysiology in humans. *J Cardiovasc Pharmacol* 2007;**50**:35–40.
2. Roy D, Pratt CM, Torp-Pedersen C, Wyse DG, Toft E, Juul-Moller S *et al.* Vernakalant hydrochloride for rapid conversion of atrial fibrillation: a phase 3, randomized, placebo-controlled trial. *Circulation* 2008;**117**:1518–25.
3. Camm AJ, Lip GY, De Caterina R, Savelieva I, Atar D, Hohnloser SH *et al.* 2012 focused update of the ESC Guidelines for the management of atrial fibrillation: an update of the 2010 ESC Guidelines for the management of atrial fibrillation—developed with the special contribution of the European Heart Rhythm Association. *Europace* 2012;**14**:1385–413.