

A right-sided subcutaneous implantable cardioverter defibrillator in a patient with congenital heart disease

James R. Waller, Antony P. Salmon, and Paul R. Roberts*

Department of Cardiology, University Hospital Southampton NHS Foundation Trust, Tremona Road, Southampton, Hampshire, SO16 6YD, UK

* Corresponding author. E-mail address: paul.roberts@uhs.nhs.uk

A young woman with congenital heart disease including dextrocardia presented to us following an out-of-hospital ventricular fibrillation (VF) arrest. She had a dual-chamber pacemaker inserted already for bradycardia. There were concerns over the risk of baffle occlusion due to multiple transvenous wires. She received an entirely right-sided subcutaneous implantable cardioverter-defibrillator with successful defibrillation tests.

Sudden cardiac death is the leading cause of mortality in adults with complex congenital heart disease, and since the 1980s implantable cardioverter-defibrillators (ICDs) have been available to treat malignant arrhythmias.¹

A 31 years old woman with complex congenital heart disease including transposition of the great arteries situs inversus with dextrocardia and a Mustard procedure aged 18 months presented with an out-of-hospital VF arrest. She sustained a hypoxic brain injury and her mobility was reduced to a few hundred yards with a frame due to myoclonus. In 2009 she had a transvenous dual chamber permanent pacemaker (PPM) implanted due to bradycardia-induced syncope but the atrial lead was failing to capture and a new atrial lead was implanted transvenously.

There was concern about the further implantation of transvenous wires and the associated risk of baffle occlusion and superior vena cava obstruction, well recognized complications of both the Mustard procedure and of transvenous pacing wires in this patient group.² The risks of pacemaker lead extraction and implantation of an endocardial ICD were considered. After discussion with the patient she received a subcutaneous ICD (S-ICD; Boston Scientific, Model SQRX) but contrary to routine practice we implanted this entirely on the right side. Conventionally, for the lowest mean defibrillation threshold, the recommendations are to site the pulse generator in the fifth to sixth intercostal space, mid-axillary line on the left side and tunnel a wire with two sensing electrodes separated by a defibrillation coil medially to the xiphisternum where it is secured with sutures and then tunnelled cranially parallel to the sternum 1–2 cm to the left. The device allows for three possible sensing vectors.¹

In our patient the pulse generator was implanted on the right side with the electrode tunnelled cranially to the right of the mediastinum to ensure the maximum cardiac mass between the shock vectors. Defibrillation tests were performed successfully. The use of subcutaneous devices in patients with transposition of the great arteries with a Mustard procedure and a transvenous PPM have been described.³ We are not aware of any cases of an entirely right-sided system.

Conflict of interest: none declared.

References

1. Peters B, Will A, Berger F, Butter C. Implantation of a fully subcutaneous ICD in a patient with single ventricle morphology and Eisenmenger physiology. *Acta Cardiologica* 2012;**67**: 473–5.
2. Patel S, Shah D, Chintala K, Karpawich PP. Atrial baffle problems following the Mustard Operation in Children and Young Adults with dextro-transposition of the Great Arteries: the need for improved clinical detection in the current era. *Congenit Heart Dis* 2011;**6**:466–74.
3. Kowalski M, Nicolato P, Kalahasty G, Kasirajan V, Wood MA, Ellenbogen KA et al. An alternative technique of implanting a nontransvenous implantable cardioverter-defibrillator system in adults with no or limited venous access to the heart. *Heart Rhythm* 2010;**7**:1572–7.

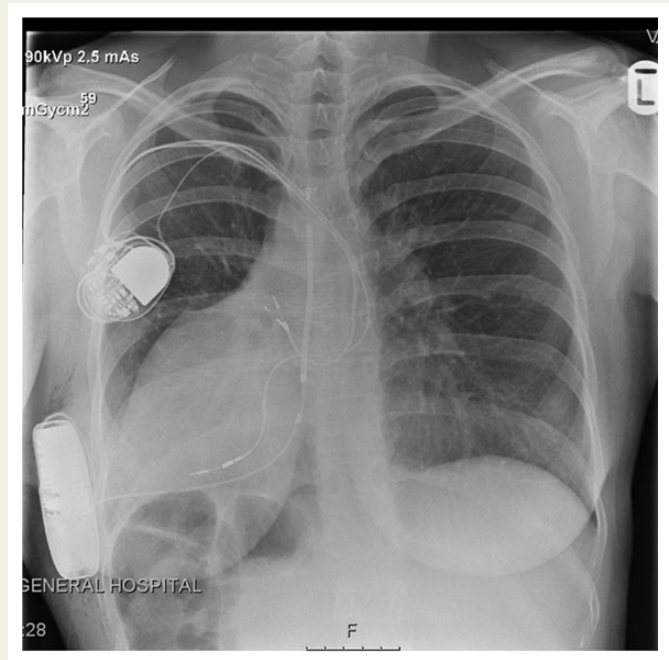


Figure 1 Chest radiograph showing dextrocardia and situs inversus with a right-sided S-ICD and dual chamber pacemaker.