

Therapeutic moderate hypothermia: a novel modality for management of electrical storm due to ventricular fibrillation

Aysha Arshad*, Jonathan S. Steinberg, and Suneet Mittal

Arrhythmia Institute, Valley Health System, 223 N Van Dien Avenue, Ridgewood, NJ 07450, USA

* Corresponding author. Tel: +1 212 432 7837; fax: +1 201 432 7830. E-mail address: arshay@valleyhealth.com

Electrical storm (ES) due to ventricular tachycardia/fibrillation is a known complication of acute coronary syndrome. Strategies for management include coronary revascularization, β -blockade, antiarrhythmic drug therapy, thoracic epidural anaesthesia, sympathetic denervation, general anaesthesia, and catheter ablation. We describe a patient in whom these therapies failed; therapeutic hypothermia ultimately successfully controlled ES obviating urgent catheter ablation.

Case presentation

A 65-year-old male with hypertension, diabetes, and hypercholesterolaemia with post-infarction ischaemic heart disease and prior hybrid myocardial revascularization [left internal mammary graft to left anterior descending (LAD) and diagonal arteries; stents to LAD and left circumflex (LCx) arteries] presented to the emergency room with flank pain. The initial electrocardiogram was unchanged from prior; he then developed angina and new anterior ST-segment elevations. While awaiting transportation to the catheterization laboratory, he had an episode of polymorphic ventricular tachycardia (PMVT), which degenerated into ventricular fibrillation (VF). The patient was defibrillated and angiography showed a subtotal occlusion of proximal LAD, thrombus within the proximal LCx, and total occlusion of the distal LCx. Balloon angioplasty restored TIMI II flow to the circumflex, then LAD arteries. During the procedure, the patient had an additional 38 episodes of PMVT and VF; each was successfully defibrillated. During this period, intubation, β -blockade, lidocaine, repeated boluses of amiodarone and then procainamide, overdrive temporary transvenous ventricular pacing, and an intra-aortic balloon pump all failed to suppress PMVT and VF. Ventricular ectopy of varying morphologies initiated each episode of PMVT. Thoracic spinal anaesthesia was considered; however, it was considered high risk given the recent administration of bivalirudin. Thus, a decision was made to institute therapeutic hypothermia. A triple lumen Alsius Icy catheter was placed via a femoral vein and connected to the Thermogard XP™ cooling unit. A target temperature of 33°C was maintained over the next 24 h. Within 1 h of initiation of hypothermia, all ventricular arrhythmias ceased (Figure 1), obviating the need for urgent catheter ablation. Lidocaine was discontinued 36 h after presentation and amiodarone was discontinued

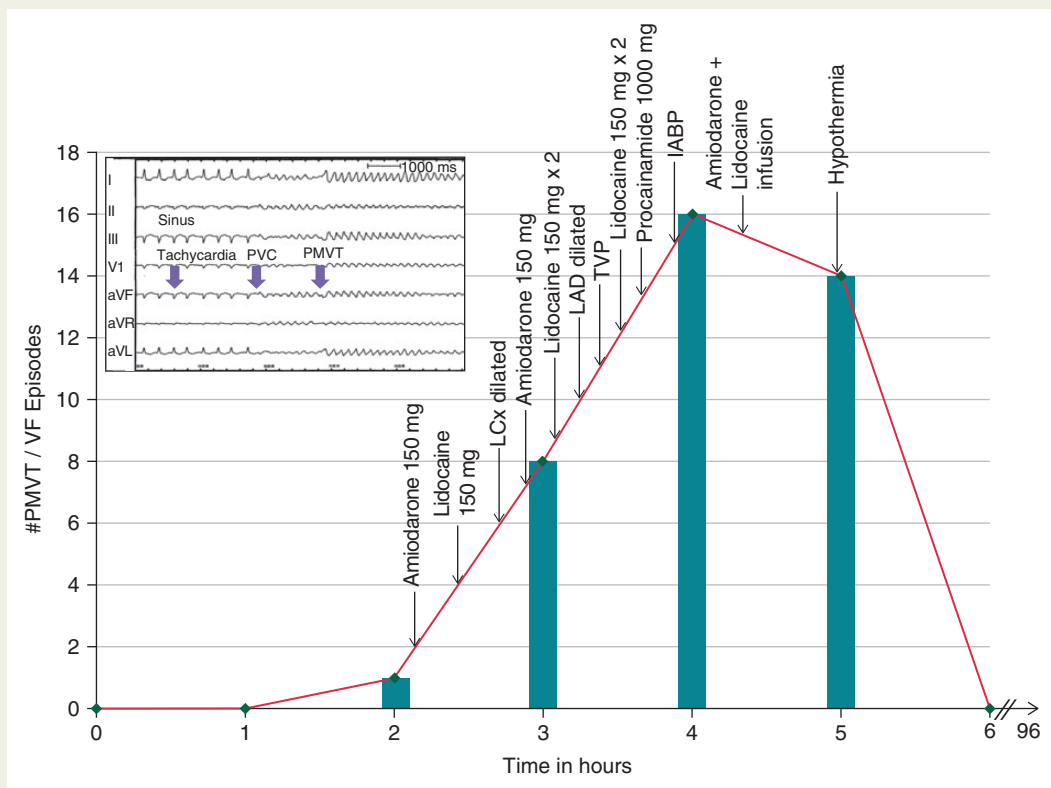


Figure 1 Effect of interventions on the incidence of ventricular tachycardia.

tinued 96 h after presentation. The patient made a complete neurological recovery. Repeat echocardiography showed persistent left ventricular dysfunction; revascularization was incomplete and so a single-chamber implantable cardioverter defibrillator (ICD) was implanted before discharge. During follow-up, the patient had a single asymptomatic episode of sustained monomorphic VT at 200 b.p.m. that was successfully pace terminated 4 months post-ICD implantation.

Electrical storm (ES) describes a period of severe cardiac electrical instability, which is manifest by recurrent malignant ventricular arrhythmias.¹ Several mechanisms may underlie the protective effects of hypothermia including heart rate reduction, mitigation of ischaemic reperfusion injury, and alteration in the electrophysiological properties of the heart.^{2,3} Irrespective, ES is associated with high mortality.

In our patient there was a dramatic cessation of ventricular arrhythmias 1 h after institution of hypothermia, which obviated the need for emergent catheter ablation. Institution of therapeutic hypothermia in ES may provide an option in the armamentarium of strategies to acutely stabilize ventricular arrhythmias and may be very important in settings where catheter ablation is not immediately available.

Conflict of interest: none declared.

References

1. Nademanee K, Taylor R, Bailey WE, Rieders DE, Kosar EM. Treating electrical storm : sympathetic blockade versus advanced cardiac life support-guided therapy. *Circulation* 2000;**102**:742–7.
2. Polderman KH. Mechanisms of action, physiological effects, and complications of hypothermia. *Crit Care Med* 2009;**37**:S186–202.
3. Boddicker KA, Zhang Y, Zimmerman MB, Davies LR, Kerber RE. Hypothermia improves defibrillation success and resuscitation outcomes from ventricular fibrillation. *Circulation* 2005;**111**:3195–201.