

Speech-triggered atrial tachycardia originating from the superior vena cava

Akira Ueno*, Norishige Morita, and Yoshinori Kobayashi

Division of Cardiology, Department of Medicine, Tokai University Hachioji Hospital, 1838 Ishikawa-machi, Hachioji-shi, Tokyo 1920032, Japan

* Corresponding author. Tel: +81 42 639 1111; fax: +81 42 639 1144. E-mail address: s4013@nms.ac.jp

An incessant form of atrial tachycardia originating from the superior vena cava, which could be reproducibly induced by starting to speak and terminated after cessation of the conversation, was successfully ablated.

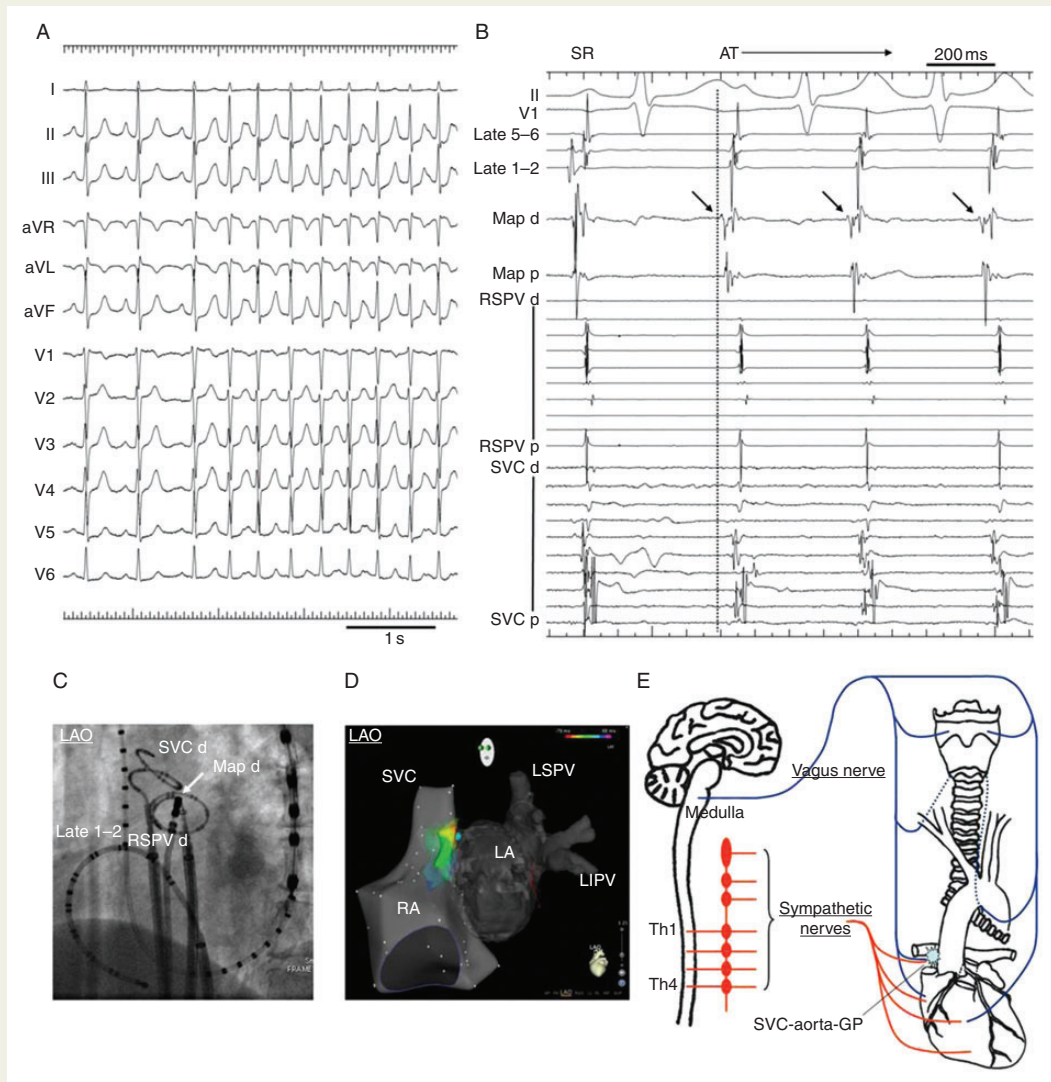


Figure 1 (A) Twelve-lead electrocardiogram showing a sustained AT during conversation. The P wave morphology of the AT was positive in Leads I, II and aVF, and biphasic in Lead V1. (B) Surface and intracardiac electrograms of an AT. A low-amplitude fragmented potential (black arrows) with the earliest atrial activation preceding the onset of the P wave in Lead II by 50 ms during the AT recorded by a mapping catheter located on the septal side of the SVC. (C) Cine capture image showing the position of the mapping catheter (white arrow) and the other diagnostic catheters. (D) Electroanatomically guided isochronal mapping revealing the earliest activation site with a centrifugal activation pattern. The blue tag represented the site where the AT became no longer inducible when the ablation catheter was placed. (E) A schematic illustration of the anatomical relationship between the pharyngolaryngeal system, vagus nerve and cardiac autonomic nervous system. AT, atrial tachycardia; d, distal electrode pair; GP, ganglionated plexi; LA, left atrium; Late, lateral side of the superior vena cava; LIPV, left inferior pulmonary vein; LSPV, left superior pulmonary vein; Map, mapping catheter; p, proximal electrode pair; RA, right atrium; RSPV, right superior pulmonary vein; SR, sinus rhythm; SVC, superior vena cava; and Th, thoracic vertebrae.

A previously healthy 63-year-old male was referred to our institute due to frequent episodes of palpitations during conversation. He had retired as an office worker 4 years prior and had no occupational use of his voice. His echocardiogram and chest computed tomography were normal. An incessant form of atrial tachycardia (AT) triggered by premature atrial complexes could be reproducibly induced by starting to speak, and terminated over time after cessation of the conversation (Figure 1A and Supplementary material online, video). Deep breaths, deglutition, coughing, exercise testing, and the intravenous administration of isoproterenol could not provoke the AT. An electrophysiological study was performed in the non-sedated state. Two duodecapolar circular mapping catheters were positioned in the superior vena cava (SVC) and right superior pulmonary vein (RSPV), respectively, and their catheter positions were confirmed by the selective angiography of the SVC. A short duration AT was reproducibly induced by a single word verbal reply to a brief question and could easily be mapped. The cycle length of the AT varied between 260 and 500 ms. Three-dimensional electroanatomical mapping (Biosense Webster) revealed that the earliest focal activation site of the AT was on the septal side of the SVC (Figure 1B–D). When the ablation catheter was placed at that site as indicated by the blue tag in Figure 1D, the AT became no longer inducible even by speech manoeuvres, and then radiofrequency energy (25W, 30 s) was applied at that site. Four additional ablation applications were applied to the neighbouring area just around the initial target site, and the ablation session was ended. After 1 year of follow-up, he has been free of any palpitations during conversations, and several 24 h Holter recordings revealed no ATs at all.

Two successful ablation cases of speech-triggered AT have been previously described with a focal arrhythmogenic origin (the roof of the left atrium and ostium of the RSPV), where left atrial ganglionated plexi (GP) are known to exist nearby. The cooperative activation of the vagal and adrenergic elements has been shown to induce triggered activity and subsequent atrial arrhythmogenic foci by the abbreviation of the local action potential duration and increased intracellular calcium transient currents via the GPs, particularly in vagally mediated ones. More recently, Zucchelli *et al.* also reported a case of vocalization-triggered AT, and referred to the difficulty in understanding its mechanism due to the complexity of the human speech system.¹ As seen in the Supplementary material online, video, an AT appeared immediately before commencing speech and was sustained during conversation. In addition, the AT ceased when the speech became short or terminated. Therefore, this finding suggests that central modulation acting on the pharyngeal muscles via the vagus nerve also stimulates the SVC-aorta-GP, which is reported to exist near the tachycardia focus, and is simultaneously influenced by the discharge of the sympathetic nervous system by the initiation of speech (Figure 1E). These inputs may collaboratively promote the formation of abnormal triggered activity,² and subsequently lead to an occurrence of speech-triggered AT as this postulated mechanism.³

Supplementary material

Supplementary material is available at *Europace* online.

Conflict of interest: All authors have no financial support or grant associated with this research and no conflict of interest.

References

1. Zucchelli G, Coluccia G, Di Cori A, Soldati E, Bongiorni MG. Silence is golden: an uncommon case of vocalization-triggered atrial tachycardia. *Can J Cardiol* 2014;**30**:247 e3–6.
2. Lu Z, Scherlag BJ, Niu G, Lin J, Fung KM, Zhao L *et al.* Functional properties of the superior vena cava (SVC)-aorta ganglionated plexus: evidence suggesting an autonomic basis for rapid SVC firing. *J Cardiovasc Electrophysiol* 2010;**21**:1392–9.
3. Tan AY, Zhou S, Ogawa M, Song J, Chu M, Li H *et al.* Neural mechanisms of paroxysmal atrial fibrillation and paroxysmal atrial tachycardia in ambulatory canines. *Circulation* 2008;**118**:916–25.