

## Accurate evaluation of para-Hisian pacing in a patient with fasciculoventricular bypass

Rintaro Hojo<sup>1\*</sup>, Seiji Fukamizu<sup>1</sup>, and Harumizu Sakurada<sup>2</sup>

<sup>1</sup>Department of Cardiology, Tokyo Metropolitan Hiroo Hospital, 2-34-10, Ebisu, Shibuya-ku, Tokyo 150-0013, Japan and

<sup>2</sup>Tokyo Metropolitan Health and Medical Treatment Corporation, Ohkubo Hospital, Tokyo 160-8488, Japan

\* Corresponding author. Tel: +81 33 444 1181; fax: +81 33 444 3196. E-mail address: rinrintaro1979@hotmail.co.jp

A 20-year-old man with palpitations was examined for ventricular pre-excitation. Atrial extra-stimulation produced AH prolongation without changes in the pre-excitation degree, suggesting fasciculoventricular bypass. Para-Hisian pacing with different stimuli strengths induced various beats, including His-bundle pacing. QRS morphologies of these different responses were similar because the distal connection of the fasciculoventricular bypass was located adjacent to the para-Hisian area.

A 20-year-old man with palpitations was referred to our hospital for evaluation of ventricular pre-excitation. The QRS morphology of his 12-lead electrocardiogram suggested the presence of a superoparaseptal accessory pathway. Atrial extra-stimulations produced AH prolongation without changes in both the HV interval and the degree of pre-excitation, which was inconsistent with atrioventricular (AV) and atriofascicular bypass, suggesting the presence of a fasciculoventricular bypass tract (Figure 1A). We attempted to reproduce His-bundle pacing at the para-Hisian area to provoke an identical degree of pre-excitation. Para-Hisian pacing with different stimuli strengths yielded two similar QRS morphologies. The low output (1 mA, 2 ms) stimulation captured only local ventricular myocardium (Vc) (Figure 1B). The high output (2 mA, 2 ms) pacing captured both the His bundle and Vc (H + Vc) (Figure 1C). This indicated that the stimulus–right ventricular apex (RVA) interval was shorter for H + Vc than for Vc, whereas the QRS morphology was identical to Vc. The high output (2 mA, 2 ms) pacing also captured only the His bundle (Hc) (Figure 1D). At this time, the stimulus–RVA interval of the beat was identical to that of H + Vc, but the stimulus–local electrogram interval was longer than for H + Vc. The QRS morphology of the captured His beat (Figure 1D) was identical to that in sinus rhythm (Figure 1F). After isoproterenol infusion (1 µg/min), accelerated junctional rhythm became dominant. The QRS morphology and HV interval of junctional rhythm (Figure 1E) were identical to those in sinus rhythm. During atrial pacing, bolus injection of adenosine triphosphate (20 mg) provoked a junctional rhythm after the AV block occurred; the junctional beats had similar properties to those in sinus rhythm.

### Discussion

Fasciculoventricular pathways are accessory connections that originate from the bundle of His or fascicles that enter directly into the ventricular myocardium. Their incidences range from 1.2 to 1.8% in patients with pre-excitation.<sup>1–3</sup> Although fasciculoventricular bypass is not the basis of any reentrant tachycardia, its differentiation from the superoparaseptal bypass is important. The typical findings of a fasciculoventricular connection include (i) prolongation of the AH interval without changes in the HV interval, (ii) a constant degree of pre-excitation, and (iii) His-bundle pacing that elicits an identical QRS as in sinus rhythm.<sup>3</sup>

In patients with fasciculoventricular bypass tract, therefore, accurate and stable His-bundle pacing is mandatory for correct diagnosis. In the present study, we could obtain a response of local para-Hisian Vc, from both H + Vc, or only Hc. The QRS morphologies of these different responses were similar because the distal connection of the fasciculoventricular bypass is located adjacent to the para-Hisian area (Figure 1H), except in rare cases of left connection. Local intracardiac electrogram data could provide a clue for accurate evaluation of para-Hisian pacing. Furthermore, if a reliable 'pure' Hisian pacing cannot be established, we could induce a junctional beat by application of isoproterenol or adenosine triphosphate to confirm the diagnosis, not only in a catheterization laboratory, but also at a bedside.<sup>3</sup>

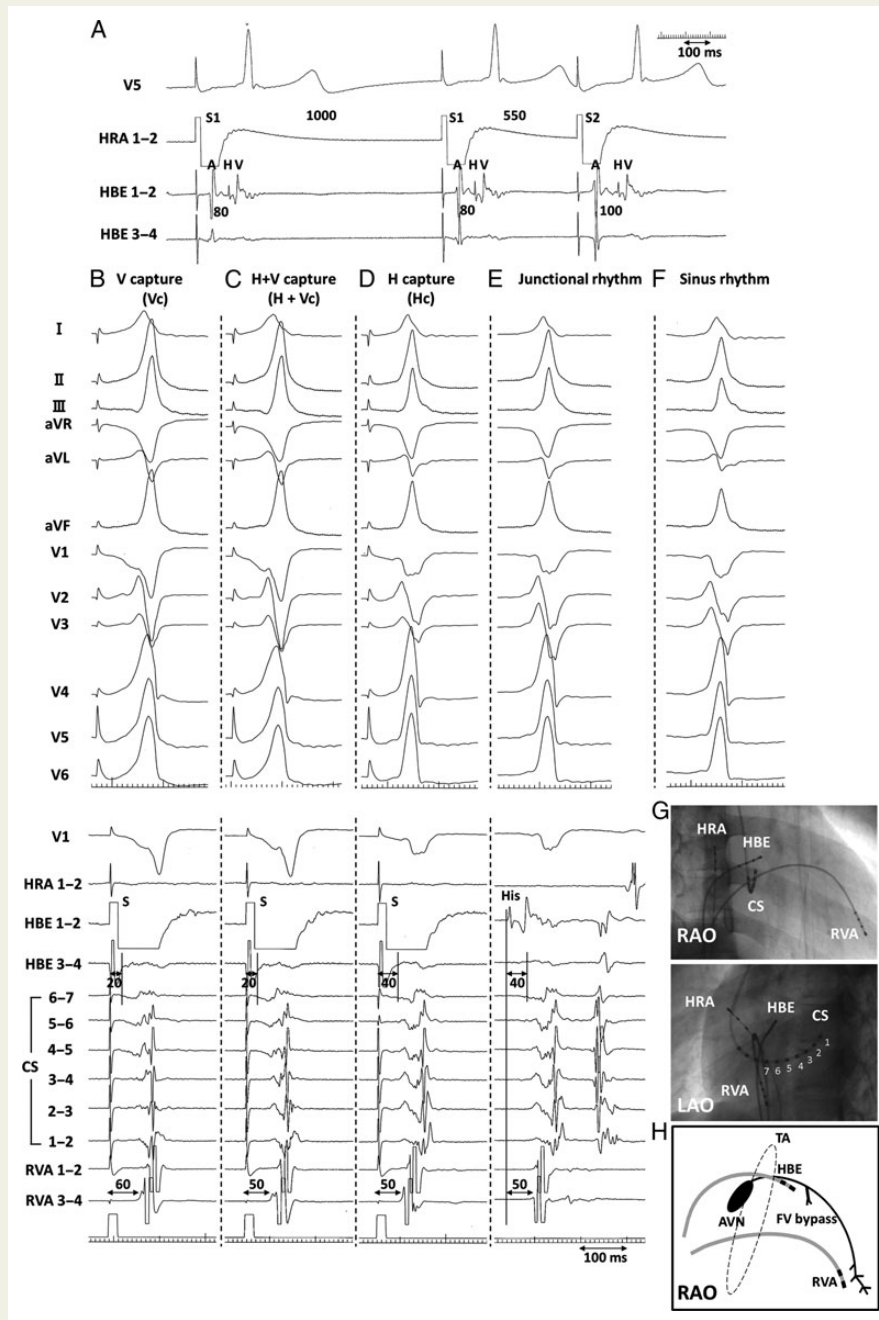
### Acknowledgements

The authors would like to acknowledge the assistance of Masayasu Hiraoka, MD, PhD, FAHA, FHRS of the Toride Kitasohma Medical Center Hospital in Ibaraki, Japan.

**Conflict of interest:** none declared.

### References

1. Gallagher JJ, Smith WK, Kasell JH, Benson DW, Sterba R, Grant AO. Role of Mahaim fibers in cardiac arrhythmias in man. *Circulation* 1981;**64**:176–89.
2. Kottkamp H, Hindricks G, Shenasa H, Chen X, Wichter T, Borggrefe M. Variants of preexcitation-specialized atriofascicular pathway, nodofascicular pathway, fasciculoventricular pathway: electrophysiologic findings and target sites for radiofrequency catheter ablation. *J Cardiovasc Electrophysiol* 1996;**7**:916–30.
3. Sternick E, Gerken L, Vrandečić M, Wellens H. Fasciculoventricular pathway: clinical and electrophysiologic characteristics of a variant of preexcitation. *J Cardiovasc Electrophysiol* 2003;**14**:1057–63.



**Figure 1** (A) Intracardiac electrogram during atrial stimulus testing. Atrial extra-stimulations at basic cycle length 1000 ms and S1–S2 interval 550 ms produced AH prolongation without changes in both the HV interval and the degree of pre-excitation, suggesting the presence of a fasciculoventricular bypass tract. (B–F) Twelve-lead electrocardiogram and intracardiac electrogram recordings during pacing from para-Hisian region illustrate the maximum amplitude of His pacing. (B) The low output (1 mA, 2 ms) stimulation captured only local ventricular myocardium (Vc) (C) The higher output (2 mA, 2 ms) pacing captured the His bundle and local ventricular myocardium (H + Vc). The stimulus–RVA interval was shorter than that of Vc. The QRS morphology was identical to Vc. (D) The higher output pacing captured only the His bundle (Hc). The QRS morphology was identical to sinus rhythm. (E) The junctional beats promoted by isoproterenol infusion showed the same degree of pre-excitation, as in sinus rhythm. In intracardiac electrogram, the activation sequence was identical to that of Hc. We substituted the ventricular wave recorded at the electrode proximal to CS (CS7–8) for the ventricular wave at the para-Hisian area because the ventricular electrogram of the para-Hisian area was unclear. (F) The QRS morphology of sinus rhythm. (G) The electrodes positions showed the electrode proximal to the right atrium. (H) The schema showed the positional relationship between FV bypass and the electrodes. HRA, high right atrium; HBE, His-bundle electrogram; CS, coronary sinus; RVA, right ventricular apex; TA, tricuspid annulus; AVN, atrioventricular node; FV, fasciculoventricular.