

Protective effect of nebivolol on anthracycline-induced cardiotoxicity, assessed by tissue doppler velocities and by speckle tracking echocardiography

Prof Dr Mirela Cleopatra Tomescu
"V. Babeş" University of Medicine and
Pharmacy Timișoara, Romania

Disclosures: None.

Background

- **Breast cancer is a major public health problem worldwide, with a death rate of about 1 in 33 .**
- **Anthracyclines are a class of powerful pharmacological agents widely used in the treatment of breast cancer.**
- **One of their main limitations is their toxic effect on the heart, inducing heart failure.**

Declaration of Interest

- **Nothing to declare**

Purpose and key points about methods

Goals of the study

- **To find a method that accurately and early detects cardiotoxicity**
- **To see if a cardioprotective drug (Nebivolol) may prevent heart failure in these patients.**

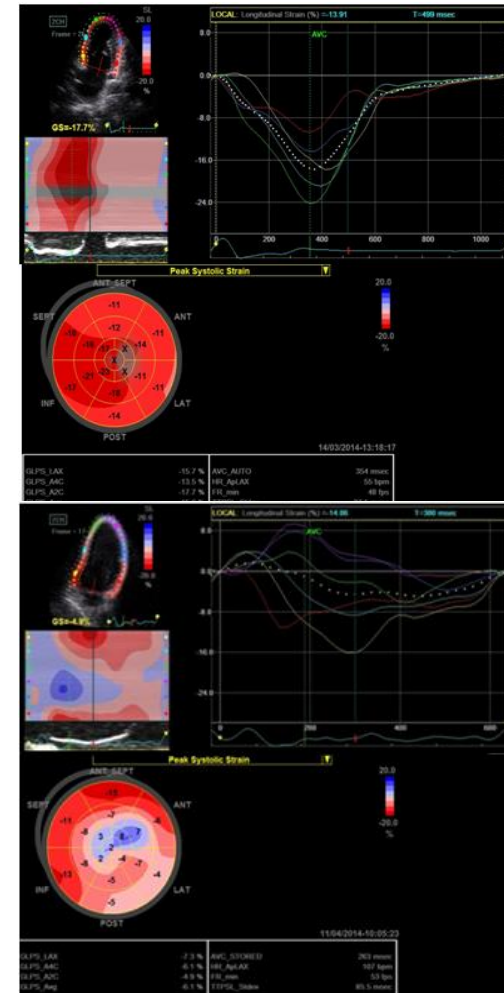
Patients and methods

- **The study group included 60 women with HER-2 negative breast cancer, with a mean age of 52 ± 13 years, scheduled to start chemotherapy with doxorubicin.**
- **They were randomly divided into two groups, the control group (n=30) and the nebivolol-treatment group (n=30).**
 - Nebivolol was administered at a dose of 5 mg once daily, for the duration of chemotherapy.
 - Cytostatic treatment was performed with doxorubicin, in 6 cycles at intervals of 21 days. The average cumulative dose of doxorubicin was 520 ± 8 mg / m².
- **Echocardiography was performed at baseline and after six months of chemotherapy and included: conventionally two-dimensional (2D), tissue Doppler imaging (TDI) and speckle tracking imaging (STI).**

Results

After six cycles of chemotherapy with doxorubicin:

- The classical echocardiographic parameters of LV systolic function (LVEF, FS, and diameters) did not change significantly.
- Tissue Doppler imaging revealed in the control (without cardioprotection) group significant alterations of the LV diastolic function, assessed by a decrease of myocardial velocities.
- Speckle-tracking imaging assessed in the same group a statistically a significant alteration of the LV systolic function, demonstrated by a decrease of longitudinal ($p = 0.04$) and radial ($p = 0.03$) strains, as well as of the strain rates ($p = 0.02$).
- In the nebivolol treatment group, no significant changes in the heart function were noted.



Longitudinal strain before and after six cycles of chemotherapy in the control group

Speaker

Conclusions

- **The results of this study demonstrate the utility of new echocardiographic methods such as tissue Doppler and speckle tracking imaging in the early detection of ventricular dysfunction induced by cytostatic treatment.**
- **Nebivolol treatment prevented the occurrence of anthracycline- induced cardiotoxicity.**
- **Larger studies with a longer follow-up period are needed to confirm these preliminary results.**