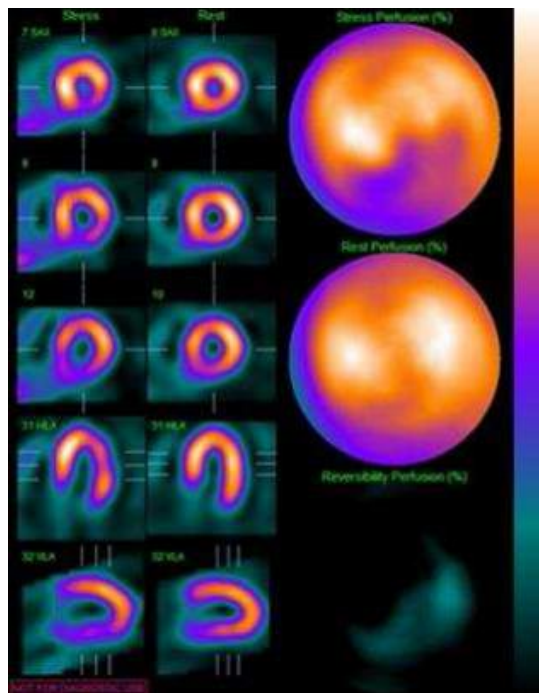




## SAMPLE QUESTION

A 61-year-old man presented 30 minutes after an episode of chest pain at rest that lasted 15 minutes and that settled shortly after taking an aspirin tablet. Coronary angiography showed a complex lesion of the mid right coronary artery, which was successfully stented, and there was also proximal left anterior descending disease of uncertain significance. Myocardial perfusion imaging was performed two days later.



Which is the best interpretation of the study?

- A. The images cannot be interpreted so soon after coronary stenting
- B. The LAD lesion is not haemodynamically significant
- C. There is a circumflex marginal branch occlusion that may not have been apparent from the angiogram
- D. There is inadequate revascularisation of the right coronary territory
- E. There is infarction of the right coronary territory

ANSWER: Option B