REPORT OF THE ESC-EAPCI TASK FORCE ON THE EVALUATION AND USE OF BIORESORBABLE SCAFFOLDS FOR PERCUTANEOUS CORONARY INTERVENTION

Task Force Members:

Robert A. Byrne (DE), Giulio G. Stefanini (IT), Davide Capodanno (IT), Yoshinobu Onuma (NL), Andreas Baumbach (UK), Javier Escaned (ES), Michael Haude (DE), Stefan James (SE), Michael Joner (DE), Peter Jüni (CH), Adnan Kastrati (DE), Semih Oktay (USA), William Wijns (IE), Patrick W. Serruys (NL), Stephan Windecker (CH)

ESC Document Reviewers:

Alan G. Fraser (UK), Peter Kearney (IE), Piotr Szymanski (PL)

30 APRIL 2017

Table of Contents

GLOSSARY OF TERMS USED IN TEXT **4**

ACRONYMS OF RANDOMIZED CLINICAL TRIALS INVESTIGATING BIORESORBABLE SCAFFOLDS **6**

PREAMBLE **7**

Task Force Members and Constitution 8

1. INTRODUCTION AND NOMENCLATURE **10**

Introduction 10
Nomenclature 10

2. UNMET NEEDS OF CURRENT METALLIC DES **11**

Very late stent thrombosis and restenosis 12
Implications of removal of permanent implant 13

3. MATERIAL COMPOSITION, PLATFORM DESIGN AND DEVICE OVERVIEW **16**

Mechanical properties of bioresorbable scaffolds 16
Key features of currently-approved bioresorbable scaffolds 19

4. CLINICAL OUTCOMES WITH CE-APPROVED BIORESORBABLE SCAFFOLDS **21**

1. ABSORB bioresorbable scaffold 21
2. DESolve bioresorbable scaffold 28
3. Magmaris bioresorbable magnesium scaffold 29
4. ART 29

5. IMPORTANT CLINICAL SUBGROUPS **41**

Small vessels 41
Acute coronary syndromes 42
Chronic total occlusions 44
Diffuse disease 44
Bifurcations 45
Diabetes 46

6. ANGIOGRAPHIC OUTCOMES WITH CE-APPROVED BIORESORBABLE SCAFFOLDS **47**

1. Absorb 47
2. DESolve 48
3. Magmaris 48

7. INTRACORONARY IMAGING RESULTS WITH CE-APPROVED BIORESORBABLE SCAFFOLDS **50**

Absorb 50
DESsolve 52
Magmaris 52

8. RECOMMENDATION FOR DUAL ANTIPLATELET THERAPY IN PATIENTS TREATED WITH BRS **54**

9. RECOMMENDATIONS FOR CURRENT CLINICAL USE **56**

Indications 56
General recommendations for clinical use of approved devices 56
Device implantation 57

Lesion Assessment 57
Pre-dilation 58
Implantation Technique 58
Post-Dilatation 59
Device Failure 59

10. RECOMMENDATIONS FOR EVALUATION PLAN FOR BIORESORBABLE SCAFFOLDS 59

Bench Testing 60
Biocompatibility 61
In Vivo Testing 62
Animal models 62
Porcine/Rabbit Models 62
Planning and conducting preclinical studies in animals 63
Standards for evaluation 64

11. CLINICAL EVALUATION PLAN 68

REFERENCES 72

SUPPLEMENTARY APPENDIX 87

Glossary of terms used in text

ACS = acute coronary syndrome

AUC = area under curve

BMS = bare metal stent

BRS = bioresorbable scaffold, further classified as pBRS (polymeric BRS) and mBRS (metallic BRS)

CI = confidence interval

DAPT = dual antiplatelet therapy

DES = drug-eluting stent

EAPCI = European Association of Percutaneous Cardiovascular Interventions

EES = everolimus-eluting stents

ESC = European Society of Cardiology

CIE = Clinical Investigation and Evaluation Working Group of the Medical Device Experts Group

HR = hazard ratio

IVUS = intravascular ultrasound

JRC = Joint Research Centre (JRC) – the scientific advisory service of the European Commission

MDEG = Medical Device Experts Group

MI = myocardial infarction

MW = Molecular weight

OCT = optical coherence tomography

OPC = objective performance criteria

OR = odds ratio

PCI = percutaneous coronary intervention

PDI = molecular weight distribution

PLA = poly- lactic acid, further classified as poly-L-lactic acid (PLLA) and poly-D, L-lactic acid (PDLLA)

POCE = patient-oriented composite endpoint

QCA = quantitative coronary angiography

RVD = reference vessel diameter

ST/ScT = stent/scaffold thrombosis

STEMI = ST-segment elevation myocardial infarction

T_g = Glass transition temperature

T_m = Melting temperature

TLF = target lesion failure

TLR = target lesion revascularization

TVR = target vessel revascularization

χ_c = Percent crystallinity

Acronyms of randomized clinical trials investigating bioresorbable scaffolds

ABSORB II: A Clinical Evaluation to Compare the Safety, Efficacy and Performance of ABSORB Everolimus Eluting Bioresorbable Vascular Scaffold System Against XIENCE Everolimus Eluting Coronary Stent System in the Treatment of Subjects With Ischemic Heart Disease Caused by de Novo Native Coronary Artery Lesions

ABSORB III: A Clinical Evaluation of Absorb™ BVS, the Everolimus Eluting Bioresorbable Vascular Scaffold in the Treatment of Subjects With de Novo Native Coronary Artery Lesions

ABSORB China: A Clinical Evaluation of Absorb™ Bioresorbable Vascular Scaffold (Absorb™ BVS) System in Chinese Population

ABSORB Japan: A Clinical Evaluation of AVJ-301 (Absorb™ BVS), the Everolimus Eluting Bioresorbable Vascular Scaffold in the Treatment of Subjects With de Novo Native Coronary Artery Lesions in Japanese Population

AIDA: Amsterdam Investigator-initiateD Absorb strategy all-comers trial

EVERBIO II: Comparison of Everolimus- and Biolimus-Eluting Stents With Everolimus-Eluting Bioresorbable Vascular Scaffold

TROFI II: Comparison of the ABSORB™ Everolimus Eluting Bioresorbable Vascular Scaffold System With a Drug- Eluting Metal Stent (Xience™) in Acute ST-Elevation Myocardial Infarction

PREAMBLE

The European Society of Cardiology (ESC) was asked in 2013 by the Clinical Investigation and Evaluation (CIE) Working Group of the Medical Device Experts Group (MDEG, standing committee) of the European Commission to provide recommendations for a revision of the EU medical device advisory document on the evaluation of coronary stents (MEDDEV 2.7.1., Appendix 1) – the only European device-specific advisory document in existence at present. This document provides guidance, which aims to ensure uniform application of evaluation standards across Europe.

The ESC EU Regulatory Affairs Committee on Medical Devices delegated the task to the European Association of Percutaneous Cardiovascular Interventions (EAPCI) with the request to establish an expert advisory group in the field of percutaneous coronary intervention with specific expertise in the evaluation of coronary artery stents. It was the mission of this ESC-EAPCI Task Force to ensure the priority of patient safety and to protect patients from exposure to incompletely evaluated devices or devices with incomplete evidence of benefit while preserving expeditious access to innovative and novel devices that will improve patient care through better outcomes.

The ESC-EAPCI Task Force presented its report to the European Commission in July 2014 and an executive summary of this report has been published in the peer-reviewed literature in 2015.[1] Following dialogue between the Joint Research Centre (JRC) – the scientific advisory service of the European Commission – and the Task Force in 2016, the Task Force was asked to prepare an additional report on the class of devices known as bioresorbable scaffolds (BRS). This current report and the previous one will now together provide the evidence that will be used by a task

force of regulators drawn from the national competent authorities in Europe as the basis for their redrafting of EU guidance to manufacturers and notified bodies on the preclinical and clinical evaluation of coronary stents.

Task Force Members and Constitution

ESC-EAPCI Task Force members: Andreas Baumbach (UK), Robert A. Byrne (DE), Davide Capodanno (IT), Javier Escaned (ES), Stefan James (SE), Michael Haude (DE), Michael Joner (DE), Peter Jüni (CH), Adnan Kastrati (DE), Semih Oktay (USA), Yoshinobu Onuma (NL), Patrick Serruys (NL), Giulio G. Stefanini (IT), William Wijns (IE), and Stephan Windecker (CH).

The representation of scientific societies and expertise within the ESC-EAPCI task force is summarized as follows:

- EAPCI representatives (Michael Haude – President; Stephan Windecker – Past President; Andreas Baumbach – President Elect; Javier Escaned – Past Treasurer; Robert Byrne – Chair, Scientific Documents and Initiatives Committee; Davide Capodanno – Co-Chair, Scientific Documents and Initiatives Committee)
- EuroPCR representative (William Wijns, Chairman)
- ESC Clinical Practice Guidelines Committee (Stephan Windecker)
- ESC Advocacy Committee and EU Regulatory Affairs Sub-Committee (Robert Byrne, Stefan James)
- ESC-EACTS Task Force on Myocardial Revascularisation (Stephan Windecker - Co-Chairman, Members Adnan Kastrati, Giulio Stefanini, Peter Jüni, William Wijns – past Co-chairman)
- Academic Research Consortium (Patrick Serruys – Chairman)

- European Heart Journal/EuroIntervention representatives (William Wijns - Associate Editor European Heart Journal, Patrick Serruys – Editor-in-Chief EuroIntervention)
- CardioMed Device Consultants, former United States Food and Drug Administration (FDA) reviewer (Semih Oktay)

Decision making within this Task Force was based on unanimity for explicit recommendations. The experts of the writing and reviewing panels completed declarations of interest forms on what might be perceived as real or potential sources of conflicts of interest. These forms were compiled into one file and can be found on the ESC website (http://www.escardio.org/The-ESC/Communities/European-Association-of-Percutaneous-Cardiovascular-Interventions-EAPCI/Publications/EAPCI-scientific-documents/Scientific-documents). The Task Force received its entire financial support from the ESC and EAPCI without any involvement from the healthcare industry. Notwithstanding, the ESC-EAPCI Task Force acknowledges intrinsic relations of interest as a direct result of the professional activities of its members as practitioners, researchers and advisors. For this reason, the document has also been reviewed and approved after amendments, by members of the Regulatory Affairs Committee of the ESC who do not have any relevant disclosures of interest.

There follows the report of this Task Force. It includes recommendations concerning the clinical use of BRS, as well as recommendations for preclinical and clinical evaluation before approval of these devices.

1. INTRODUCTION AND NOMENCLATURE

Introduction

During the last decade, the introduction of new generation conventional metallic drug-eluting stents (DES) – characterized by thinner stent struts, novel polymer coatings, and antiproliferative drugs – has improved the safety and efficacy profile of coronary stents in comparison with both early generation DES as well as uncoated bare metal stents (BMS).[1-4] Based on available evidence, new generation DES represent the current standard of care for percutaneous coronary intervention (PCI) in all patient and lesion subsets.[5-7] Notwithstanding this, stent technology is characterized by continuous innovation and novel devices have been developed or are currently under clinical investigation aiming to further improve long-term outcomes. BRS represent the most recent innovation in coronary stent technology. BRS are also known as bioresorbable stents or fully bioresorbable stents though use of the term scaffold is now more widespread and will be preferred in this report. These devices consist of coronary prostheses providing temporary mechanical scaffolding and site-specific release of antiproliferative agents in the initial months and years after implantation followed by complete bioresorption of the carrier device.

Nomenclature

BRS may be classified according to composition of the backbone as either polymeric (pBRS, comprised of polylactic acid or related compounds) or metallic (mBRS, comprised of magnesium alloy). BRS that are drug-eluting also include a drug-polymer matrix coating typically consisting of a biodegradable polymer matrix and an antiproliferative drug. The bioresorption process of BRS is often initiated by hydrolysis and results in complete degradation of the backbone skeleton into

carbon dioxide and water, amorphous calcium phosphate, and other degradation products depending on the specific platform. [8-10]

It is important to differentiate BRS from conventional metallic DES coated with a matrix coating of bioresorbable polymer and antiproliferative drug. Such devices have standard metallic non-degrading stent backbones and are known variously as bioresorbable polymer DES, bioabsorbable polymer DES or biodegradable polymer DES.

In general terms, bioabsorption is used to reflect the disappearance of the compound of interest and transformation into another substance,[11] whereas bioresorption indicates the total elimination of the compound by dissolution, assimilation and excretion.[12, 13] Degradation is to be used in the case of unknown or ex-vivo mechanisms, whereas biodegradation refers to a cell-mediated in-vivo mechanism.[12] Structural discontinuities, fragmentation, disintegration or dismantling of a polymer are used to describe physical degradation of polymeric device without systematic breakdown of constituting macromolecules.

2. UNMET NEEDS OF CURRENT METALLIC DES

New generation DES are a mature technology demonstrating excellent clinical outcomes at 1 year in both randomized clinical trials and large-scale clinical registries enrolling consecutively-treated patients. [1-4] Moreover, although some attrition of performance is observed with clinical follow-up out to 3 to 5 years,[14-16] the overall medium-term efficacy of this technology is high. This means that the bar is high with respect to comparative efficacy for new technologies such as BRS. In many respects, although unmet need can be said to exist with regard to late adverse events after conventional DES implantation, the magnitude of this issue is relatively small and

the overall prognosis of stented patients continues to be determined in large part by events resulting from generalized progression of atherosclerotic disease.[17] For all of these reasons, before considering the potential advantages of BRS technology in more detail, it might be observed that incremental benefit of any new technology should be tangible and clear before it is embraced in routine clinical practice.

PCI with current DES is effective in suppression of neointimal hyperplasia following arterial injury, prevention of constrictive remodelling, and sealing dissections. Most of these vascular processes are limited to the first year following stent implantation. Therefore, BRS may offer advantages over permanent metallic DES by avoiding the permanent metallic caging of the treated vessel over the long-term.[8, 9] Moreover, a number of unmet needs of current metallic DES might be potentially addressed by BRS technologies.

Very late stent thrombosis and restenosis

Although the performance of current generation metallic DES is excellent in the first year after implantation,[1] late adverse events related to the target lesion continue to occur beyond 1 year after stenting at rates of 0.3%-2% per year. Studies with late angiographic follow-up using early generation DES and BMS have documented late attrition in antirestenotic efficacy out to 2 to 5 years. [18-20] Moreover clinical trial and registry data show that very late stent thrombosis continues to occur over the medium- to long-term with an annual rate of approximately 0.1-0.3% with DES and BMS.[3, 4] Data from autopsy series, as well as emerging data from optical coherence tomography (OCT) studies suggest that neoatherosclerosis may play an important role in a proportion of these late adverse events[21] and may be related to stent-related delayed healing and impairment of functional endothelial integrity in the stented segment. It has been

hypothesized that BRS might address this limitation and improve late clinical outcomes beyond the excellent levels achieved with current metallic DES.

Implications of removal of permanent implant

Restoration of physiological vasomotion within the treated coronary segment has been documented using physiological testing during angiographic surveillance procedures after BRS implantation. [22-24] However, the ABSORB II trial failed to show improvements in vasomotion within the stented segment with the Absorb pBRS as compared to metallic everolimus-eluting stents (EES) at 3 years. Somewhat surprisingly, vasomotion was also detected within segments treated with metallic stents. Whether other BRS technologies may provide restoration of physiological vasomotion remains to be determined. Moreover, it remains to be determined whether benefits in vasomotion translate into improved clinical outcomes.

Restoration of vascular compliance has been suggested by intravascular palpography evaluation after BRS implantation.[25, 26] Vascular compliance may allow for return of physiological pulsatile cyclic strain and shear stress enabling mechanotransduction with subsequent expression of extracellular matrix proteins playing a role in the maintenance of vascular integrity.

Single arm, longitudinal intravascular imaging studies in selected patients throughout 5 years after BRS implantation have provided preliminary evidence for positive vascular remodelling over time.[23, 27] However, the ABSORB II trial failed to show a larger lumen area with the Absorb pBRS versus the metallic EES at 3 years of follow-up. Whether late expansive remodelling may develop during longer-term follow-up after Absorb pBRS or other BRS technologies remains to be determined.

OCT studies following BRS implantation have observed the development of a new fibrous cap – referred to as “neocap” – at the site of the implanted BRS.[28] The formation of this biologic barrier has the potential of shielding the underlying atherosclerotic plaque mitigating the risk of subsequent plaque rupture and of adverse events associated with neoatherosclerosis. This may be of particular interest for the treatment of vulnerable plaques but has not been evaluated in appropriately designed trials.

Table 1. Overview of CE-Marked Bioresorbable Scaffolds

Commercial name	Manufacturer /Approving Notified Body	Backbone material	Coating material	Platform design	Device thickness	Drug release	Drug load	Duration of drug release	Bioresorption in preclinical swine models	Year of CE-mark	Year of FDA approval	Year of PDMA (Japan) approval
ABSORB BVS 1.1	Abbott Vascular / BSI	PLLA	PDLLA	In-phase zig-zag hoops, cross-linked by bridges	156 µm	Everolimus	76-308 µg/stent	3 months	36 months	2011	2016	2016
DESolve (+ DESolve 100/DESolve Cx/ DESolve NXT)	Elixir Medical / LRQA	PLLA	PLLA	Tubular arrangement hoops, linked by bridges	100-150 µm	Novolimus	NA	3 months	24 months	2014	NA	NA
ART Pure	ART / NA	PDLLA	NA	creep resistance hinge design	170 µm	No drug elution	NA	NA	24 months	2015	NA	NA
Magmaris	Biotronik / BSI	Magnesium alloy	PLLA	6-crown design	150 µm	Sirolimus	1.4 µg/mm2	3 months	9-12 months	2016	NA	NA

FDA = Food and Drug Administration; LRQA = Lloyds Register Quality Assurance; NA = not available; PDLLA, poly-D, L-lactic acid; PMDA: pharmaceuticals and medical devices agency; PLLA, poly-L-lactic acid

3. MATERIAL COMPOSITION, PLATFORM DESIGN AND DEVICE OVERVIEW

An overview of BRS that have received CE mark approval for use in Europe is shown in **Table 1.** A number of the design features of these scaffolds are similar to those of conventional metallic DES. The drug release kinetics of drug-eluting BRS, for example, are broadly similar to that provided by contemporary metallic DES particularly compared with metallic DES and biodegradable surface polymer used for drug release. However, mechanical properties of BRS differ significantly from conventional stents, and these differences translate into smaller post-PCI luminal dimensions, and are likely of sufficient magnitude to impact on the rates of recurrent symptoms and the need for repeat revascularisation.

Mechanical properties of bioresorbable scaffolds

The important differences between conventional stents and BRS in terms of their mechanical properties are critical to the consideration of comparative efficacy between the two classes of device. Currently-developed BRS are primarily comprised of poly- lactic acid (PLA) or magnesium alloy (**Table 1**). Numerous different polymers are available, each with different chemical compositions, mechanical properties and subsequent bioresorption times. PLA polymers are already in widespread clinical use as polymer coatings on conventional DES as well as in applications such as resorbable sutures, soft tissue implants, orthopaedic implants and dialysis media. Compared to a permanent metal such as cobalt chromium, PLA polymer has less elasticity (poly-L-lactic acid [PLLA] 3.1-3.7 GPa vs. cobalt chromium 210-235 GPa), lower tensile strength (60-70 MPa vs. 1449 MPa) and a shorter elongation at break (2-6% vs. approx. 40%) (see details in **Table 2**).[29]

Table 2. Mechanical properties and degradation time for different polymers and metals.

Composition	Tensile modulus of elasticity (GPa)	Tensile strength (MPa)	Elongation at break (%)	Degradation time (months)
Poly(L-lactide)	3.1-3.7	60-70	2-6	>24
Poly (DL-lactide)	3.1-3.7	45-55	2-6	12-6
Poly (glycolide)	6.5-7.0	90-110	1-2	6-12
50/50 DL-lactide/glycolide	3.4-3.8	40-50	1-4	1-2
82/18 L-lactide/glycolide	3.3-3.5	60-70	2-6	12-18
70/30 L-Lactide/ ε -caprolactone	0.02-0.04	18-22	>100	12-24
Cobalt chromium	210-235	1449	～40	Biostable
Stainless steel 316L	193	668	40+	Biostable
Nitinol	45	700-1100	10-20	Biostable
Magnesium alloy	40-45	220-330	2-20	1-3

GPa = Giga Pascal, MPa = Mega Pascal

Bioresorbable materials have a couple of intrinsic limitations: (i) insufficient ductility which impacts scaffold retention on balloon catheter and limits the range of scaffold expansion during deployment; (ii) low tensile strength and stiffness which require thick struts to prevent recoil during implantation and vessel remodelling; (iii) mechanical properties become unstable with time, potentially causing dismantling (late discontinuities) of the device during resorption. To compensate for mechanical shortcomings of bioresorbable materials, strut thickness and width

of the current generation of BRS are in general higher than conventional metallic DES. The thicker protruding struts cause a more turbulent flow blood flow behind the struts and may act as a possible nidus for thrombus formation. Current BRS also require more careful preparation of the lesion before implantation as well as a post-dilatation of the scaffold after implantation all of which result in prolonged procedures, increased use of contrast agents and ancillary materials (non-compliant balloons, cutting balloons, scoring balloons, rotational atherectomy, intracoronary imaging) and cost. In addition pBRS are temperature sensitive and require storage at temperatures below room temperature.

A wide variety of BRS are being developed with newer generation devices aiming to incorporate thinner, narrower struts with enhanced mechanical properties thereby improving material tensile strength, stiffness, and ductility (see **Supplementary Table 1**). This could be achieved by controlling the composition, crystallinity and orientation of the polymer and by using different processing of the polymer such as extrusion, annealing, moulding, microbraiding and spinning. For example, the Arteriosorb polymeric scaffold made with the oriented polymer significantly improves the tensile strength to 220-260 MPa as well as the percentage elongation at break to 40-70%. The Mirage scaffold consisting of a highly oriented circular polylactide monofilament has a tensile strength of 300 MPa and percentage elongation of 35%. In addition to the improvement of the initial mechanical properties, the control of the onset and rate of degradation of materials can be crucial in improving the range of device applicability.

As of September 2016, at least 28 companies are developing bioresorbable scaffolds (see **Supplementary Table 1**). The most commonly used biodegradable material is PLLA (26 products), followed by magnesium (6 products). The other materials used were tyrosine polycarbonate,

salicylic acid polymer and iron. Except for the 4 products that have received CE mark, at least 11 scaffolds are undergoing clinical trials for regulatory approval.

Current generation BRS have a number of mechanical limitations in comparison with metallic DES. This impacts on their handling and deliverability and makes the implantation procedures more cumbersome. In particular lower radial strength (see **Table 2**) means that more extensive lesion preparation is necessary, post-dilation is mandatory and intravascular imaging guidance should be liberally used to identify and correct suboptimal stent deployment. Reduced expansion capabilities confer extra burden in relation to accurate vessel sizing before implantation. In addition thicker stent struts and large stent footprint (i.e., arterial coverage by struts) may be associated with higher rates of acute side branch compromise and peri-procedural myocardial infarction and impact on crossing profile, compromising to some extent the deliverability of the device. Newer generation devices are aiming at thinner struts ≤120 µm compared to the currently available BRS devices.

Key features of currently-approved bioresorbable scaffolds

Three polymeric and one metallic BRS have received CE approval as of April 2017: the Absorb pBRS 1.1 (Abbott Vascular, Santa Clara, California), the DESolve pBRS (Elixir Medical, Sunnyvale, California), and the Arterial Remodelling Technologies (ART) pBRS, as well as the mBRS Magmaris (Biotronik, Berlin, Germany). The Absorb pBRS is also approved for use in the United States and Japan. Key features of these CE mark-approved devices are summarized in **Table 1**.

The **Absorb BVS 1.1** is a pBRS based on a backbone made of PLLA with a strut thickness of 156 µm. The platform design is characterized by in-phase zig-zag hoops cross-linked by bridges, with radiopaque markers at both ends. The scaffold backbone is coated with poly-D, L-lactic acid (PDLLA) polymer that allows controlled release of everolimus at a dose ranging from 76 to 308 µg, depending on length, with complete drug elution during 3 months. In animal studies, the device appeared to be fully bioresorbed within 36 months.

The **DESolve scaffold** is a pBRS also based on a backbone made of PLLA with a strut thickness of 150 µm. The platform design is characterized by tubularly arranged hoops linked by bridges, with two radiopaque markers. A bioresorbable PLLA coating allows controlled release of novolimus, with complete drug elution during 3 months. In animal studies, the device appeared to be fully bioresorbed at 24 months. Thinner strut versions of the device have also been approved (DESolve 100, with a strut thickness of 100 µm; DESolve Cx and DESolve NXT, with a strut thickness of 120 µm) though published clinical data with these latter device iterations is not available.

The **Magmaris mBRS** differs from the other CE-approved devices in view of its metallic biodegradable composition. It is made of a magnesium alloy with a 6-crown 2-link design. The backbone is characterized by strut thickness of 150 µm with radiopaque markers at both ends. The metallic backbone is coated with a bioresorbable PLLA polymer allowing controlled release of sirolimus at a dose of 1.4 $\mu g/mm^2$, with complete drug elution during 3 months. In animal studies, the device appeared to be fully bioresorbed within 9-12 months.

The ART PLLA stent (Noisy le Roi, France) is a non-drug-eluting poly-lactic acid pBRS which has a unique combination of L (98%) and D isomers (2%). The scaffold has a strut thickness of 170 micron with a scaffold surface area of <25%. The device is programmed to have an early dismantling which starts 3 months after implantation, as demonstrated in the micro-computer tomography analysis of the animal study.[30] Scaffold resorption in animal models occurs at around 24 months.

4. CLINICAL OUTCOMES WITH CE-APPROVED BIORESORBABLE SCAFFOLDS

1. ABSORB bioresorbable scaffold

The everolimus-eluting Absorb pBRS received CE mark approval for use in January 2011. It is the only device in this class with clinical outcome data from randomized clinical trials and to have reached limited use in clinical practice to date.

A total of seven published randomized clinical trials have investigated outcomes in studies with and without protocol mandated imaging follow-up (**Table 3**).[31-37] The comparator device in most trials was the Xience EES (Abbott Vascular, Santa Clara, California). The main clinical outcomes of each of the randomized clinical trials at early and late follow-up reported to date are detailed in **Table 4** and **Table 5.** The main results are as follows:

- The **ABSORB II** trial was designed to assess vasomotion and lumen dimensions at three year follow-up. The trial aimed to demonstrate two mechanistic properties of the pBRS: increase in lumen dimensions as a result of scaffold resorption and restoration of vasomotion of the stented vessel. The 3-year co-primary endpoints were vasomotor

reactivity (powered for superiority) and late lumen loss (powered for non-inferiority). The one year endpoint report of the ABSORB II trial showed broadly comparable rates of target lesion failure (TLF) in comparison with metallic EES at 1 year (4.8% vs. 3.0%, P=0.35).[38] However, TLF was significantly higher with Absorb pBRS than metallic EES at 3 years (10% vs 5%, hazard ratio [HR] 2·17 [95% confidence interval (CI) 1.01–4.70]; P=0.0425), mainly due to higher rates of target-vessel myocardial infarction (MI, 6% vs 1%; P=0.0108).[31] Moreover, the trial did not meet its co-primary endpoints of superior vasomotor reactivity and non-inferior late luminal loss for the Absorb BRS with respect to the metallic EES. The vasomotor reactivity at 3 years was not statistically different (Absorb BRS group 0·047 mm [SD 0·109] vs Xience EES group 0·056 mm [0·117]; p for superiority=0·49), whereas the late luminal loss was larger in the Absorb BRS group than in the Xience EES group (0·37 mm [0·45] vs 0·25 mm [0·25]; p for non-inferiority=0·78). In addition there was no evidence of difference in terms of relief of angina pectoris.

- The **ABSORB III** trial was powered to investigate non-inferiority for a clinical composite efficacy endpoint. Enrolling 2,008 patients, the ABSORB III trial is the largest randomized trial reported to date.[32] Patients were randomly assigned in a 2:1 ratio (active treatment vs control) after predilatation of the target lesion. The primary endpoint was a composite of cardiac death, target-vessel MI and ischemia-driven target lesion revascularization (TLR, TLF and non-inferiority was assessed against an expected event rate of 7% with a pre-specified non-inferiority margin of 4.5%. The main finding of the study was that TLF at 1 year was non-inferior with BRS vs. EES in both intention-to-treat (7.8% versus 6.1%, difference 1.7%, upper bound of 95% CI 3.9%, $P_{noninferiority}$ 0.007) and as treated analyses (8.0% versus 6.0%, difference 2.0% upper bound of 95% CI 4.1%, $P_{noninferiority}$ 0.01). Rates of target vessel MI (6.0% versus 4.6%; P=0.18) and definite/probable stent/scaffold

thrombosis at 1-year were numerically higher with BRS (1.5% versus 0.7%, P=0.13). Results of 2-year follow-up have recently been presented showing a higher rate of TLF (11.0% vs. 7.9%, P=0.03) and target vessel MI (7.3% vs. 4.9%, P=0.04) with BRS vs. EES as well as a numerically higher rate of stent/scaffold thrombosis with BRS (1.9% vs. 0.8%).[39]

- The **ABSORB China** trial was designed to assess non-inferiority with respect to angiographic effectiveness at 1 year in a Chinese population. The trial was not powered for clinical endpoints but reported similar rates of the composite of cardiac death, target-vessel MI or ischemia-driven TLR (3.4% vs. 4.2%, P=0.62) and definite/probable stent/scaffold thrombosis (0.4% vs. 0.0%, P=1.00) at 1 year in patients allocated to treatment with BRS versus EES.[33] Two-year follow-up showed low and comparable event rates in both groups (TLF 4.2% vs 4.6% respectively).[40]
- The **ABSORB Japan** trial was designed to assess non-inferiority for a clinical composite efficacy endpoint in a Japanese population, with wide prespecified non-inferiority margin. The trial showed broadly comparable results in terms of the composite of cardiac death, target vessel MI, or ischaemia-driven TLR at 12 months (BRS 4.2% vs. EES 3.8%, difference [95% CI] 0.39% [3.95%]; non-inferiority margin 8.6%, $P_{non\text{-}inferiority}$, 0.0001); however at 2 years TLF was numerically higher with BRS (BRS: 7.3% vs. CoCr-EES 3.8%, P=0.18) with an approximately 2-fold increase in definite stent/scaffold thrombosis (3.1% vs. 1.5%, P=0.51). [41]
- The **EVERBIO trial** was an investigator-initiated trial comparing angiographic outcomes at 9 months in patients randomly allocated to BRS, metallic EES or metallic biolimus-eluting stents (BES, Biomatrix Flex, Biosensors).[36] The primary endpoint was in-stent late lumen loss. Although not powered for clinical endpoints the trial reported comparable clinical outcomes at 9 months between BRS and EES/BRS: the composite of cardiac death, MI and

TLR rate was 9% in the BRS group and 12% in the EES/BES group (P=0.60). Two-year follow-up showed broadly comparable outcomes in both treatment groups in terms of the same endpoint (16% vs. 21%, P=0.54).[42]

- The **ABSORB STEMI-TROFI II** investigator-initiated trial investigated vascular healing as assessed by frequency domain OCT at 6 months among patients with ST-segment elevation myocardial infarction (STEMI). The primary endpoint showed non-inferiority in terms of vascular healing with BRS as compared to EES. Clinical event rates were very low with no signal of difference in TLF between the groups (Absorb BRS: 1.1% vs. EES: 0%).[37] Recently presented 2-year follow-up showed low and broadly similar event rates in both groups (3.2% vs. 3.2% respectively).[43]
- The **AIDA** investigator-initiated trial enrolled relatively unselected patients undergoing intervention in routine practice including patients with acute coronary syndromes.[35] The trial intended to test non-inferiority of BRS versus EES at 2 years. However, during follow-up and after full enrolment the data and safety monitoring board of the trial recommended early reporting due to safety concerns. At the time of reporting the median duration of follow-up was 707 days. The primary endpoint – a composite of cardiac death, target vessel MI, or target vessel revascularization – was similar in both groups (11.7% vs. 10.7%, HR 1.12 [0.85-1.48], P=0.43). Definite/probable stent/scaffold thrombosis was significantly higher in the BRS treatment group (3.5% versus 0.9%, P<0.001).

An overview of the main characteristics of the first six randomized trials with Absorb BRS as well as rates of TLR and stent/scaffold thrombosis is shown in **Figure 1**.

Meta-analysis of the first six trials with reported follow-up at one year shows rates of TLR with ABSORB BRS that are comparable to metallic EES but a two-fold increase in the risk of stent/scaffold thrombosis (see **Figure 2**).[44] A pooled analysis of individual patient data from the four industry-sponsored studies showed broadly concordant findings.[45]

A meta-analysis of all 7 randomised trials reporting long-term follow-up with a minimum 2-year clinical follow-up has been recently performed by a number of members of the Task Force.[46] A total of 5,583 included patients received BRS (n= 3,261) or EES (n= 2,322). Weighted median follow-up was 25 months. Patients treated with BRS versus EES showed higher risk for TLF (odds ratio, OR [95% CI] = 1.34 [1.10-1.64], p= 0.012) (**Figure 3A**) due to a higher risk of target vessel MI (OR 1.66 [1.21-2.29], p= 0.008) and ischaemia-driven TLR (OR 1.41 [1.11-1.79], p= 0.012). Patients treated with BRS versus EES showed a higher risk for definite/probable stent/scaffold thrombosis (OR 3.21 [2.28-4.51], p= 0.0002) (**Figure 3B**), most marked in the period beyond 1 year after implantation (OR 4.56 [1.89-10.95]; p= 0.007).

In terms of registry studies, results from a large number of predominantly small and moderate sized clinical registries have been published. The largest reported datasets were consistent in showing generally acceptable clinical outcomes at one year.[47-51] An overview of the main characteristics of large registry studies with Absorb pBRS as well as rates of TLR and stent/scaffold thrombosis is shown in **Figure 1**. Rates of stent/scaffold thrombosis appeared somewhat higher than those observed with conventional DES in routine clinical practice. [47-51] Importantly, it should be noted that despite the implantation of significant numbers of devices worldwide in the years since approval – estimated to be of the order of >200,000 devices – only a

small proportion of patients have been entered into registries with reports that have been published in the peer-reviewed literature.

A potential relationship between vessel-device mismatch and clinical events was investigated. In a pooled dataset from Absorb cohort B, Absorb II and Absorb Extend trials (N=1232 patients), scaffold oversize (maximal vessel diameters on quantitative coronary angiography [QCA] smaller than nominal size of the device) was associated with the increased major adverse cardiac event rate (oversize: 6.6% vs. non-oversize: 3.3%, $p_{log\text{-}rank}$ 0.01) mainly driven by a higher MI rate within 1 month post-procedure (3.5% vs. 1.9%; p = 0.08). [52] Scaffold under-size could lead to large malapposition, which is not correctable beyond the expansion limit of the Absorb scaffold. [23] Implantation of BRS in a too large vessel (e.g. >4.0mm) should therefore be avoided. These data emphasize the importance of vessel sizing and device size selection before implanting Absorb.

Clinical data suggested the necessity of intensive predilatation and postdilatation, in order to overcome the mechanical limitations of BRS, to achieve a similar acute performance to metallic DES, and to improve clinical outcomes. In the randomized trials, acute lumen gain of Absorb pBRS was consistently lower than DES in simple lesions when postdilatation was not mandatory. [32-34, 38] In the Absorb II and the Absorb Japan trials, intravascular imaging demonstrated that BRS expand more eccentrically and asymmetrically [41, 53]. In the Absorb II trial, multivariate analysis identified that post-procedural asymmetry was an independent predictor of TLF [HR 3.43, 95% CI: 1.08-10.92, p=0.037] [53]. Plaque morphology, especially calcification, influenced strut embedment [non-atherosclerotic (58.9±54.3µm), fibroatheroma (73.3±59.6µm), fibrous plaque (59.7±51.1µm), and fibrocalcific plaque (-3.1±61.6µm, negative value means malapposition), P <0.001]. [54] Balloon-artery ratio of predilatation and post-dilatation was positively correlated with

expansion of Absorb. [pre-dilatation (Pearson Correlation r: QCA:0.167 vs. OCT:0.552), post-dilatation (QCA:0.316 vs. OCT:0.717)]. [54] Puricel et al. demonstrated that by employing dedicated optimal implantation strategy (predilatation with non-compliant balloon, postdilatation with non-compliant balloon at high pressure etc.), the stent/scaffold thrombosis rate decreased from 3.3% to 1.0%, an effect that remained significant when adjusted for multivariable propensity score (p = 0.012; HR: 0.19; 95% CI: 0.05 to 0.70).[50] In addition, an analysis of data from the GHOST-EU registry showed that presence of all 3 of lesion predilatation, accurate sizing and scaffold postdilatation was an independent predictor of one-year adverse events (HR 0.75, 95% CI: 0.61-0.93; p=0.007), albeit with poor calibration and discrimination (area under curve, AUC 0.611, 95% CI: 0.545-0.677).[55] Examination of procedural data from both randomized trials and registries shows that postdilatation is now more frequently done and is almost universal in most recent studies (**Figure 1**). How this change in practice will impact on the rate of clinical events remains unknown.

Recent data from long-term follow-up of randomized trials provided evidence regarding a possible excess of late stent/scaffold thrombosis with Absorb pBRS in comparison with conventional stents.[31, 41, 56] Findings from intravascular imaging at the time of presentation with scaffold thrombosis in patients enrolled in clinical trials as well as in observational studies provide some insight into the pathophysiology of these events (see **Figure 4**).[41, 57, 58] While in acute and subacute scaffold thrombosis cases, strut malapposition, incomplete lesion coverage and under-deployment were the most frequently observed imaging findings in late and very late scaffold thrombosis cases, malapposition, late discontinuity and peri-strut low intensity area were frequently observed at the time of event.[58] Amongst these imaging findings associated with late/very late scaffold thromboses, late discontinuities are specifically related to the BRS

technology. Late discontinuity is generally a benign change during the bioresorption process and does not have clinical significance if these struts are well covered.[59] In the first-in-man Absorb Cohort B trial, out of 50 patients (51 lesions), late structural discontinuity was observed in 21 patients (43%) in 3 years, associated with no ischemic events.[59] However, when struts are not covered by neointimal tissue, discontinued and protruding struts may be a potential cause of late or very late scaffold thrombosis. Three main factors are hypothesized to be involved in late/very late scaffold thrombosis: (i) alteration in laminar flow as a consequence of loss of integrity of the scaffold backbone; this may lead to prolapse of part of the scaffold into the vessel lumen; (ii) thrombogenicity of the breakdown products and/or the extracellular matrix replacing the strut void; and (iii) effects of inflammation at a tissue level due to breakdown/resorption of the scaffold at a time when protection is now longer provided by drug elution from the scaffold backbone.

A summary of on-going clinical trials with the Absorb pBRS is shown in **Table 7**.

2. DESolve bioresorbable scaffold

The novolimus-eluting DESolve pBRS received CE mark approval in May 2014. The single arm **DESolve Nx trial** enrolled 126 patients treated with 150µm thickness pBRS. At 2 years major adverse cardiac events were observed in 7.4%.[60] No randomized clinical trial data are available to date.

A single comparative analysis between the DESolve BRS and the Absorb BRS is available using a propensity-score matching model.[61] The main finding was that outcomes at one year were similar between the two devices: the one-year rates of TLF (4.7 vs. 4.5%; p=0.851), TLR (2.6 vs.

3.5%; p=0.768), cardiac death (1.5 vs. 2.0%;p=0.752), and definite stent/scaffold thrombosis (2.0 vs. 1.0 %; p=0.529) did not differ significantly between Absorb BRS and DESolve BRS.

3. Magmaris bioresorbable magnesium scaffold

The Magmaris drug-eluting mBRS received CE mark approval in June 2016. Clinical data is limited to results from the **BIOSOLVE-II** study, a single arm study enrolling 123 patients.[62, 63] Overall rates of clinical events at 12 months were low: TLF was observed in 3.4%, 95% CI: 0.9–8.4. No randomized clinical trial data are available to date.

4. ART

This is a non-drug eluting pBRS. There are no published clinical outcome data with this device. The device was tested in the ART-DIVA trial enrolling 30 patients with single de novo lesion of a native coronary artery (NCT01761578). At 6 months, there were no cardiac deaths, no MI, one ischemia-driven TLR and 2 non-ischemia-driven TLRs reported (Presentation, Lafont, EuroPCR 2016). Following this study, the non-drug-eluting pBRS received a CE mark.

Table 3. Main baseline characteristics of patients in enrolled in randomized trials comparing the Absorb BRS with conventional metallic DES

Trial	*Patients, n*	*Age, yrs*	*Males, %*	*Diabetes, %*	*ACS at admission, %*	*Lesions, n*	*RVD, mm*	*Length, mm*
ABSORB II[38]	501	61.2	78	24	21*	546	2.61	13.8
ABSORB III[32]	2008	63.5	70	32	26*	2098	2.66	12.8
ABSORB China[33]	480	57.4	72	24	64*	503	2.81	14.0
ABSORB Japan[34]	400	67.2	76	36	13*	412	2.75	13.4
AIDA[35]	1845	64.2	74	18	54	2446	2.67	18.9
EVERBIO II[36]	240	65.0	79	19	35	325	2.58	NA
TROFI II[37]	191	58.6	82	17	100	193	2.81	13.1

Overall mean values are reported; *unstable angina only. ACS: acute coronary syndrome; RVD: reference vessel diameter; NA: not available. ABSORB China: A Clinical Evaluation of Absorb™ Bioresorbable Vascular Scaffold (Absorb™ BVS) System in Chinese Population; ABSORB II: A Clinical Evaluation to Compare the Safety, Efficacy and Performance of ABSORB Everolimus Eluting Bioresorbable Vascular Scaffold System Against XIENCE Everolimus Eluting Coronary Stent System in the Treatment of Subjects With Ischemic Heart Disease Caused by de Novo Native Coronary Artery Lesions; ABSORB III: A Clinical Evaluation of Absorb™ BVS, the Everolimus Eluting Bioresorbable Vascular Scaffold in the Treatment of Subjects With de Novo Native Coronary Artery Lesions; ABSORB Japan: A Clinical Evaluation of AVJ-301 (Absorb™ BVS), the Everolimus Eluting Bioresorbable Vascular Scaffold in the Treatment of Subjects With de Novo Native Coronary Artery Lesions in Japanese Population; AIDA: Amsterdam Investigator-initiateD Absorb strategy all-comers trial; EVERBIO II: Comparison of Everolimus- and Biolimus-Eluting Stents With Everolimus-Eluting Bioresorbable Vascular Scaffold; TROFI II: Comparison of the ABSORB™ Everolimus Eluting Bioresorbable Vascular Scaffold System With a Drug- Eluting Metal Stent (Xience™) in Acute ST-Elevation Myocardial Infarction

Table 4. Clinical outcomes at 1-year from six randomized trials comparing bioresorbable scaffolds versus metallic everolimus-eluting stents

	TLF	POCE	Death	Cardiac death	MI	TVMI	TLR (*ID-TLR)	D/P-stent/scaffold thrombosis	Definite stent/scaffold thrombosis
ABSORB II[38]	16/335 (5) vs 5/166 (3)	24/335 (7) vs 15/166 (9)	0/335 (0) vs 1/166 (1)	0/335 (0) vs 0/166 (0)	15/335 (4) vs 2/166 (1)	NA	4/335 (1) vs 3/166 (2)*	3/335 (0.9) vs 0/166 (0)	2/335 (0.6) vs 0/166 (0)
ABSORB III[32]	102/1313 (7.8) vs 41/677 (6.1)	NA	15/1313 (1.1) vs 3/677(0.4)	8/1313 (0.6) vs 1/677 (0.1)	90/1313 (6.9) vs 38/677 (5.6)	79/1313 (6.0) vs 31/677 (4.6)	40/1313 (3.0) vs 17/677 (2.5)*	20/1301 (1.5) vs 5/675 (0.7)	18/1301 (1.4) vs 5/675 (0.7)
ABSORB China[33]	8/238 (3.4) vs 10/237 (4.2)	19/238 (8.0) vs 23/237 (9.7)	0/238 (0) vs 5/237 (2.1)	0/238 (0) vs 3/237 (1.3)	5/238 (2.1) vs 4/237 (1.7)	4/238 (1.7) vs 2/237 (0.8)	6/238 (2.5) vs 5/237 (2.1)*	1/238 (0.4) vs 0/232 (0)	0/238 (0) vs 0/232 (0)
ABSORB Japan[34]	11/265 (4.2) vs 5/133 (3.8)	26/265 (9.8) vs 11/133 (8.3)	2/265 (0.8) vs 0/133 (0)	0/265 (0) vs 0/133 (0)	9/265 (3.4) vs 3/133 (2.3)	9/265 (3.4) vs 3/133 (2.3)	7/265 (2.6) vs 3/133 (2.3)*	4/262 (1.5) vs 2/133 (1.5)	4/262 (1.5) vs 1/133 (0.8)
EVERBIO II§[36]	9/78 (12) vs 11/80 (14)	21/78 (27) vs 26/80 (33)	1/78 (1) vs 3/80 (4)	1/78 (1) vs 0/78 (0)	1/78 (1) vs 1/80 (1)	0/78 (0) vs 0/80 (0)	8/78 (10) vs 11/80 (14)	0/78 (0) vs 0/80 (0)	0/78 (0) vs 0/80 (0)
TROFI II†[37]	1/95 (1.1) vs 0/96 (0)	NA	0/95 (0) vs 0/96 (0)	0/95 (0) vs 0/96 (0)	1/95 (1.1) vs 0/96 (0)	1/95 (1.1) vs 0/96 (0)	1/95 (1.1) vs 0/96 (0)*	1/95 (1.1) vs 0/96 (0)	1/95 (1.1) vs 0/96 (0)

Data are shown for bioresorbable scaffolds vs. metallic everolimus-eluting stents as n/N (%) and are at 1-year unless otherwise stated; §= at 9 months, †= at 6 months; ID-TLR=ischemia-driven target lesion revascularization; MI=myocardial infarction; NA= not available; POCE=patient-oriented composite endpoint; TLF=target lesion failure; TLR=target lesion revascularization; TVMI=target-vessel myocardial infarction; details of trial acronyms as in table 3

Table 5. Clinical outcomes at long-term follow-up from 7 randomized trials comparing BRS versus metallic everolimus-eluting stents

	TLF	POCE	Death	Cardiac death	MI	TVMI	TLR (*ID-TLR)	D/P-stent/scaffold thrombosis	Def stent/scaffold thrombosis
ABSORB II†[31]	34/325 (10) vs. 8/161 (5)	68/325 (21) vs. 39/161 (24)	8/325 (2) vs. 6/161 (4)	3/325 (1) vs. 3/161 (2)	27/325 (8) vs. 5/161 (3)	23/325 (7) vs. 2/161 (1)	20/325 (6) vs 3/161 (2)*	9/320 (3) vs 0/159 (0)	8/320 (3) vs 0/159 (0)
ABSORB III[39]	143/1322 (11.0) vs 53/686 (7.9)	NA	NA	14/1322 (1.1) vs. 4/686 (0.6)	NA	95/1322 (7.3) vs. 33/686 (4.9)	69/1322 (5.3) vs. 29/686 (4.3)	24/1322 (1.9) vs. 5/686 (0.8)	NA
ABSORB China[40]	10/237 (4.2) vs 11/237 (4.6)	24/237 (10.1) vs 27/237 (11.4)	1/237 (0.4) vs 6/237 (2.5)	1/237 (0.4) vs 3/237 (1.3)	7/237 (3.0) vs 5/237 (2.1)	5/237 (2.1) vs 2/237 (0.8)	8/237 (3.4) vs 6/237 (2.5)*	2/237 (0.8) vs 0/231 (0)	1/237 (0.4) vs 0/231 (0)
ABSORB Japan[41]	19/261 (7.3) vs 5/130 (3.8)	52/261 (19.9) vs 16/130 (12.3)	4/261 (1.5) vs 0/130 (0)	1/261 (0.4) vs 0/130 (0)	14/261 (5.4) vs 4/130 (3.1)	13/261 (5.0) vs 4/130 (3.1)	14/261 (5.4) vs 3/130 (2.3)*	8/257 (3.1) vs 2/130 (1.5)	8/257 (3.1) vs 1/130 (0.8)
AIDA[35]	91/924 (10.3) vs. 78 (8.9)	105/924 (11.7) vs. 94/921 (10.7)	32/924 (3.5) vs. 43/921 (4.3)	18/924 (2.0) vs. 23 (2.7)	62/924 (7.1) vs. 41 (4.2)	48/924 (5.5) vs. 30 (3.2)	60/924 (7.0) vs. 45 (5.2)	31 (3.5) vs. 8 (0.9)	27 (3.1) vs. 5 (0.6)
EVERBIO[42]	16 (21) vs. 13 (16)	27 (35) vs. 30 (38)	2 (3) vs. 4 (5)	1 (1) vs. 1 (1)	4 (5) vs. 2 (3)	2 (3)= vs. 0 (0)	11 (14) vs. 8 (10)	1 (1) vs. 0 (0)	1 (1) vs. 0 (0)

TROFI II[43]	3 (3.2) vs 3 (3.2)	NA	1 (1.1) vs 1 (1.0)	1 (1.1) vs 1 (1.0)	3 (3.2) vs 3 (3.2)	2 (2.1) vs 3 (3.2)	2 (2.1) vs 1 (1.0)*	2/95 (2.1) vs 1 (1.0)	2 (2.1) vs 1 (1.0)

Data are shown for bioresorbable scaffolds vs. metallic everolimus-eluting stents as n/N (%) and are at 2-years follow-up unless otherwise indicated; †=at 3 years; ID-TLR=ischemia-driven target lesion revascularization; ID-TVR= ischemia-driven target vessel revascularization; MI=myocardial infarction; NA=not available; POCE=patient-oriented composite endpoint; TLF=target lesion failure; TLR=target lesion revascularization; TVMI=target-vessel myocardial infarction; TVR=target vessel revascularization; details of trial acronyms as in table 3

Table 6. Angiographic outcomes at follow-up from six randomized trials comparing bioresorbable scaffolds versus metallic everolimus-eluting stents

	In-segment diameter stenosis, %	In-device diameter stenosis, %	In-segment late luminal loss, mm	In-device late luminal loss, mm	In-segment binary restenosis, %	In-device binary restenosis, %
ABSORB II 36 months[31]	27.7 ± 17.0 vs 22.7 ± 10.3	25.8 ± 17.2 vs 15.7 ± 8.3	-0.29 ± 0.46 vs -0.14 ± 0.34	0.37 ± 0.45 vs 0.25 ± 0.25	8.4 vs 3.3	7.0 vs 0.7
ABSORB China 12 months[33]	23.5 ± 0.84 vs 23.0 ± 0.92	18.5 ± 0.92 vs 11.3 ± 0.76	0.18 ± 0.03 vs 0.13 ± 0.03	0.23 ± 0.03 vs 0.10 ± 0.02	3.9 ± 1.34 vs. 2.8 ± 1.13	2.9 ± 1.16 vs 0.75 ± 0.56
ABSORB Japan 13 months[34]	23.4 ± 11.3 vs 23.7 ± 12.3	17.4 ± 12.8 vs 11.7 ± 12.3	0.13 ± 0.30 vs 0.12 ± 0.32	0.19 ± 0.31 vs 0.16 ± 0.33	1.9 vs 3.9	1.5 vs 1-6
ABSORB Japan 24 months[41]	27.7 ± 12.2 vs 24.7 ± 10.2	23.3 ± 13.0 vs 14.8 ± 11.9	0.27 ± 0.38 vs 0.12 ± 0.32	0.36 ± 0.38 vs 0.21 ± 0.38	7.8 vs 2.5	5.2 vs 2.5
EVERBIO II 9 months[36]	17.8 ± 11.7 vs 15.5 ± 11.0	16.9 ± 11.6 vs 11.3 ± 9.8	0.30 ± 0.44 vs 0.20 ± 0.43	0.28 ± 0.39 vs 0.24 ± 0.32	11 vs 9	5 vs 4
TROFI II 6 months[37]	21.6 ± 7.3 vs 20.4 ± 9.1	17.3 ± 7.4 vs 14.5 ± 9.3	0.14 ± 0.28 vs 0.06 ± 0.29	0.17 ± 0.24 vs 0.08 ± 0.28	0 vs 1.1	0 vs 1.1

Data are shown for bioresorbable scaffolds vs. metallic everolimus-eluting stents as mean ± SD except ABSORB-China which reports mean ± SE; details of trial acronyms as in table 3

Table 7. Ongoing or planned large-scale randomized controlled trial with bioresorbable scaffolds

	Trial identifier	Patients, n	Comparator	Primary outcome	Comment
ABSORB IV	NCT02173379	3000	Xience	Angina within 1 year	excluding acute STEMI
Compare Absorb	NCT02486068	2100	Xience	Target lesion failure at 1 year	only patients at high-risk of restenosis
PREVENT	NCT02316886	1600	Optimal medical treatment	Cardiovascular death Nonfatal myocardial infarction Unplanned hospitalization leading to unstable angina	Functionally insignificant coronary stenosis with vulnerable plaque
BVS LATE	NCT02939872	2000	DAPT (aspirin and clopidogrel) vs Aspirin monotherapy	Composite event of death, myocardial infarction, or stroke	On dual antiplatelet therapy and between 12 months and 18 months after Absorb pBRS implantation

Only trials enrolling more than n>1000 patients are shown; all trials investigate the Absorb pBRS

Figure 1. Randomised controlled trials and cohort studies investigating the Absorb pBRS.

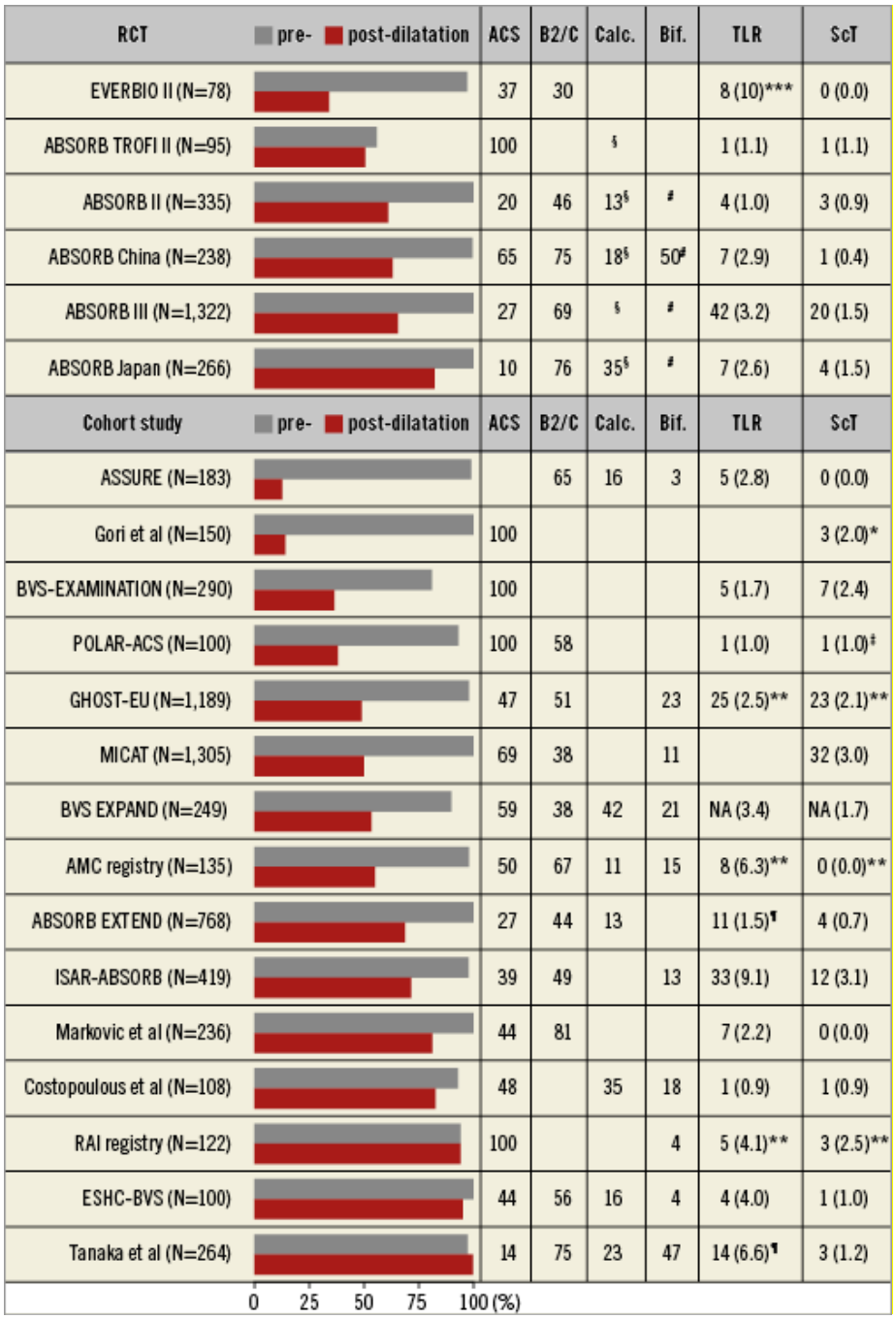

RCT (pre- / post-dilatation)	ACS	B2/C	Calc.	Bif.	TLR	ScT
EVERBIO II (N=78)	37	30			8 (10)***	0 (0.0)
ABSORB TROFI II (N=95)	100		§		1 (1.1)	1 (1.1)
ABSORB II (N=335)	20	46	13§	#	4 (1.0)	3 (0.9)
ABSORB China (N=238)	65	75	18§	50#	7 (2.9)	1 (0.4)
ABSORB III (N=1,322)	27	69	§	#	42 (3.2)	20 (1.5)
ABSORB Japan (N=266)	10	76	35§	#	7 (2.6)	4 (1.5)
Cohort study (pre- / post-dilatation)	**ACS**	**B2/C**	**Calc.**	**Bif.**	**TLR**	**ScT**
ASSURE (N=183)		65	16	3	5 (2.8)	0 (0.0)
Gori et al (N=150)	100					3 (2.0)*
BVS-EXAMINATION (N=290)	100				5 (1.7)	7 (2.4)
POLAR-ACS (N=100)	100	58			1 (1.0)	1 (1.0)‡
GHOST-EU (N=1,189)	47	51		23	25 (2.5)**	23 (2.1)**
MICAT (N=1,305)	69	38		11		32 (3.0)
BVS EXPAND (N=249)	59	38	42	21	NA (3.4)	NA (1.7)
AMC registry (N=135)	50	67	11	15	8 (6.3)**	0 (0.0)**
ABSORB EXTEND (N=768)	27	44	13		11 (1.5)¶	4 (0.7)
ISAR-ABSORB (N=419)	39	49		13	33 (9.1)	12 (3.1)
Markovic et al (N=236)	44	81			7 (2.2)	0 (0.0)
Costopoulous et al (N=108)	48		35	18	1 (0.9)	1 (0.9)
RAI registry (N=122)	100			4	5 (4.1)**	3 (2.5)**
ESHC-BVS (N=100)	44	56	16	4	4 (4.0)	1 (1.0)
Tanaka et al (N=264)	14	75	23	47	14 (6.6)¶	3 (1.2)

Horizontal histograms show rates of pre- and post-dilatation. Data reported as percentage or number of events (cumulative incidences) for any TLR and definite or probable scaffold thrombosis at one year, unless otherwise specified. *1 month. **6 months. ***9 months; ¶ischaemia-driven TLR; ‡definite scaffold thrombosis; §heavily calcified lesions were excluded; # major bifurcation lesions were excluded; ACS=acute coronary syndrome; NA= not available; RCT=randomised controlled trial; ScT=scaffold thrombosis; TLR=target lesion revascularisation [64]

Figure 2. Risk of target lesion revascularization and stent/scaffold thrombosis at early follow-up (6-12 months) in meta-analysis of six randomized controlled trials comparing bioresorbable scaffolds and conventional drug-eluting stents

A Target lesion revascularisation

	BVS Events	BVS Total	EES Events	EES Total	Weight (%)	Fixed-effects odds ratio (95% CI)
ABSORB China	7	238	7	237	13·2	1·00 (0·34–2·88)
ABSORB II	4	335	3	166	5·9	0·64 (0·13–3·12)
ABSORB III	42	1313	19	677	51·6	1·14 (0·67–1·95)
ABSORB Japan	7	265	5	133	10·1	0·68 (0·20–2·31)
EVERBIO II	8	78	11	80	16·3	0·72 (0·28–1·87)
TROFI II	2	95	1	96	2·9	1·98 (0·20–19·29)
Overall	**70**	**2324**	**46**	**1389**	**100**	**0·97 (0·66–1·43)**

Heterogeneity: χ^2=1·69, df=5; p=0·89; I^2=0%
Test for overall effect: Z=0·16; p=0·87
Random-effects odds ratio 0·97 (95% CI 0·66–1·43)

B Definite or probable stent thrombosis

	BVS Events	BVS Total	EES Events	EES Total	Weight (%)	Fixed-effects odds ratio (95% CI)
ABSORB China	1	238	0	232	3·1	7·21 (0·14–363·23)
ABSORB II	3	335	0	166	8·2	4·49 (0·04–49·92)
ABSORB III	20	1301	5	675	69·1	1·89 (0·82–4·34)
ABSORB Japan	4	262	2	133	16·5	1·02 (0·18–5·58)
EVERBIO II	0	78	0	80		Not estimable
TROFI II	1	95	0	96	3·1	7·47 (0·15–376·35)
Overall	**29**	**2309**	**7**	**1382**	**100**	**1·99 (1·00–3·98)**

Heterogeneity: χ^2=1·90, df=4; p=0·75; I^2=0%
Test for overall effect: Z=1·96; p=0·05
Random-effects odds ratio 1·99 (95% CI 1·00–3·98)

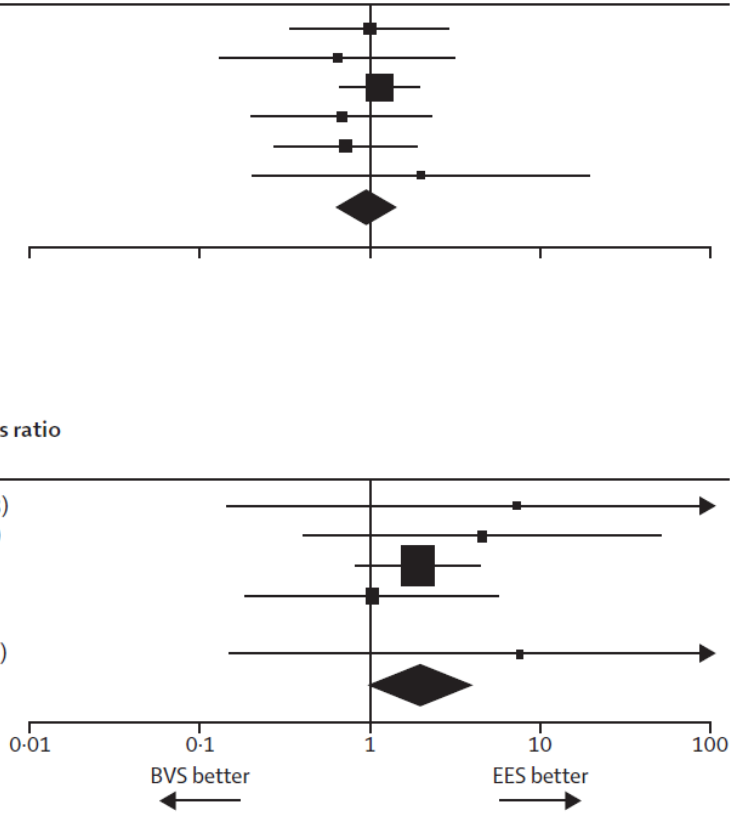

Plot of odds ratio for **(A)** target lesion failure and **(B)** definite/probable stent/scaffold thrombosis associated with BRS versus EES; BVS = Absorb bioresorbable scaffold; EES = everolimus-eluting stent [44]

Figure 3: Risk of target lesion failure and stent/scaffold thrombosis at follow-up of 2 years or more in meta-analysis of 7 randomized controlled trials comparing BRS and conventional DES

(A) Target lesion failure

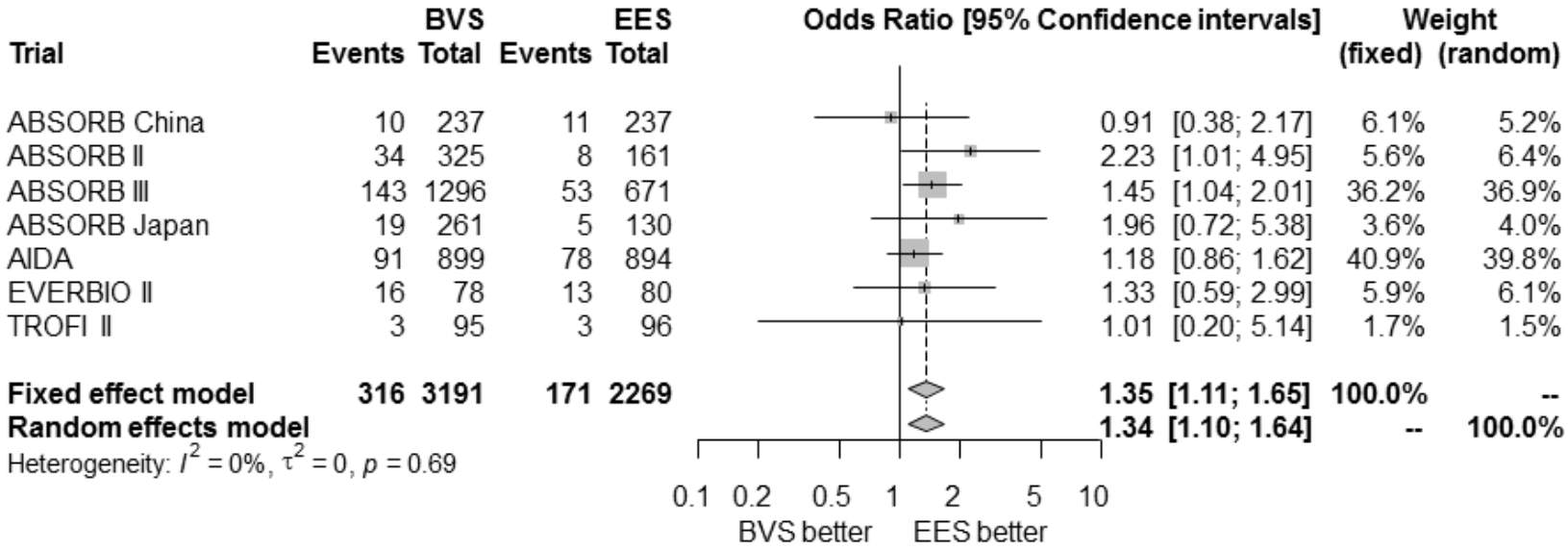

Odds ratios for target lesion failure with pBRS versus EES. The diamonds indicates the point estimate and the left and the right ends of the lines the [95% confidence interval, CI]. BVS=bioresorbable stent (i.e. Absorb pBRS); EES=everolimus-eluting stent

(B) Definite/probable stent/scaffold thrombosis

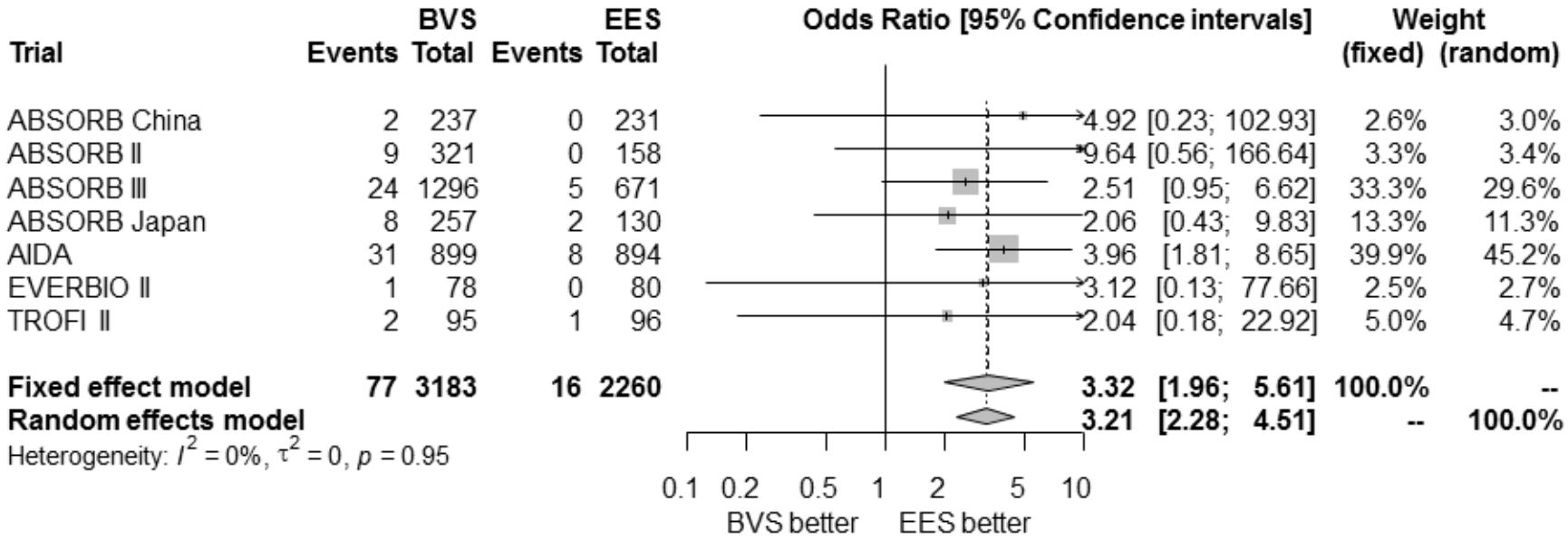

Odds ratios for definite/probable stent (scaffold) thrombosis with BRS versus EES. The diamonds indicates the point estimate and the left and the right ends of the lines the [95% confidence interval, CI]. BVS=bioresorbable stent (i.e. Absorb pBRS); EES=everolimus-eluting stent [46]

Figure 4. Representative OCT cross sections and 3D reconstructions from patients with very late scaffold thrombosis.

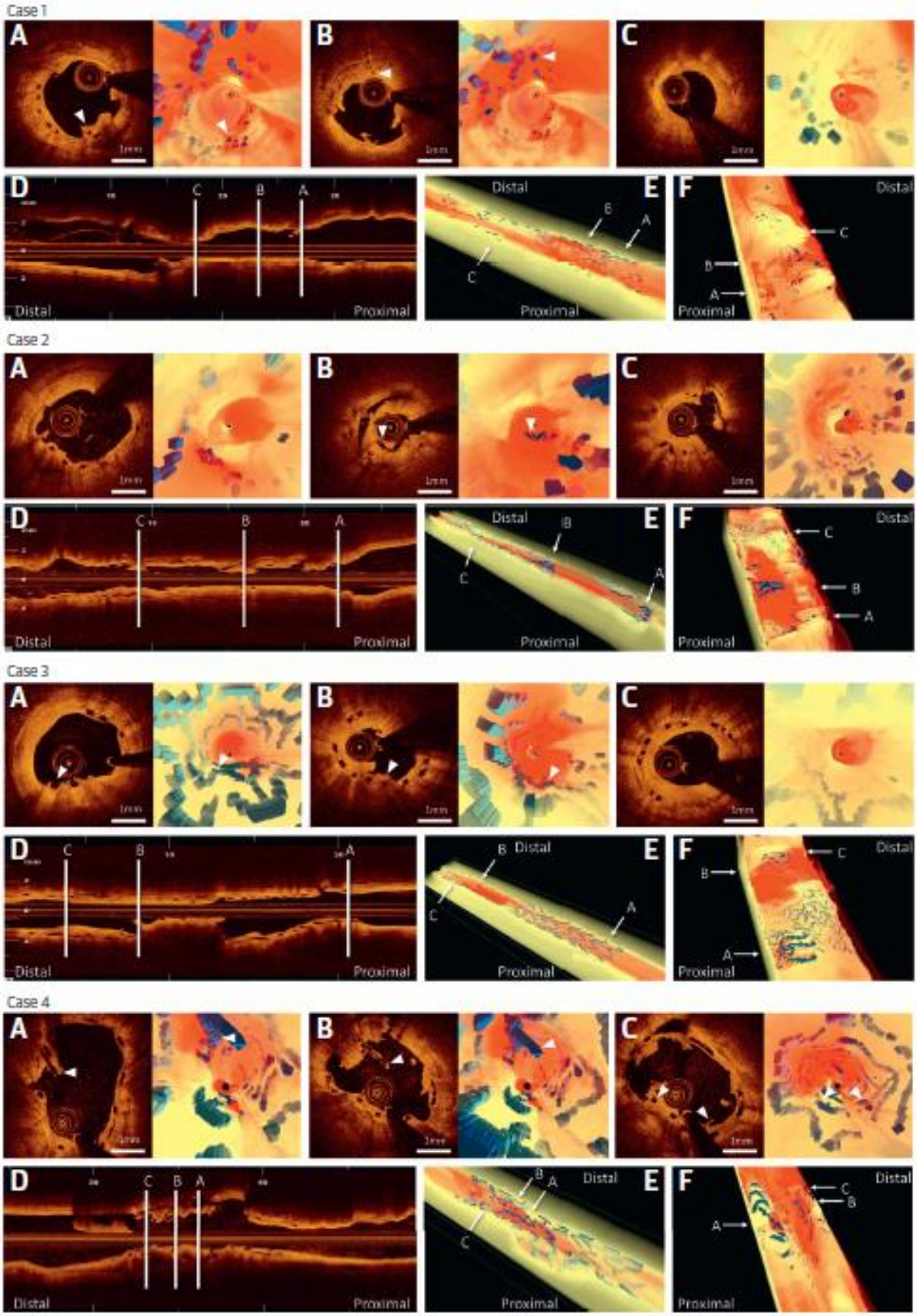

Legend for figure 4. Pullbacks were matched with the 3-dimensional (3D) and 2-dimensional (2D) longitudinal views (indicated by arrows in A to F). In all cases, D shows the longitudinal view, E the half-cut 3D view, and F the spread-out 3D view. Case 1 shows malapposed struts surrounded by thrombus (A, B, arrowheads) and the presence of macrophage accumulations at the minimal lumen area location (C). Case 2 shows extensive scaffold strut discontinuity (B, arrowheads) on 2D and 3D OCT. Case 3 shows thrombus on top of uncovered apposed scaffold struts (A, B, arrowheads). Case 4 shows a scaffold strut discontinuity (A, B, arrowheads) surrounded by thrombus, as well as uncovered struts (C, arrowheads) in 2D and 3D OCT. Yellow represents the lumen contour; blue is the scaffold strut; red is thrombus [57]

5. IMPORTANT CLINICAL SUBGROUPS

Small vessels

In the ABSORB trial (Cohort B), there were no differences in late lumen loss, in-segment binary restenosis and clinical outcomes at 2 years between groups of patients treated with the Absorb BRS stratified by a baseline reference vessel diameter of 2.5 mm.[65] This is consistent with the results of a real world registry that showed comparable outcomes of BRS for smaller compared with larger vessels.[66] In all these studies, however, the number of patients was small (<100 patients). In a three-centre, single-arm registry of 121 BRS patients with reference vessel diameter <2.75 mm, TLR and scaffold thrombosis occurred in 9.0% and 1.5%, respectively, at a median of 11.4 months.[67]

In the ABSORB III trial, patients were excluded if they had a reference vessel diameter <2.50 mm by visual estimation. [32] In subgroup analyses, there was no interaction between the relative treatment effect of pBRS and the median vessel diameter (2.63 mm) for both 1-year TLF (p for interaction = 0.90) and stent/scaffold thrombosis (p for interaction = 0.48). However, visual estimation tends to overestimate the vessel size compared with QCA and QCA identified that about one fifth of implanted vessels visually assessed as ≥2.50 mm were actually smaller. When

comparing the outcomes of 375 patients (408 lesions) with reference vessel diameter <2.25 mm (an arbitrarily defined post hoc cut-off) by QCA with the remainder of the ABSORB III population, there was evidence of a higher risk of 1-year device thrombosis with BRS compared with EES in the small vessels group (4.6% vs. 1.5%, respectively, in the <2.25 mm vessel group; 0.8% vs. 0.5%, respectively, in the ≥2.25 mm vessel group).[68] Similar results were noted with respect to TLF at 1 year, driven by an increase in MI in the small vessels group (10.0% vs 4.5% in the BRS and EES groups, respectively; P=0.06). Exploratory post-hoc analyses suggested that the rates of BRS thrombosis in the small vessels group were higher in patients who did not receive post-dilation (8.1%) and those who received post-dilation at <14 atmospheres (5.6%). Taken together, these findings may have important implications for lesion/device selection and technique, in that they discourage the use of the Absorb BRS for vessels <2.5 mm and encourage the use of on-line QCA for vessels sizes in the range of 2.5-2.75 mm. Against this an analysis from the ISAR-ABSORB registry found no difference in outcomes between patients treated with a 2.5 mm scaffold in comparison with those treated with a scaffold size larger than 2.5 mm diameter.[69] The United States FDA recommends vessel sizing with on-line QCA or intravascular imaging in case of vessels visually assessed as ≤2.75mm, and recommends not to implant an Absorb pBRS if quantitative imaging determines a vessel size <2.5mm.

Acute coronary syndromes

Relatively few registries have reported on the outcomes of patients treated with the Absorb BRS across the spectrum of acute coronary syndromes (ACS), including unstable angina, non-ST-segment elevation myocardial infarction and STEMI (**Supplementary Table 2**).[70-74] In studies with 12-month follow-up, mortality was reported at 0-3.1%, MI at 2-6.8%, TLR at 2-6.8% and definite scaffold thrombosis at 0.8-2.3%.[71-74] The largest analysis to data comes from the GHOST-EU

registry and showed a numerically higher incidence of POCE in 951 patients with ACS treated with pBRS as compared with patients with stable disease (6.4% vs. 4.2%, p=0.052).[75] In a meta-regression of 25 BRS studies, ACS emerged as a potential modifier for the risk of device thrombosis of both BRS and DES at follow-up.[76]

There are multiple specific reports of BRS in STEMI, although many of these studies represent the update of a previously published cohort (**Supplementary Table 3**).[37, 48, 77-90] In registries with a metallic stent control arm, there were similar rates of combined events in the BRS group, but the comparisons were unadjusted.[82, 88] By contrast, in a propensity score matched analysis from BVS-EXAMINATION there was a trend towards higher rates of definite thrombosis with BRS compared with everolimus eluting stents (EES) at 24 months (3.3% vs 1.0%; p=0.081) [89], and in a similar matched analysis from the BVS STEMI First study, BRS showed a higher clinical event rate compared with matched EES at 18 months.[87] TROFI II is the only randomized study of BRS and EES published so far, but the study was not powered for clinical endpoints. The device-oriented composite endpoint was comparably low between groups (1.1% BRS vs. 0% EES) at 6 months, and there was only one case of definite subacute stent/scaffold thrombosis.[37] At two years, one subacute and one very late scaffold thrombosis were observed in the Absorb pBRS arm (definite scaffold thrombosis rate at 2 years: 2.1%), whereas one very late scaffold thrombosis was observed in the EES arm (1.0%).

As far as important questions of efficacy and safety are concerned, all the available studies are limited by the lack of a control group, the nonrandomized design and/or the small sample size. Two earlier analyses suggest that the rates of scaffold thrombosis may be higher in ACS compared with non-ACS patients, a phenomenon already noted with DES [38, 76], although a more

recent meta-analysis suggested that ACS appeared to have little impact on the incidence of scaffold thrombosis.[91]

Chronic total occlusions

Multiple case reports suggest that treating chronic total occlusions (CTO) with BRS is feasible in selected patients after both anterograde and retrograde recanalization. [92-97] Preliminary studies are available that generally suggest acceptable short- and mid-term outcomes with BRS in this scenario (**Supplementary Table 4**). [98-107] In the largest series (N=105), major adverse events occurred in 3% of patients at 6 months.[101] In the only study with a control arm, however, technical and procedural successes were shown to be significantly lower in the BRS compared with the DES group.[102] Overall, larger-scale DES-controlled studies are necessary to better define the procedural characteristics and clinical outcomes of BRS in the setting of CTO recanalization.

Diffuse disease

Treatment of diffuse disease represents a clinically-relevant unmet need given limited suitability for bypass grafting and poor results with implantation of multiple metallic DES. Although conceptually attractive, using BRS for this indication results in placement of long chains of polymer and creation of multiple overlapping points at risk for delayed strut coverage.[108, 109] Scaffold enhancement techniques, coupled with angiography, may be helpful in minimizing overlap length and proportion of stacked struts.[110] A hybrid approach with a BRS for the larger proximal segment plus a drug-coated balloon for the smaller distal segment has been proposed for the treatment of patients with diffuse disease.[111]

In a multicentre study of 162 patients who received overlapping BRS, the rates of TLF and stent/scaffold thrombosis did not differ compared with those of propensity score matched patients who received overlapping DES, but there was a higher incidence of procedural-related myocardial injury with BRS.[112] In a smaller study, no differences were noted at 1 year in major adverse cardiovascular events, including TLR, between matched BRS and DES.[113] In an analysis of the GHOST-EU registry comparing the outcomes of 320 with overlapping pBRS with those of 1157 with no overlap, no difference in PoCE between the overlap versus no-overlap group (18.4% vs. 18.2%; HR 1.07, [0.80-1.44]; P = 0.636), was seen even after adjustment (HR 1.05, [0.48-2.20]; P = 0.904).[114]

In summary, there is a paucity of data in the literature on the fate of BRS for diffuse disease. A randomized trial named COMPARE ABSORB (NCT02486068) is currently testing BRS versus EES for the treatment of lesions at high risk of restenosis, including those longer than 28 mm (see **Table 7**).

Bifurcations

Despite technical limitations and concerns, specific 1-scaffold and 2-scaffold strategies have been described for the treatment of bifurcation lesions both in-vitro and in-vivo.[115-121] Multiple strategies and tips for material selection have been suggested to minimize the risk of fracture, including adaptation of established techniques for bifurcation lesions (i.e., low-pressure kissing balloon inflation with snuggling balloons, also known as mini-kissing balloon inflation).[120, 122-126]

Relatively few studies have reported on the outcomes of BRS for bifurcation lesions. In a study from Kawamoto et al. (N=132), treating bifurcations with BRS was shown to be feasible, but

there were numerically more TLR at 1-year with complex two-scaffold strategies compared with the provisional strategy.[127] The same group of authors later reported mid-term clinical outcomes in 41 patients treated with complex strategies (BRS in the main branch and BRS or DES in the side branch), with 9.7% of TLR at 1 year (lower in patients who received DES in the side branch compared with those who received BRS in both the main and side branches).[128] In another study from Suarez de Lezo et al. (N=194), where virtually all cases (96%) were treated by the provisional technique, procedural success was 100%, angiographic restenosis at 7.3±1.6 months was 5% and device thrombosis at 14±6 months was 1.3%.[129] In a series of 28 patients from Wiebe et al., there was a very high rate of scaffold thrombosis at 1 year (8.1%), but in this study all patients with scaffold thrombosis had premature antiplatelet therapy discontinuation.[130]

The largest series of BRS for bifurcation lesions (N=289) comes so far from a substudy of the GHOST-EU registry, where a complex strategy was used in 14% of cases.[131] At 1 year, the estimated rates of TLF and stent/scaffold thrombosis were 6.4% and 2.5%, respectively. Independent predictors for TLF were treatment in the context of an ACS and diabetes mellitus.

Diabetes

In the GHOST-EU registry, diabetes mellitus was the only independent predictor of TLF at 6 months.[132] Conversely, in a propensity score matched analysis of BRS and EES from Muramatsu et al, diabetic patients treated with BRS showed similar rates of combined ischemic endpoints compared with nondiabetic patients treated with BRS and diabetic patients treated with EES at 1-year follow-up.[133] In a patient-level meta-analysis of ABSORB II, ABSORB III, ABSORB-CHINA and ABSORB JAPAN encompassing 3,389 patients treated with BRS or EES, diabetes mellitus

independently predicted a number of clinical endpoints at 1 year, including target vessel failure, target vessel MI, ischemia-driven TLR and scaffold thrombosis.[45]

6. ANGIOGRAPHIC OUTCOMES WITH CE-APPROVED BIORESORBABLE SCAFFOLDS

1. Absorb

A number of randomized trials compared outcomes of patients treated with Absorb BRS with conventional metallic DES, and incorporated protocol-mandated angiographic follow-up. The main findings are summarized in **Table 6**.

- In the **ABSORB China** trial the primary endpoint of in-segment late loss at 1 year was 0.19±0.38mm for BRS versus 0.13±0.38mm for EES (one-sided 97.5% upper confidence limit of the difference = 0.14 mm, $P_{noninferiority}$=0.01).[33]
- In **ABSORB-Japan** in-segment late loss at 13 months was 0.13±0.30mm with BRS and 0.12±0.32mm with EES (upper one-sided 95 confidence limit of the difference = 0.07); $P_{non\text{-}inferiority} < 0.0001$).[34, 41]
- Data from the **EVERBIO-II** trial showed that in-stent late loss at 9 months was similar between patients treated with BRS (0.28±0.39 mm) and with EES/BES (0.25±0.36 mm, P= 0.30).[36]
- In the **TROFI II trial** in-stent late loss at 6 months favoured conventional stents (Absorb BRS: 0.17±0.24mm vs. EES: 0.08±0.28mm, P=0.024).[37]
- In the **ABSORB II trial**, the 3-year co-primary endpoints were vasomotor reactivity (powered for superiority) and late lumen loss (powered for non-inferiority). The trial failed to show superiority with respect to vasomotor reactivity at 3 years (Absorb BRS 0.047 mm [SD 0.109] vs EES 0·056 mm [0·117]; P-superiority=0.49) as well as non-

inferiority for the co-primary endpoint of late lumen loss that was larger with Absorb BRS than EES (0.37 mm [0.45] vs. 0.25 mm [0.25]; $P_{non\text{-}inferiority}$=0.78).

Meta-analysis of the four trials with angiographic surveillance scheduled in the time window that is usual for the assessment of conventional metallic DES shows that both in-device and in-segment late loss are significantly higher for the Absorb BRS compared with metallic EES. (see **Figure 5**).[44]

In terms of registry data from routine practice with angiographic follow-up, device performance was broadly in line with clinical trial data with respect to angiographic antirestenotic efficacy. The ISAR-ABSORB registry showed a mean in-stent late loss of 0.26±0.51 in 286 patients undergoing surveillance angiography at a median of 196 days after stenting.[51]

2. DESolve

In the **DESolve Nx trial** at 6-month angiographic follow-up the novolimus-eluting bioresorbable DESolve scaffold showed in-stent late lumen loss of 0.20±0.32 mm.[60]

3. Magmaris

In the **BIOSOLVE-II trial** mean late lumen loss at follow-up with the drug-eluting Magmaris mBRS was somewhat higher than is seen with conventional metallic DES and remained stable between 6 and 12 months: in-segment late lumen loss 0.20±0.21 mm and 0.25±0.22 mm, P = 0.117, delta late loss 0.05±0.21 mm (95% CI: 20.01;0.12); in-scaffold late lumen loss 0.37±0.25 mm vs. 0.39±0.27 mm, P = 0.446, delta late loss 0.03±0.22 (95% CI: 20.04;0.10), respectively.[62, 63]

Figure 5. Meta-analysis of differences in late lumen loss between bioresorbable scaffolds and conventional drug-eluting stents in trials with angiographic surveillance scheduled at 6-12 months follow-up

A In-device late lumen loss

	BVS			EES			Weight	Mean difference
	Mean	(SD)	Total	Mean	(SD)	Total	(%)	(95% CI)
ABSORB China	0·24	(0·39)	240	0·10	(0·32)	246	33·3	0·14 (0·08 to 0·20)
ABSORB Japan	0·19	(0·31)	272	0·16	(0·33)	137	30·4	0·03 (–0·04 to 0·10)
EVERBIO II	0·28	(0·39)	75	0·24	(0·32)	103	11·6	0·04 (–0·07 to 0·15)
TROFI II	0·17	(0·24)	94	0·08	(0·28)	98	24·7	0·09 (0·02 to 0·16)
Overall			**681**			**584**	**100**	**0·08 (0·05–0·12)**

Heterogeneity: χ^2=6·19, df=3; p=0·10; I^2=52%
Test for overall effect: Z=4·42; p<0·0001
Random-effects mean difference 0·08 (95% CI 0·03–0·13)

B In-segment late lumen loss

	BVS			EES			Weight	Mean difference
	Mean	(SD)	Total	Mean	(SD)	Total	(%)	(95% CI)
ABSORB China	0·19	(0·40)	240	0·13	(0·37)	246	31·9	0·06 (–0·01 to 0·13)
ABSORB Japan	0·13	(0·30)	272	0·12	(0·32)	137	36·2	0·01 (–0·05 to 0·07)
EVERBIO II	0·30	(0·44)	75	0·20	(0·43)	103	8·9	0·10 (–0·03 to 0·23)
TROFI II	0·14	(0·28)	94	0·06	(0·29)	98	23·0	0·08 (–0·00 to 0·16)
Overall			**681**			**584**	**100**	**0·05 (0·01–0·09)**

Heterogeneity: χ^2=2·67, df=3; p=0·45; I^2=0%
Test for overall effect: Z=2·54; p=0·01
Random-effects mean difference 0·05 (95% CI 0·01–0·09)

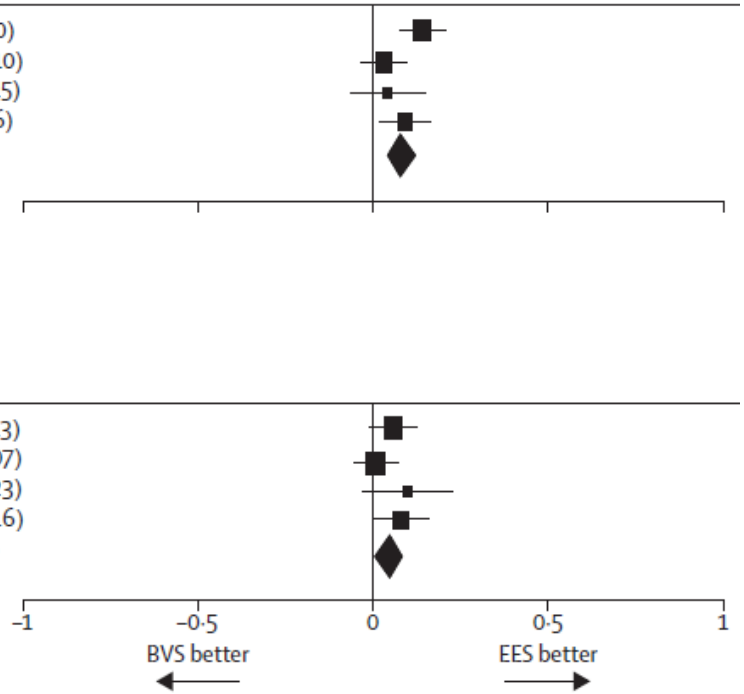

Plots of weighted mean difference in **(A)** in-device and **(B)** in-segment late loss. The boxes/diamonds indicates the point estimate and the left and the right ends of the lines the 95% confidence interval (CI); BVS = Absorb bioresorbable vascular scaffold; EES = everolimus-eluting stent [44]

7. INTRACORONARY IMAGING RESULTS WITH CE-APPROVED BIORESORBABLE SCAFFOLDS

Absorb

The Absorb BRS is the scaffold with the largest number of intracoronary imaging investigations conducted so far. These investigations have contributed greatly to the current understanding of BRS-treated vessels before and after bioresorption,[134, 135] and allowed defining new concepts and surrogate endpoints for subsequent investigations in BRS-treated patients, such as plaque shielding and passivation.[28, 136] OCT has also been instrumental to characterize the mechanisms of very late scaffold thrombosis, including scaffold discontinuity and restenosis during the resorption process (**Figure 4**).[57, 58] OCT-based light intensity analysis and intravascular ultrasound (IVUS)-based echogenicity are well correlated with the process of strut integration into the arterial wall and depolymerization of the strut, respectively, which allows to follow the bioresorption process over time.[137-141] IVUS has a poor capacity to detect qualitative findings after BRS implantation and its reproducibility is low compared with OCT.[142] Conversely, OCT provides correlated measurements of the same order of magnitude as histomorphometry, and is reproducible for the evaluation of vascular and BRS-related characteristics.[143] Since BRS pose unique challenges in OCT quantification and interpretation, a consensus document has been produced to standardize OCT measurements in comparative studies versus EES.[144]

In the ABSORB Cohort A study, 8 patients had IVUS and OCT at 5 years. On IVUS, data showed an increase in mean lumen area between 5 years and 6 months, primarily attributable to a persistent reduction in plaque area size and necrotic core, and there were no signs of endothelial dysfunction with acetylcholine testing.[145] On OCT, in all patients, BRS struts were integrated in the vessel and no longer discernable.[146]

In the ABSORB Cohort B study, 45 patients (Cohort B1) and 56 patients (Cohort B2) underwent serial intravascular imaging with IVUS and OCT at different times.[147] At 6 months, there was a relative 5.4% decrease in minimum luminal area on IVUS, whereas OCT showed that 97% of the struts were already covered.[148] The lack of strut apposition at baseline was uncommon but related to the presence of uncovered struts and intraluminal masses at 6 months.[149] At 1 year, the amount of neointimal proliferation was not different from that of control EES, [150] and related to the patterns of endothelial shear stress, a finding with potential implications for scaffold design.[151] On OCT, in the Cohort B2, malapposition was rare, and strut coverage was detected in 97% of struts.[24] At 2 years, neointima was found to cover the whole circumference of the vessel wall without compromising the luminal dimensions, [152] with 99% of still recognizable struts being covered.[23] At 3 years, there were stable luminal dimensions on IVUS, [153] and OCT showed late discontinuity, an expected fate of BRS at the time of bioresorption, in 40% of cases, with no clinical implications.[59] At 5 years, there were stable lumen dimensions on both IVUS and OCT, with struts no longer discernable [147] and no evidence of edge vascular response. [154]

IVUS sub-studies of the ABSORB II trial have shown that BRS are associated with less acute gain [38, 155] and increased post-procedural asymmetric and eccentric morphology [53] compared to metallic EES. Notably, the finding of more eccentricity compared with EES was at variance with a previous non-randomized study using patients from the ABSORB Cohorts A and B.[156]

Recently two-year OCT follow-up was reported in a subset of patients enrolled in the ABSORB-Japan trial and showed almost fully covered struts, and minimal malapposition nearly complete in both BRS and EES arms. However, the flow area by two-year OCT was smaller in the BRS arm than in the EES arm, mainly due to a higher quantity of tissue growth inside the device.[41]

Finally, in TROFI II, the OCT-defined primary endpoint (healing score) was comparable between BRS and EES, with both devices almost completely healed at 6 months.[37]

DESsolve

In the DESolve first in man trial, 16 patients treated with the myolimus-eluting Elixir pBRS underwent serial IVUS and OCT assessment at baseline and 6 months. At IVUS follow up, neointimal volume was 7%, with no evidence of scaffold recoil or late malapposition. OCT showed uniform, thin neointimal coverage, with 99% of struts covered at follow up. In DESolve NX, 40 and 38 patients treated with the novolimus-eluting pBRS had paired IVUS and OCT images at baseline and 6 months, respectively.[60] On follow up IVUS, there was evidence of a significant increase in lumen and scaffold area compared with baseline. Of the 3 cases of acute incomplete strut apposition seen at baseline, 2 resolved at follow up, and there were no cases of late acquired incomplete scaffold apposition. On OCT, there was a significant increase in mean and minimum scaffold area, and a small decrease in lumen dimensions. Strut coverage was 99% at 6 months and, consistent with the IVUS results, there were no cases of late acquired incomplete scaffold apposition. Signals of ongoing degradation (i.e., struts circumferentially misaligned with respect to adjacent struts, but embedded by neointimal) were observed in 32% of the scaffolds.

Magmaris

In BIOSOLVE-I, paired post-procedural, 6- and 12-month IVUS assessments of the DREAMS 1G scaffold (a former version of the current device) were available in 21 patients.[22] There were significant reductions in scaffold and mean lumen areas at 6- and 12-month follow-up compared with the findings immediately after the procedure, no notable changes in vessel area, and an

increase in plaque area between baseline and 6 months. Taken together, these findings indicate that the most likely explanation for the observed angiographic lumen loss at 6 months (substantially unchanged at 12 months), was the combination of increased extra-scaffold plaque area and neointimal formation rather than negative remodeling. Serial OCT data were available in 7 patients. After the procedure, incompletely apposed struts were 4% of the total number of struts analyzed, suggesting good conformability. At 6 months, the rate of complete apposition was 97%, with persistent incomplete strut apposition noted in 0.6%, and late acquired incomplete strut apposition in 2.2%. At 12 months, 99.8% of struts were apposed with 0.1% persistent incomplete strut apposition and 0.1% late acquired incomplete strut apposition.

In BIOSOLVE-II, featuring the newer generation DREAMS 2G scaffold, IVUS and OCT were performed in a subgroup of 30 patients with pre-procedure, post-procedure and 6-month assessments.[63] Once again, IVUS showed significant reductions in minimum scaffold and lumen areas, no changes in vessel area, and increased total plaque area between post-procedure and 6 months, but preservation of mean scaffold area and lower neointimal area than that shown by DREAMS 1G in BIOSOLVE-I (0.08 mm^2 vs. 0.30 mm^2). Six-month OCT showed significant reductions in mean and minimum lumen areas, and no incompletely apposed struts were detected because all struts were embedded into the vessel wall.

8. RECOMMENDATION FOR DUAL ANTIPLATELET THERAPY IN PATIENTS TREATED WITH BRS

Treatment with dual antiplatelet therapy (DAPT) with aspirin and a P2Y12 inhibitor after BRS implantation is mandatory to mitigate the risk of scaffold thrombosis. Yet, the optimal duration of such DAPT treatment is unknown. The ESC clinical practice guidelines on myocardial revascularization recommend DAPT for a minimum of 6 months after new generation metallic DES implantation, but no specific recommendations are made for BRS.[5] Furthermore, optimal DAPT duration after PCI is currently a matter of debate in the aftermath of a number of large randomized trials reported in recent years, the largest of which was the Dual Antiplatelet Therapy trial.[157] This trial showed that prolonged DAPT beyond one year after DES implantation is associated with a lower risk of stent thrombosis and myocardial infarction but a higher risk of major bleeding.

In considering DAPT regime after BRS a number of aspects have to be considered. Thicker and wider BRS stent struts might confer a higher risk of stent thrombosis in comparison to thin-strut conventional DES. Moreover, thicker stent struts may take longer to completely endothelialize. Importantly, due to concerns regarding scaffold thrombosis late in the course of scaffold degradation at 2-3 years, it is conceivable that the duration of DAPT treatment may need to be prolonged to the time of BRS bioresorption.

The ABSORB II trial constitutes the best evidence on the relationship between extended DAPT duration and scaffold thrombosis at present.[31] At three-year follow-up, 9 patients presented with scaffold thrombosis; six of these cases (78%) presented with late or very late scaffold thrombosis. In all of them, scaffold thrombosis had occurred after discontinuation of DAPT, in most cases

after a long period of antiplatelet monotherapy: in 8 patients (87%) scaffold thrombosis occurred more than 100 days after DAPT was discontinued. Of note, there were no cases of late/very late scaffold thrombosis in the 63 patients in the scaffold arm in whom DAPT was maintained without interruption for 3 years.

Overall, available data suggest that current BRS may require prolonged DAPT to mitigate the risk of late and very late scaffold thrombosis. It is unknown whether use of more potent P2Y12 inhibitors, such as ticagrelor or prasugrel, may have a more protective effect against scaffold thrombosis than DAPT with clopidogrel. As prolonged DAPT confers a higher risk of bleeding events, prolonged DAPT duration will impact net clinical benefit. It is unknown whether de-escalating strategies from ticagrelor or prasugrel to clopidogrel as the P2Y12 included in DAPT might decrease the chances of bleeding while providing better protection against early scaffold thrombosis.

Patients who cannot tolerate or are unlikely to be compliant with extended duration DAPT are not candidates for BRS treatment. Patients with an indication for OAC are not candidates for BRS at this point in time.

In patients who have already been treated with BRS, there are two scenarios to be considered. In patients who remain on DAPT without clinical events, it is recommended to continue DAPT for the duration of bioresorption expected on the basis of existing non-clinical and clinical studies (e.g. at least 36 months in case of pBRS). In patients who have discontinued DAPT prior to this time point, a decision to re-initiate DAPT should be made on a case-by-case basis after evaluation of the thrombotic and bleeding risks.

9. RECOMMENDATIONS FOR CURRENT CLINICAL USE

There are sufficient clinical data to inform recommendations of this Task Force only about the everolimus-eluting Absorb pBRS. Other bioresorbable scaffolds may be used according to ongoing clinical investigations and their outcomes.[158] Of note, data regarding cost-effectiveness do not exist and may differ widely according to each local health care system and reimbursement scheme.

Indications

Current data from randomized trials and meta-analyses compare the everolimus-eluting Absorb pBRS with the metallic EES in patients with predominantly stable coronary artery disease, and with simple to moderately complex lesion characteristics. They suggest similar clinical efficacy at one year, as it relates to the risk of target lesion revascularization and to the device-oriented composite outcome TLF. However, the risks of target-vessel MI and definite or probable stent/scaffold thrombosis are increased in patients treated with the Absorb BRS. Moreover, late outcomes out to 2-3 years suggest an excess of very late stent/scaffold thrombosis, target vessel MI, and TLF, with BRS versus metallic EES. Current evidence suggests no late advantage in terms of clinical efficacy including relief of angina pectoris. Thus the Task Force has the following recommendations for the clinical use of BRS as an alternative to conventional metallic DES:

General recommendations for clinical use of approved devices

- As long as concerns regarding long-term clinical safety (i.e. MI, stent/scaffold thrombosis) have not been dispelled by ongoing clinical trials or prospective, monitored registries, BRS should not be preferred to current generation metallic DES for routine clinical use

- Ongoing trials should be closely monitored for adverse events and data should be made available at regular intervals in the public domain, irrespective of the initial analysis plan
- It is not recommended to use BRS in patients who cannot tolerate or are unlikely to be compliant with extended duration DAPT or who require oral anticoagulants

Device implantation

Consistent observations point to the differences in mechanical properties of BRS compared with metallic DES. This mandates meticulous assessment and preparation of the lesion, and also frequent use of pre- and post-dilatation. As a result, procedure duration and contrast use are increased and the cross-over to metallic DES is more common. Moreover, acute performance, as assessed by acute gain and percent diameter stenosis, as well as longer term (6-36 months) angiographic results, assussed as in-device late lumen loss, are both inferior for BRS as compared with metallic DES.

In view of these observations, this Task Force has the following recommendations regarding device implantation:

- It is recommended that BRS are implanted by appropriately trained operators with specific experience in the implantation of these devices.

Lesion Assessment

- BRS require careful lesion assessment, to determine the need and extent of lesion preparation, as well as to select the appropriate size and length of the device. The use of pre-and post-procedural intracoronary imaging (IVUS, OCT), as well as online quantitative

coronary angiography, is encouraged to optimize device implantation. The use of BRS in calcified vessels is strongly discouraged. BRS should be avoided in stenoses with reference diameter smaller than 2.5 mm.

Pre-dilation

- It is recommended to systematically predilate lesions with non-compliant balloons, aiming at a balloon diameter corresponding to the estimated reference vessel diameter.
- Complete balloon expansion should be ensured, in orthogonal angiographic projections.
- In case of incomplete balloon expansion during pre-dilation, use of plaque modification techniques (cutting/scoring balloon, rotational atherectomy) should be considered prior to BRS insertion.
- It is recommended to refrain from BRS implantation in cases where balloon expansion remains incomplete despite plaque modification techniques.

Implantation Technique

- If more than one device needs to be implanted due to lesion length, incomplete lesion coverage or edge dissections, additional devices may be implanted by carefully avoiding excessive stent overlap. An abutting technique (device-to-device) should be preferred in patients needing more than one stent.

Post-Dilatation

- High-pressure (>16 bar) post-dilatation using non-compliant balloons should be done routinely, with nominal balloon diameter not exceeding 0.5 mm above the nominal diameter of the device.

Device Failure

In cases of scaffold thrombosis it is recommended that intravascular imaging be performed, preferably with OCT, after restoration of normal vessel flow. This may provide insight into the mechanisms underlying the scaffold thrombosis and potentially guide therapy. In most cases, implantation of a conventional DES will be the preferred strategy to restore vessel patency.

10. RECOMMENDATIONS FOR EVALUATION PLAN FOR BIORESORBABLE SCAFFOLDS

A key question in the development and evaluation of current and new BRS is how best to identify parameters that will reliably predict the clinical complications encountered.

The Task Force recommends that bench testing of the biodegradable scaffold backbone should include two components: (i) characterization of the finished product and (ii) mechanical testing.

Currently, there are no established standards, FDA Guidance Document or MEDDEV documents addressing non-clinical test requirements for BRS. However, the risks associated with such products have been identified, based on both pre-clinical and clinical experiences from the

currently marketed products and from products that are under investigational use. This section provides recommendations for the non-clinical testing of BRS.

Bench Testing

Full characterization of the finished product is important. All the following characteristics should be studied and defined:

- Molecular weight (MW)
- The molecular weight distribution (PDI)
- Percent crystallinity (χ_c, if applicable)
- Melting temperature (T_m, if applicable)
- Glass transition temperature (T_g)
- Residual monomer content
- Residual free radicals (if applicable)
- Structural integrity
- Mass loss
- Degradation products

Mechanical testing should be performed under environmental conditions that mimic physiological ones, to capture the effect of degradation on mechanical integrity over time. The results of characterization may impact all aspects of product evaluation such as type of testing and timing of assessments. For example, acceleration of mechanical loading should be synchronized with accelerated degradation for accelerated durability testing. The duration of the accelerated fatigue testing should be determined through time of complete tissue coverage as

determined by in vivo or in vitro degradation studies. Particulates testing should be performed through time of significant mass loss of the polymer.

Biocompatibility

Biocompatibility testing should be performed as recommended in the ISO standard "Use of International Standard ISO-10993, "Biological Evaluation of Medical Devices Part 1: Evaluation and Testing." However, there may be a need to alter some of the standard tests (e.g. extraction conditions, exposure times). It is also recommended that biocompatibility testing should be performed separately on degradation products. The following standards should be considered for the biocompatibility evaluation of the BRS:

- ISO/TS 12417:2011
- ISO/DIS 12417-1
- ISO/TR 37137:2014
- ISO/TS 17137:2014

FDA Draft Guidance Document entitled "Use of International Standard ISO-10993" provides further clarification and updated information on the use of International Standard ISO-10993, "Biological Evaluation of Medical Devices Part 1: Evaluation and Testing".[159] This Draft FDA Guidance incorporates information on the in vivo polymerizing and bioabsorbable materials.

In Vivo Testing

Animal models

To date, the preferable animal model for the assessment of coronary stents has been the *domestic crossbred or miniature swine model* or the *rabbit iliac artery model;* because their size, access, and injury response appear to be similar to human vessels, they may be suitable for assessing safety before human use [160]. In some situations the sheep model may also be used. Comparative studies are encouraged to reflect both safety and biological responses appropriately. Standard contemporary anti-platelet therapy should be utilized in all animal models. As a general rule, preclinical testing should be performed within the intended vascular territory, although there may be instances in which a switch to a different vascular location may provide valuable information about the biological behaviour of stents owing to the differential reaction to vascular injury among species and vascular territories.

Porcine/Rabbit Models

The mature (non-juvenile) normolipidemic porcine coronary artery is the most frequently used and widely accepted animal model to study the outcome of coronary stents[160]. Miniature swine should be considered when long-term studies are performed, to allow for the impact of animal growth over time. Stents should be appropriately sized for the target vessel with the targeted device-to-artery ratio between 1.0 to 1.2. Online QCA should be used for sizing, of images acquired after giving nitrate. In addition to the assessment of safety aspects, a general appreciation of efficacy should be reflected in preclinical study design. This can be achieved best by including approved comparators with known clinical efficacy.

An advantage of the rabbit iliac artery model is that it is associated with low variability in injury and inflammation after scaffold implantation, which is useful when assessing biocompatibility and safety of investigational devices. Especially for studies focused on re-endothelialization of devices, the rabbit model may provide important advantages over swine, as the time taken for re-endothelialization is longer. [161, 162]

Planning and conducting preclinical studies in animals

Generally, preclinical animal studies including histopathological assessment should be performed in designated preclinical animal facilities with Good Laboratory Practice (GLP) certification. Each artery should only receive one test device, except when overlapping or repeated treatment is intended. One or more arteries may be treated in a single animal depending on the specific study design.

In general, study design must include appropriate controls to appreciate treatment effects especially with regards to safety and biocompatibility. When polymer-coated stents are investigated, appropriate controls consisting of either the full-component device or polymer-only coated devices should be included. In our view, the ideal control should consist of a currently accepted standard of care in the specific indication for which the test product will be used clinically. A minimum of 6-8 samples should be included per treatment group, in standard histopathological safety studies, and in pharmacokinetic and degradation studies of BRS. For metallic stents, a standard 28 days follow-up should be combined with a later time point of follow up of at least 90 days to capture more safety-relevant biological responses. For BRS, critical time points of follow-up will depend on the pace of biodegradation.

Standards for evaluation

1. Necropsy evaluation

Thorough necropsy evaluation is key to a successful assessment of device safety and biological response. Premature and unexpected deaths need to undergo complete necropsy, including gross examination of organs, and tissue and histopathologic examination.

2. Tissue processing and fixation

Ideally, pressure-fixation at about 100mmHg with rapid exsanguination should be performed. Following fixation, organs and vessels should be sectioned transaxially at a minimum of 5mm intervals, resulting in a minimum of 3 sections per stented segment (proximal, middle, distal) depending on the total length of the organ/vessel.

3. Histopathology

Histomorphometry: Standard measurements have been described previously [160] and should include medial area, area within the external and internal elastic lamina, lumen area, and stent area. Neointimal area and percent area stenosis can be calculated from the above-mentioned areas. In addition, neointimal thickness should be measured above and between stent struts. With respect to the assessment of BRS it is important to emphasize luminal dimensions during degradation.

Special care is needed for the assessment of BRS. Acute and chronic inflammation should be judged on the basis of acute and chronic inflammatory cells, which mostly consist of neutrophils/monocytes acutely and lymphocytes/macrophages chronically for clearing of biodegradation products. Similarly, standard injury scores may be misleading at longer-term follow-up as destruction of the internal elastic lamina may result from inflammation rather than reflecting vascular residues of acute injury sustained at the time of stent implantation. Furthermore, special efforts should be made to characterize the change in tissue composition

during biodegradation by histopathology, focussing on both the extent and the nature of neointimal tissue especially at the remnant sites of stent struts. Correlation with intravascular imaging may be helpful in understanding changes in tissue composition.

4. Clinical observations and blood tests

Monitoring of general health, body temperature and body weight are important. Blood parameters of overall organ function are important before initiation of the study and at regular intervals thereafter.

5. Overlapping stents and long stents

For the assessment of BRS, overlapping stent studies are strongly recommended. These tests are important for two reasons. Firstly, mechanical issues (e.g. fatigue) occurring at the site of overlapping stents must be evaluated and any excess injury and inflammation investigated. Secondly, synergistic effects of stent coatings (i.e. carrier matrix and/or drug) in overlapping stents need to be carefully investigated to exclude potential adverse reactions arising from local accumulation and release into the surrounding tissue. Specific clinical safety aspects of overlapping BRS struts include fracture, particulate embolization, thrombus formation, and delayed healing (i.e. endothelialisation etc.).

6. Intravascular imaging

IVUS and OCT are important tools in the assessment of coronary stents [163-167]. They allow for the evaluation of important *in vivo* parameters of healing such as stent strut coverage, neointima formation, malapposition and thrombus formation. However, intravascular imaging may cause substantial tissue damage (i.e. endothelial loss or injury), that may be interpreted inappropriately during histopathological assessment of stents. Intravascular imaging is strongly recommended in a subset of animals in studies of BRS, in order that stent degradation and physiological vessel

dimensions can be evaluated over time.[138, 168] Measurements should be adjusted using reference area, to compensate for growth during the study.[169, 170]

7. Time point of follow up

In general, follow-up should capture all relevant biological processes pertaining to stent safety. If drug elution is complete by 90 days, follow-up should be done to 180 days. If biodegradation of stents or stent components takes 1 year, time points beyond the 1-year frame may be necessary to appropriately assess device safety. The addition of a late time point after bioresorption is complete may be needed to document patency of the vessel, extent of neointimal growth, and presence or absence of inflammation.

8. In vitro and in vivo pharmacokinetics and dose finding

Release of drug from coronary stents should be examined in vitro and in vivo. In vitro investigation should serve the purpose of establishing the order of release kinetic and determination of complete release. For the examination of in vivo release kinetics, several methods of determination should be applied. Drug release can be examined by direct chemical determination or by use of radioactively labelled agents. First pass metabolism should be evaluated by examination of drug elimination in urine. As there may be substantial variability in drug concentrations measured in tissue, depending on the methods applied, a minimum of 6 different samples from each device at a minimum of 5 time points is recommended. The last sample should provide evidence that drug concentrations are below the level of detection. Drug concentrations in blood and major organs must also be determined, including myocardium downstream in the territory of the target artery. The dose proposed for clinical use should be justified by preclinical data; thus, preclinical dose-ranging studies are strongly recommended, to establish biological effects from sub-therapeutic to toxic levels.

9. Biochemical analysis of degradation products

In general, degradation products need to be clearly defined with respect to their physicochemical structure and in vivo biological behaviour. With regards to the evaluation of polymeric components, gel permeation chromatography is a suitable analytical method to assess molecular weight and polydispersity index; these provide important insights into the degradation process of the stent and help explain observed biological behaviour. In this regard, it is important to correlate results from bioengineering tests with results from in vitro and in vivo degradation analyses, to facilitate understanding of scaffolding function. For the assessment of mBRS, other technologies may be applied to examine degradation products appropriately, such as chemical analysis, micro CT analysis, and scanning electron microscopy with element analysis.

10. Special considerations for the assessment of multi-component devices

Special attention is needed when it comes to assessing the safety of multi-component devices that employ bioresorbable stent backbones with either permanent or biodegradable coatings of different origin compared to the stent backbone. In these instances it is strongly recommended to investigate all stent components separately and also as the full-component device. The interaction of degradation processes among the different stent components needs to be defined as closely as possible.

11. CLINICAL EVALUATION PLAN

At present there are important differences in the regulatory approval systems worldwide and in particular between Europe, the United States and Japan. This means, for example, that four BRS devices are currently approved for use in Europe whereas only one device is approved in the United States and Japan. (see **Table 1**).

Many of the potential risks associated with BRS can be anticipated based on non-clinical evaluation. Only devices with satisfactory non-clinical assessment should undergo clinical evaluation. The Task Force suggests evaluation of current and future devices according to a standard plan; an overview is shown in **Figure 6**. In general, where recommendations are made with regard to the numbers of patients to be enrolled, at least 50% of these patients should be enrolled in Europe.

Initial human feasibility studies with BRS should be small-sized (N=50-150), performed in selected patients, and including IVUS and/or OCT imaging in addition to angiographic and clinical follow-up (see **Figure 6**). These studies should support the claim of efficacy and safety but also provide detailed information regarding vessel-device interactions and bioresorption process. In this regard, angiography and intracoronary imaging protocols should include assessment at baseline, at 6-12 months after device implantation, and at the time of claimed complete resorption (if longer than 12 months). Imaging can be performed at various time points in different populations in order to reduce the burden of serial invasive imaging assessment. These initial human studies may be planned as single arm, prospective, observational studies. In addition, it may be reasonable to compare the performance of investigational BRS against angiographic and clinical benchmarks derived from trials of conventional DES – using objective

performance criteria (OPC) in a manner similar to that detailed in the earlier report of the Task Force on coronary stents.[1] Such comparison may identify devices not suitable for further investigation in larger trials. Imaging surveillance protocols with non-invasive modalities such as computer tomography may be appropriate as supplementary evaluation in certain circumstances.

Figure 6. Task Force recommended clinical evaluation plan

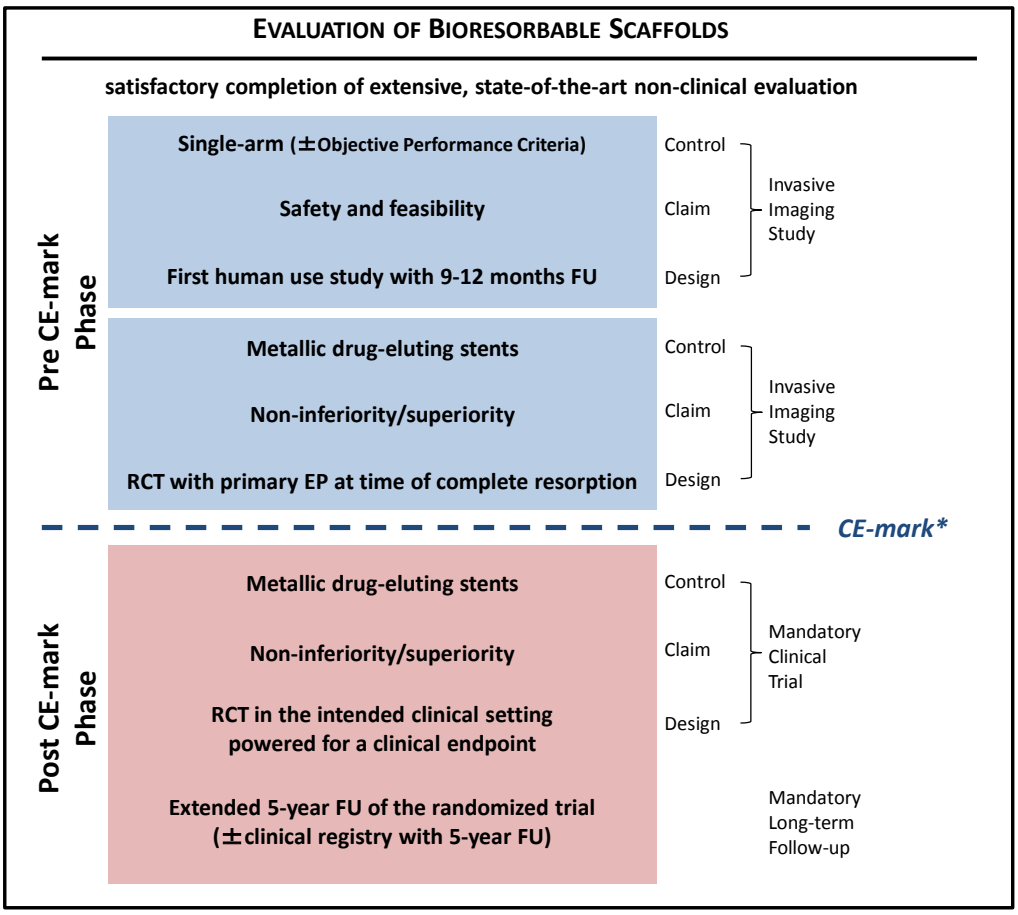

EP = endpoint; FU = follow-up; RCT = randomized controlled trial; * the manufacturer must submit and have approved by the notified body a plan for post-market clinical follow up in the form of a large-scale, randomized trial ± a large-scale clinical registry

Subsequently a medium-sized, randomized trial (N=200-500) should be undertaken, powered for the detection of differences in surrogate endpoints in comparison with existing control devices. This should be based on angiographic surveillance at 6-12 months follow-up and include intracoronary imaging in a subgroup of patients (N=50-100) to compare arterial healing properties. Control devices should be contemporary metallic DES, ideally releasing a similar antiproliferative drug with a pharmacokinetic release profile similar to that of the investigational device. It is not sufficient to compare the investigational BRS against another BRS technology at this point in time, as the performance of conventional DES make these devices the most appropriate comparator. Surveillance angiography and intracoronary imaging during later time points (2-5 years) may evaluate delayed late loss and changes in response to the complete resorption of the BRS.

As a minimum requirement, both of these steps should be completed with satisfactory results, before any new BRS is approved and granted a certificate of compliance with the essential requirements of the EU device regulations, leading to a CE mark. As part of this process, the manufacturer must submit and have approved by the notified body a plan for post-market clinical follow up; in the case of BRS this plan should include the conduct of a large-scale, randomized trial, in order to assess long-term clinical efficacy and safety. Most commonly this will involve comparative efficacy testing against a benchmark device in a trial powered for a device- or patient-specific outcome (usually requiring a sample of 1500-2500 patients) (see **Figure 6**). Data collection and analysis from a large-scale clinical registry including patients with broader inclusion criteria and long-term follow-up may also be requested (see **Figure 6**).

An alternative concept would be conditional approval, with continuing market access being dependent on the conduct and satisfactory completion and reporting of a large-scale trial, but we recognize that this mechanism is not included in the new European Union Medical Device Regulation.

This Task Force recommends that BRS should be evaluated against established conventional metallic DES, for the reasons mentioned above. A non-inferiority design for the assessment of outcomes within one year would be acceptable, but sequential designs combining non-inferiority at 1 year followed by superiority during longer-term follow-up (3-5 years) are recommended in order to evaluate the long-term effects of BRS. A device-oriented composite endpoint – typically TLF – combines safety and efficacy and is commonly used in device-versus-device comparisons of DES. Primary endpoint assessment should be performed at 9-12 months, in analogy to DES. Thereafter yearly follow-up out to 5 years is recommended in order to detect any late adverse event. A later time point of primary endpoint assessment at 2, 3 or 5 years may also be considered particularly in view of the specific bioresorption profile of any given device. The assessment of stent/scaffold thrombosis – according to established definitions for conventional metallic DES [171] – should be performed at each time point of assessment. During the conduct of trials in the post CE mark approval phase, the Task Force recommends that provision be advised for device reimbursement by payers at the price of the equivalent treatment (conventional metallic DES).

References

1. Byrne RA, Serruys PW, Baumbach A, Escaned J, Fajadet J, James S, Joner M, Oktay S, Juni P, Kastrati A, Sianos G, Stefanini GG, Wijns W, Windecker S. Report of a European Society of Cardiology-European Association of Percutaneous Cardiovascular Interventions task force on the evaluation of coronary stents in Europe: executive summary. Eur Heart J 2015;**36**(38):2608-20.
2. Stefanini GG, Baber U, Windecker S, Morice MC, Sartori S, Leon MB, Stone GW, Serruys PW, Wijns W, Weisz G, Camenzind E, Steg PG, Smits PC, Kandzari D, Von Birgelen C, Galatius S, Jeger RV, Kimura T, Mikhail GW, Itchhaporia D, Mehta L, Ortega R, Kim HS, Valgimigli M, Kastrati A, Chieffo A, Mehran R. Safety and efficacy of drug-eluting stents in women: a patient-level pooled analysis of randomised trials. Lancet 2013;**382**(9908):1879-88.
3. Tada T, Byrne RA, Simunovic I, King LA, Cassese S, Joner M, Fusaro M, Schneider S, Schulz S, Ibrahim T, Ott I, Massberg S, Laugwitz KL, Kastrati A. Risk of stent thrombosis among bare-metal stents, first-generation drug-eluting stents, and second-generation drug-eluting stents: results from a registry of 18,334 patients. JACC Cardiovasc Interv 2013;**6**(12):1267-74.
4. Raber L, Magro M, Stefanini GG, Kalesan B, van Domburg RT, Onuma Y, Wenaweser P, Daemen J, Meier B, Juni P, Serruys PW, Windecker S. Very late coronary stent thrombosis of a newer-generation everolimus-eluting stent compared with early-generation drug-eluting stents: a prospective cohort study. Circulation 2012;**125**(9):1110-21.
5. Windecker S, Kolh P, Alfonso F, Collet JP, Cremer J, Falk V, Filippatos G, Hamm C, Head SJ, Juni P, Kappetein AP, Kastrati A, Knuuti J, Landmesser U, Laufer G, Neumann FJ, Richter DJ, Schauerte P, Sousa Uva M, Stefanini GG, Taggart DP, Torracca L, Valgimigli M, Wijns W, Witkowski A, Authors/Task Force m. 2014 ESC/EACTS Guidelines on myocardial revascularization: The Task Force on Myocardial Revascularization of the European Society of Cardiology (ESC) and the European Association for Cardio-Thoracic Surgery (EACTS)Developed with the special contribution of the European Association of Percutaneous Cardiovascular Interventions (EAPCI). Eur Heart J 2014;**35**(37):2541-619.
6. Task Force M, Montalescot G, Sechtem U, Achenbach S, Andreotti F, Arden C, Budaj A, Bugiardini R, Crea F, Cuisset T, Di Mario C, Ferreira JR, Gersh BJ, Gitt AK, Hulot JS, Marx N, Opie LH, Pfisterer M, Prescott E, Ruschitzka F, Sabate M, Senior R, Taggart DP, van der Wall EE, Vrints CJ, Guidelines ESCCfP, Zamorano JL, Achenbach S, Baumgartner H, Bax JJ, Bueno H, Dean V, Deaton C, Erol C, Fagard R, Ferrari R, Hasdai D, Hoes AW, Kirchhof P, Knuuti J, Kolh P, Lancellotti P, Linhart A, Nihoyannopoulos P, Piepoli MF, Ponikowski P, Sirnes PA, Tamargo JL, Tendera M, Torbicki A, Wijns W, Windecker S, Document R, Knuuti J, Valgimigli M, Bueno H, Claeys MJ, Donner-Banzhoff N, Erol C, Frank H, Funck-Brentano C, Gaemperli O, Gonzalez-Juanatey JR, Hamilos M, Hasdai D, Husted S, James SK, Kervinen K, Kolh P, Kristensen SD, Lancellotti P, Maggioni AP, Piepoli MF, Pries AR, Romeo F, Ryden L, Simoons ML, Sirnes PA, Steg PG, Timmis A, Wijns W, Windecker S, Yildirir A, Zamorano JL. 2013 ESC guidelines on the management of stable coronary artery disease: the Task Force on the management of stable coronary artery disease of the European Society of Cardiology. Eur Heart J 2013;**34**(38):2949-3003.
7. Roffi M, Patrono C, Collet JP, Mueller C, Valgimigli M, Andreotti F, Bax JJ, Borger MA, Brotons C, Chew DP, Gencer B, Hasenfuss G, Kjeldsen K, Lancellotti P, Landmesser U, Mehilli J, Mukherjee D, Storey RF, Windecker S, Baumgartner H, Gaemperli O, Achenbach S, Agewall S, Badimon L, Baigent C, Bueno H, Bugiardini R, Carerj S, Casselman F, Cuisset T, Erol C, Fitzsimons D, Halle M, Hamm C, Hildick-Smith D, Huber K, Iliodromitis E, James S, Lewis BS, Lip GY, Piepoli MF, Richter D, Rosemann T, Sechtem U, Steg PG, Vrints C, Luis Zamorano J, Management of Acute Coronary Syndromes in Patients Presenting without Persistent STSEotESoC. 2015 ESC Guidelines for the management of acute coronary syndromes in patients presenting without persistent ST-segment elevation: Task

Force for the Management of Acute Coronary Syndromes in Patients Presenting without Persistent ST-Segment Elevation of the European Society of Cardiology (ESC). Eur Heart J 2016;**37**(3):267-315.

8. Serruys PW, Garcia-Garcia HM, Onuma Y. From metallic cages to transient bioresorbable scaffolds: change in paradigm of coronary revascularization in the upcoming decade? Eur Heart J 2012;**33**(1):16-25b.

9. Iqbal J, Onuma Y, Ormiston J, Abizaid A, Waksman R, Serruys P. Bioresorbable scaffolds: rationale, current status, challenges, and future. Eur Heart J 2014;**35**(12):765-76.

10. Wiebe J, Nef HM, Hamm CW. Current status of bioresorbable scaffolds in the treatment of coronary artery disease. J Am Coll Cardiol 2014;**64**(23):2541-51.

11. Shalaby SW, Burg KJL. *Absorbable and biodegradable polymers (advances in polymeric biomaterials)*. 1st edition ed: CRC Press; 2003.

12. Vert M. Bioabsorbable polymers in medicin: an overview. EuroIntervention 2009;**5**(Supplement F):F9-F14.

13. Rep.15351 CT. Plastics Guide for vocabulary in the field of degradable and biodegradable polymers and plastic items. In; 2006.

14. Brener SJ, Kereiakes DJ, Simonton CA, Rizvi A, Newman W, Mastali K, Wang JC, Caputo R, Smith RS, Jr., Ying SW, Cutlip DE, Stone GW. Everolimus-eluting stents in patients undergoing percutaneous coronary intervention: final 3-year results of the Clinical Evaluation of the XIENCE V Everolimus Eluting Coronary Stent System in the Treatment of Subjects With de Novo Native Coronary Artery Lesions trial. Am Heart J 2013;**166**(6):1035-42.

15. Kufner S, Sorges J, Mehilli J, Cassese S, Repp J, Wiebe J, Lohaus R, Lahmann A, Rheude T, Ibrahim T, Massberg S, Laugwitz KL, Kastrati A, Byrne RA, Investigators I-T-. Randomized Trial of Polymer-Free Sirolimus- and Probucol-Eluting Stents Versus Durable Polymer Zotarolimus-Eluting Stents: 5-Year Results of the ISAR-TEST-5 Trial. JACC Cardiovasc Interv 2016;**9**(8):784-92.

16. Maeng M, Tilsted HH, Jensen LO, Krusell LR, Kaltoft A, Kelbaek H, Villadsen AB, Ravkilde J, Hansen KN, Christiansen EH, Aaroe J, Jensen JS, Kristensen SD, Botker HE, Thuesen L, Madsen M, Thayssen P, Sorensen HT, Lassen JF. Differential clinical outcomes after 1 year versus 5 years in a randomised comparison of zotarolimus-eluting and sirolimus-eluting coronary stents (the SORT OUT III study): a multicentre, open-label, randomised superiority trial. Lancet 2014;**383**(9934):2047-56.

17. Stone GW, Maehara A, Lansky AJ, de Bruyne B, Cristea E, Mintz GS, Mehran R, McPherson J, Farhat N, Marso SP, Parise H, Templin B, White R, Zhang Z, Serruys PW, Investigators P. A prospective natural-history study of coronary atherosclerosis. N Engl J Med 2011;**364**(3):226-35.

18. Raber L, Wohlwend L, Wigger M, Togni M, Wandel S, Wenaweser P, Cook S, Moschovitis A, Vogel R, Kalesan B, Seiler C, Eberli F, Luscher TF, Meier B, Juni P, Windecker S. Five-year clinical and angiographic outcomes of a randomized comparison of sirolimus-eluting and paclitaxel-eluting stents: results of the Sirolimus-Eluting Versus Paclitaxel-Eluting Stents for Coronary Revascularization LATE trial. Circulation 2011;**123**(24):2819-28, 6 p following 2828.

19. Byrne RA, Iijima R, Mehilli J, Pinieck S, Bruskina O, Schomig A, Kastrati A. Durability of antirestenotic efficacy in drug-eluting stents with and without permanent polymer. JACC Cardiovasc Interv 2009;**2**(4):291-9.

20. Natsuaki M, Morimoto T, Furukawa Y, Nakagawa Y, Kadota K, Yamaji K, Ando K, Shizuta S, Shiomi H, Tada T, Tazaki J, Kato Y, Hayano M, Abe M, Tamura T, Shirotani M, Miki S, Matsuda M, Takahashi M, Ishii K, Tanaka M, Aoyama T, Doi O, Hattori R, Kato M, Suwa S, Takizawa A, Takatsu Y, Shinoda E, Eizawa H, Takeda T, Lee JD, Inoko M, Ogawa H, Hamasaki S, Horie M, Nohara R, Kambara H, Fujiwara H, Mitsudo K, Nobuyoshi M, Kita T, Kimura T, investigators CR-KPCrc-. Late adverse events after implantation of sirolimus-eluting stent and bare-metal stent: long-term (5-7 years) follow-up

of the Coronary Revascularization Demonstrating Outcome study-Kyoto registry Cohort-2. Circ Cardiovasc Interv 2014;**7**(2):168-79.

21. Otsuka F, Byrne RA, Yahagi K, Mori H, Ladich E, Fowler DR, Kutys R, Xhepa E, Kastrati A, Virmani R, Joner M. Neoatherosclerosis: overview of histopathologic findings and implications for intravascular imaging assessment. Eur Heart J 2015;**36**(32):2147-59.

22. Haude M, Erbel R, Erne P, Verheye S, Degen H, Bose D, Vermeersch P, Wijnbergen I, Weissman N, Prati F, Waksman R, Koolen J. Safety and performance of the drug-eluting absorbable metal scaffold (DREAMS) in patients with de-novo coronary lesions: 12 month results of the prospective, multicentre, first-in-man BIOSOLVE-I trial. Lancet 2013;**381**(9869):836-44.

23. Ormiston JA, Serruys PW, Onuma Y, van Geuns RJ, de Bruyne B, Dudek D, Thuesen L, Smits PC, Chevalier B, McClean D, Koolen J, Windecker S, Whitbourn R, Meredith I, Dorange C, Veldhof S, Hebert KM, Rapoza R, Garcia-Garcia HM. First serial assessment at 6 months and 2 years of the second generation of absorb everolimus-eluting bioresorbable vascular scaffold: a multi-imaging modality study. Circ Cardiovasc Interv 2012;**5**(5):620-32.

24. Serruys PW, Onuma Y, Dudek D, Smits PC, Koolen J, Chevalier B, de Bruyne B, Thuesen L, McClean D, van Geuns RJ, Windecker S, Whitbourn R, Meredith I, Dorange C, Veldhof S, Hebert KM, Sudhir K, Garcia-Garcia HM, Ormiston JA. Evaluation of the second generation of a bioresorbable everolimus-eluting vascular scaffold for the treatment of de novo coronary artery stenosis: 12-month clinical and imaging outcomes. J Am Coll Cardiol 2011;**58**(15):1578-88.

25. Serruys PW, Ormiston JA, Onuma Y, Regar E, Gonzalo N, Garcia-Garcia HM, Nieman K, Bruining N, Dorange C, Miquel-Hebert K, Veldhof S, Webster M, Thuesen L, Dudek D. A bioabsorbable everolimus-eluting coronary stent system (ABSORB): 2-year outcomes and results from multiple imaging methods. Lancet 2009;**373**(9667):897-910.

26. Gupta V, Grande-Allen KJ. Effects of static and cyclic loading in regulating extracellular matrix synthesis by cardiovascular cells. Cardiovasc Res 2006;**72**(3):375-83.

27. Waksman R, Prati F, Bruining N, Haude M, Bose D, Kitabata H, Erne P, Verheye S, Degen H, Vermeersch P, Di Vito L, Koolen J, Erbel R. Serial Observation of Drug-Eluting Absorbable Metal Scaffold: Multi-Imaging Modality Assessment. Circ Cardiovasc Interv 2013.

28. Brugaletta S, Radu MD, Garcia-Garcia HM, Heo JH, Farooq V, Girasis C, van Geuns RJ, Thuesen L, McClean D, Chevalier B, Windecker S, Koolen J, Rapoza R, Miquel-Hebert K, Ormiston J, Serruys PW. Circumferential evaluation of the neointima by optical coherence tomography after ABSORB bioresorbable vascular scaffold implantation: can the scaffold cap the plaque? Atherosclerosis 2012;**221**(1):106-12.

29. Onuma Y, Serruys PW. Bioresorbable scaffold: the advent of a new era in percutaneous coronary and peripheral revascularization? Circulation 2011;**123**(7):779-97.

30. Durand E, Sharkawi T, Leclerc G, Raveleau M, van der Leest M, Vert M, Lafont A. Head-to-head comparison of a drug-free early programmed dismantling polylactic acid bioresorbable scaffold and a metallic stent in the porcine coronary artery: six-month angiography and optical coherence tomographic follow-up study. Circ Cardiovasc Interv 2014;**7**(1):70-9.

31. Serruys PW, Chevalier B, Sotomi Y, Cequier A, Carrie D, Piek JJ, Van Boven AJ, Dominici M, Dudek D, McClean D, Helqvist S, Haude M, Reith S, de Sousa Almeida M, Campo G, Iniguez A, Sabate M, Windecker S, Onuma Y. Comparison of an everolimus-eluting bioresorbable scaffold with an everolimus-eluting metallic stent for the treatment of coronary artery stenosis (ABSORB II): a 3 year, randomised, controlled, single-blind, multicentre clinical trial. Lancet 2016;**388**(10059):2479-2491.

32. Ellis SG, Kereiakes DJ, Metzger DC, Caputo RP, Rizik DG, Teirstein PS, Litt MR, Kini A, Kabour A, Marx SO, Popma JJ, McGreevy R, Zhang Z, Simonton C, Stone GW, Investigators AI. Everolimus-Eluting Bioresorbable Scaffolds for Coronary Artery Disease. N Engl J Med 2015;**373**(20):1905-15.

33. Gao R, Yang Y, Han Y, Huo Y, Chen J, Yu B, Su X, Li L, Kuo HC, Ying SW, Cheong WF, Zhang Y, Su X, Xu B, Popma JJ, Stone GW, Investigators AC. Bioresorbable Vascular Scaffolds Versus Metallic Stents in Patients With Coronary Artery Disease: ABSORB China Trial. J Am Coll Cardiol 2015;**66**(21):2298-309.

34. Kimura T, Kozuma K, Tanabe K, Nakamura S, Yamane M, Muramatsu T, Saito S, Yajima J, Hagiwara N, Mitsudo K, Popma JJ, Serruys PW, Onuma Y, Ying S, Cao S, Staehr P, Cheong WF, Kusano H, Stone GW, Investigators AJ. A randomized trial evaluating everolimus-eluting Absorb bioresorbable scaffolds vs. everolimus-eluting metallic stents in patients with coronary artery disease: ABSORB Japan. Eur Heart J 2015;**36**(47):3332-42.

35. Wykrzykowska JJ, Kraak RP, Hofma SH, van der Schaaf RJ, Arkenbout EK, AJ IJ, Elias J, van Dongen IM, Tijssen RY, Koch KT, Baan J, Jr., Vis MM, de Winter RJ, Piek JJ, Tijssen JG, Henriques JP, Investigators A. Bioresorbable Scaffolds versus Metallic Stents in Routine PCI. N Engl J Med 2017.

36. Puricel S, Arroyo D, Corpataux N, Baeriswyl G, Lehmann S, Kallinikou Z, Muller O, Allard L, Stauffer J-C, Togni M, Goy J-J, Cook S. Comparison of Everolimus- and Biolimus-Eluting Coronary Stents With Everolimus-Eluting Bioresorbable Vascular Scaffolds. Journal of the American College of Cardiology 2015;**65**(8):791-801.

37. Sabate M, Windecker S, Iniguez A, Okkels-Jensen L, Cequier A, Brugaletta S, Hofma SH, Raber L, Christiansen EH, Suttorp M, Pilgrim T, Anne van Es G, Sotomi Y, Garcia-Garcia HM, Onuma Y, Serruys PW. Everolimus-eluting bioresorbable stent vs. durable polymer everolimus-eluting metallic stent in patients with ST-segment elevation myocardial infarction: results of the randomized ABSORB ST-segment elevation myocardial infarction-TROFI II trial. Eur Heart J 2016;**37**(3):229-40.

38. Serruys PW, Chevalier B, Dudek D, Cequier A, Carrie D, Iniguez A, Dominici M, van der Schaaf RJ, Haude M, Wasungu L, Veldhof S, Peng L, Staehr P, Grundeken MJ, Ishibashi Y, Garcia-Garcia HM, Onuma Y. A bioresorbable everolimus-eluting scaffold versus a metallic everolimus-eluting stent for ischaemic heart disease caused by de-novo native coronary artery lesions (ABSORB II): an interim 1-year analysis of clinical and procedural secondary outcomes from a randomised controlled trial. Lancet 2015;**385**(9962):43-54.

39. Ellis S. Everolimus-eluting Bioresorbable Vascular Scaffolds in Patients with Coronary Artery Disease: ABSORB III Trial 2-Year Results. In: *ACC*. *Washington, D.C., USA*, *2017*.

40. Gao R. Two results of the ABSORB China randomized trial. In: *Transcatheter Therapeutics (TCT)*. *Washington, D.C.*, *2016*.

41. Onuma Y, Sotomi Y, Shiomi H, Ozaki Y, Namiki A, Yasuda S, Ueno T, Ando K, Furuya J, Igarashi K, Kozuma K, Tanabe K, Kusano H, Rapoza R, Popma JJ, Stone GW, Simonton C, Serruys PW, Kimura T. Two-year clinical, angiographic, and serial optical coherence tomographic follow-up after implantation of an everolimus-eluting bioresorbable scaffold and an everolimus-eluting metallic stent: insights from the randomised ABSORB Japan trial. EuroIntervention 2016;**12**(9):1090-1101.

42. Puricel S. Comparison of Everolimus- and Biolimus-Eluting Coronary Stents With Everolimus-Eluting Bioresorbable Vascular Scaffolds: 2-year Outcomes of the EVERBIO II Trial. In: *Transcatheter Therapeutics (TCT)*. *San Francisco*, *2015*.

43. Windecker S. ABSORB STEMI-TROFI II - Two-year results. In: *Transcatheter Therapeutics (TCT)*. *Washington, D.C., USA*, *2016*.

44. Cassese S, Byrne RA, Ndrepepa G, Kufner S, Wiebe J, Repp J, Schunkert H, Fusaro M, Kimura T, Kastrati A. Everolimus-eluting bioresorbable vascular scaffolds versus everolimus-eluting metallic stents: a meta-analysis of randomised controlled trials. Lancet 2016;**387**(10018):537-44.

45. Stone GW, Gao R, Kimura T, Kereiakes DJ, Ellis SG, Onuma Y, Cheong WF, Jones-McMeans J, Su X, Zhang Z, Serruys PW. 1-year outcomes with the Absorb bioresorbable scaffold in patients with coronary artery disease: a patient-level, pooled meta-analysis. Lancet 2016;**387**(10025):1277-89.

46. Cassese S, Byrne RA, Jüni P, Wykrzykowska J, Puricel S, Ndrepepa G, Schunkert H, Fusaro M, Cook S, Kimura T, Henriques JP, Serruys PW, Windecker S, Kastrati A. Mid-term clinical outcomes with everolimus-eluting bioresorbable scaffolds versus everolimus-eluting metallic stents for percutaneous coronary interventions: a meta-analysis of randomized trials.

47. Abizaid A, Costa JR, Jr., Bartorelli AL, Whitbourn R, van Geuns RJ, Chevalier B, Patel T, Seth A, Stuteville M, Dorange C, Cheong WF, Sudhir K, Serruys PW. The ABSORB EXTEND study: preliminary report of the twelve-month clinical outcomes in the first 512 patients enrolled. EuroIntervention 2014.

48. Brugaletta S, Gori T, Low AF, Tousek P, Pinar E, Gomez-Lara J, Scalone G, Schulz E, Chan MY, Kocka V, Hurtado J, Gomez-Hospital JA, Munzel T, Lee CH, Cequier A, Valdes M, Widimsky P, Serruys PW, Sabate M. Absorb bioresorbable vascular scaffold versus everolimus-eluting metallic stent in ST-segment elevation myocardial infarction: 1-year results of a propensity score matching comparison: the BVS-EXAMINATION Study (bioresorbable vascular scaffold-a clinical evaluation of everolimus eluting coronary stents in the treatment of patients with ST-segment elevation myocardial infarction). JACC Cardiovasc Interv 2015;**8**(1 Pt B):189-97.

49. Capodanno D, Gori T, Nef H, Latib A, Mehilli J, Lesiak M, Caramanno G, Naber C, Di Mario C, Colombo A, Capranzano P, Wiebe J, Araszkiewicz A, Geraci S, Pyxaras S, Mattesini A, Naganuma T, Munzel T, Tamburino C. Percutaneous coronary intervention with everolimus-eluting bioresorbable vascular scaffolds in routine clinical practice: early and midterm outcomes from the European multicentre GHOST-EU registry. EuroIntervention 2015;**10**(11):1144-53.

50. Puricel S, Cuculi F, Weissner M, Schmermund A, Jamshidi P, Nyffenegger T, Binder H, Eggebrecht H, Munzel T, Cook S, Gori T. Bioresorbable Coronary Scaffold Thrombosis: Multicenter Comprehensive Analysis of Clinical Presentation, Mechanisms, and Predictors. J Am Coll Cardiol 2016;**67**(8):921-31.

51. Hoppmann P, Kufner S, Cassese S, Wiebe J, Schneider S, Pinieck S, Scheler L, Bernlochner I, Joner M, Schunkert H, Laugwitz KL, Kastrati A, Byrne RA. Angiographic and clinical outcomes of patients treated with everolimus-eluting bioresorbable stents in routine clinical practice: Results of the ISAR-ABSORB registry. Catheter Cardiovasc Interv 2016;**87**(5):822-9.

52. Ishibashi Y, Nakatani S, Sotomi Y, Suwannasom P, Grundeken MJ, Garcia-Garcia HM, Bartorelli AL, Whitbourn R, Chevalier B, Abizaid A, Ormiston JA, Rapoza RJ, Veldhof S, Onuma Y, Serruys PW. Relation Between Bioresorbable Scaffold Sizing Using QCA-Dmax and Clinical Outcomes at 1 Year in 1,232 Patients From 3 Study Cohorts (ABSORB Cohort B, ABSORB EXTEND, and ABSORB II). JACC Cardiovasc Interv 2015;**8**(13):1715-26.

53. Suwannasom P, Sotomi Y, Ishibashi Y, Cavalcante R, Albuquerque FN, Macaya C, Ormiston JA, Hill J, Lang IM, Egred M, Fajadet J, Lesiak M, Tijssen JG, Wykrzykowska JJ, de Winter RJ, Chevalier B, Serruys PW, Onuma Y. The Impact of Post-Procedural Asymmetry, Expansion, and Eccentricity of Bioresorbable Everolimus-Eluting Scaffold and Metallic Everolimus-Eluting Stent on Clinical Outcomes in the ABSORB II Trial. JACC Cardiovasc Interv 2016;**9**(12):1231-42.

54. Sotomi Y, Onuma Y, Dijkstra J, Eggermont J, Liu S, Tenekecioglu E, Zeng Y, Asano T, de Winter RJ, Popma JJ, Kozuma K, Tanabe K, Serruys PW, Kimura T. Impact of Implantation Technique and Plaque Morphology on Strut Embedment and Scaffold Expansion of Polylactide Bioresorbable Scaffold- Insights From ABSORB Japan Trial. Circ J 2016;**80**(11):2317-2326.

55. Ortega-Paz L, Capodanno D, Gori T, Nef H, Latib A, Caramanno G, Di Mario C, Naber C, Lesiak M, Capranzano P, Wiebe J, Mehilli J, Araszkiewicz A, Pyxaras S, Mattesini A, Geraci S, Naganuma T, Colombo A, Munzel T, Sabate M, Tamburino C, Brugaletta S. Predilation, sizing and post-dilation scoring in patients undergoing everolimus-eluting bioresorbable scaffold implantation for prediction of cardiac adverse events: development and internal validation of the PSP score. EuroIntervention 2017.

56. Collet C. Late Thrombotic Events after Bioresorbable Scaffold Implantation: A Systematic Review and Meta-analysis of Randomized Clinical Trials. Eur Heart J.

57. Raber L, Brugaletta S, Yamaji K, O'Sullivan CJ, Otsuki S, Koppara T, Taniwaki M, Onuma Y, Freixa X, Eberli FR, Serruys PW, Joner M, Sabate M, Windecker S. Very Late Scaffold Thrombosis: Intracoronary Imaging and Histopathological and Spectroscopic Findings. J Am Coll Cardiol 2015;**66**(17):1901-14.

58. Sotomi Y, Suwannasom P, Serruys PW, Onuma Y. Possible Mechanical Causes of Scaffold Thrombosis: Insights from Case Reports with Intracoronary Imaging. EuroIntervention 2016.

59. Onuma Y, Serruys PW, Muramatsu T, Nakatani S, van Geuns RJ, de Bruyne B, Dudek D, Christiansen E, Smits PC, Chevalier B, McClean D, Koolen J, Windecker S, Whitbourn R, Meredith I, Garcia-Garcia HM, Veldhof S, Rapoza R, Ormiston JA. Incidence and imaging outcomes of acute scaffold disruption and late structural discontinuity after implantation of the absorb Everolimus-Eluting fully bioresorbable vascular scaffold: optical coherence tomography assessment in the ABSORB cohort B Trial (A Clinical Evaluation of the Bioabsorbable Everolimus Eluting Coronary Stent System in the Treatment of Patients With De Novo Native Coronary Artery Lesions). JACC Cardiovasc Interv 2014;**7**(12):1400-11.

60. Abizaid A, Costa RA, Schofer J, Ormiston J, Maeng M, Witzenbichler B, Botelho RV, Costa JR, Jr., Chamie D, Abizaid AS, Castro JP, Morrison L, Toyloy S, Bhat V, Yan J, Verheye S. Serial Multimodality Imaging and 2-Year Clinical Outcomes of the Novel DESolve Novolimus-Eluting Bioresorbable Coronary Scaffold System for the Treatment of Single De Novo Coronary Lesions. JACC Cardiovasc Interv 2016;**9**(6):565-74.

61. Wiebe J. Everolimus- versus novolimus-eluting bioresorbable scaffolds for the treatment of coronary artery disease: a matched comparison. .

62. Haude M, Ince H, Abizaid A, Toelg R, Lemos PA, von Birgelen C, Christiansen EH, Wijns W, Neumann FJ, Kaiser C, Eeckhout E, Lim ST, Escaned J, Onuma Y, Garcia-Garcia HM, Waksman R. Sustained safety and performance of the second-generation drug-eluting absorbable metal scaffold in patients with de novo coronary lesions: 12-month clinical results and angiographic findings of the BIOSOLVE-II first-in-man trial. Eur Heart J 2016.

63. Haude M, Ince H, Abizaid A, Toelg R, Lemos PA, von Birgelen C, Christiansen EH, Wijns W, Neumann FJ, Kaiser C, Eeckhout E, Lim ST, Escaned J, Garcia-Garcia HM, Waksman R. Safety and performance of the second-generation drug-eluting absorbable metal scaffold in patients with de-novo coronary artery lesions (BIOSOLVE-II): 6 month results of a prospective, multicentre, non-randomised, first-in-man trial. Lancet 2016;**387**(10013):31-9.

64. Yamaji K, Raber L, Windecker S. What determines long-term outcomes using fully bioresorbable scaffolds - the device, the operator or the lesion? EuroIntervention 2017.

65. Diletti R, Farooq V, Girasis C, Bourantas C, Onuma Y, Heo JH, Gogas BD, van Geuns RJ, Regar E, de Bruyne B, Dudek D, Thuesen L, Chevalier B, McClean D, Windecker S, Whitbourn RJ, Smits P, Koolen J, Meredith I, Li X, Miquel-Hebert K, Veldhof S, Garcia-Garcia HM, Ormiston JA, Serruys PW. Clinical and intravascular imaging outcomes at 1 and 2 years after implantation of absorb everolimus eluting bioresorbable vascular scaffolds in small vessels. Late lumen enlargement: does

bioresorption matter with small vessel size? Insight from the ABSORB cohort B trial. Heart 2013;**99**(2):98-105.

66. Tanaka A, Ruparelia N, Kawamoto H, Sticchi A, Sato K, Miyazaki T, Naganuma T, Chieffo A, Carlino M, Montorfano M, Latib A, Colombo A. Clinical outcomes following bioresorbable scaffold implantation in small vessels. Int J Cardiol 2016;**207**:59-61.

67. Latini RA, Granata F, Ielasi A, Varricchio A, Moscarella E, Tespili M, Cortese B. Bioresorbable vascular scaffolds for small vessels coronary disease: The BVS-save registry. Catheter Cardiovasc Interv 2016.

68. Steinvil A, Rogers T, Torguson R, Waksman R. Overview of the 2016 U.S. Food and Drug Administration Circulatory System Devices Advisory Panel Meeting on the Absorb Bioresorbable Vascular Scaffold System. JACC Cardiovasc Interv 2016;**9**(17):1757-64.

69. Wiebe J, Hoppmann P, Kufner S, Harada Y, Colleran R, Michel J, Giacoppo D, Schneider S, Cassese S, Ibrahim T, Schunkert H, Laugwitz KL, Kastrati A, Byrne RA. Impact of stent size on angiographic and clinical outcomes after implantation of everolimus-eluting bioresorbable scaffolds in daily practice: insights from the ISAR-ABSORB registry. EuroIntervention 2016;**12**(2):e137-43.

70. Gori T, Schulz E, Hink U, Wenzel P, Post F, Jabs A, Munzel T. Early outcome after implantation of Absorb bioresorbable drug-eluting scaffolds in patients with acute coronary syndromes. EuroIntervention 2014;**9**(9):1036-41.

71. Dudek D, Rzeszutko L, Zasada W, Depukat R, Siudak Z, Ochala A, Wojakowski W, Przewlocki T, Zmudka K, Kochman J, Lekston A, Gasior M. Bioresorbable vascular scaffolds in patients with acute coronary syndromes: the POLAR ACS study. Pol Arch Med Wewn 2014;**124**(12):669-77.

72. Gori T, Schulz E, Hink U, Kress M, Weiers N, Weissner M, Jabs A, Wenzel P, Capodanno D, Munzel T. Clinical, Angiographic, Functional, and Imaging Outcomes 12 Months After Implantation of Drug-Eluting Bioresorbable Vascular Scaffolds in Acute Coronary Syndromes. JACC Cardiovasc Interv 2015;**8**(6):770-7.

73. Felix CM, Onuma Y, Fam JM, Diletti R, Ishibashi Y, Karanasos A, Everaert BR, van Mieghem NM, Daemen J, de Jaegere PP, Zijlstra F, Regar ES, van Geuns RJ. Are BVS suitable for ACS patients? Support from a large single center real live registry. Int J Cardiol 2016;**218**:89-97.

74. Rzeszutko L, Siudak Z, Tokarek T, Plens K, Wlodarczak A, Lekston A, Ochala A, Gil RJ, Balak W, Dudek D. Twelve months clinical outcome after bioresorbable vascular scaffold implantation in patients with stable angina and acute coronary syndrome. Data from the Polish National Registry. Postepy Kardiol Interwencyjnej 2016;**12**(2):108-15.

75. Schnorbus B, Wiebe J, Capodanno D, Brugaletta S, Geraci S, Mehilli J, Latib A, Lesiak M, Jensen C, Mattesini A, Munzel T, Capranzano P, Di Mario C, Naber C, Araszkiewicz A, Colombo A, Caramanno G, Sabate M, Tamburino C, Nef H, Gori T. 12 months outcomes after Bioresorbable Vascular Scaffold implantation in Patients with Acute Coronary Syndromes. Data from the European Multicentre GHOST-EU Extended Registry. EuroIntervention 2017.

76. Lipinski MJ, Escarcega RO, Baker NC, Benn HA, Gaglia MA, Jr., Torguson R, Waksman R. Scaffold Thrombosis After Percutaneous Coronary Intervention With ABSORB Bioresorbable Vascular Scaffold: A Systematic Review and Meta-Analysis. JACC Cardiovasc Interv 2016;**9**(1):12-24.

77. Kajiya T, Liang M, Sharma RK, Lee CH, Chan MY, Tay E, Chan KH, Tan HC, Low AF. Everolimus-eluting bioresorbable vascular scaffold (BVS) implantation in patients with ST-segment elevation myocardial infarction (STEMI). EuroIntervention 2013;**9**(4):501-4.

78. Diletti R, Karanasos A, Muramatsu T, Nakatani S, Van Mieghem NM, Onuma Y, Nauta ST, Ishibashi Y, Lenzen MJ, Ligthart J, Schultz C, Regar E, de Jaegere PP, Serruys PW, Zijlstra F, van Geuns RJ.

Everolimus-eluting bioresorbable vascular scaffolds for treatment of patients presenting with ST-segment elevation myocardial infarction: BVS STEMI first study. Eur Heart J 2014;**35**(12):777-86.

79. Wiebe J, Mollmann H, Most A, Dorr O, Weipert K, Rixe J, Liebetrau C, Elsasser A, Achenbach S, Hamm C, Nef H. Short-term outcome of patients with ST-segment elevation myocardial infarction (STEMI) treated with an everolimus-eluting bioresorbable vascular scaffold. Clin Res Cardiol 2014;**103**(2):141-8.

80. Kocka V, Maly M, Tousek P, Budesinsky T, Lisa L, Prodanov P, Jarkovsky J, Widimsky P. Bioresorbable vascular scaffolds in acute ST-segment elevation myocardial infarction: a prospective multicentre study 'Prague 19'. Eur Heart J 2014;**35**(12):787-94.

81. Ielasi A, Cortese B, Varricchio A, Tespili M, Sesana M, Pisano F, Loi B, Granata F, Moscarella E, Silva Orrego P, La Vecchia L, Steffenino G. Immediate and midterm outcomes following primary PCI with bioresorbable vascular scaffold implantation in patients with ST-segment myocardial infarction: insights from the multicentre "Registro ABSORB Italiano" (RAI registry). EuroIntervention 2015;**11**(2):157-62.

82. Cortese B, Ielasi A, Romagnoli E, Varricchio A, Cuculo A, Loi B, Pisano F, Corrado D, Sesana M, La Vecchia L, Summaria F, Tespili M, Silva Orrego P, Tognoni G, Steffenino G. Clinical Comparison With Short-Term Follow-Up of Bioresorbable Vascular Scaffold Versus Everolimus-Eluting Stent in Primary Percutaneous Coronary Interventions. Am J Cardiol 2015;**116**(5):705-10.

83. Kochman J, Tomaniak M, Koltowski L, Jakala J, Proniewska K, Legutko J, Roleder T, Pietrasik A, Rdzanek A, Kochman W, Brugaletta S, Kaluza GL. A 12-month angiographic and optical coherence tomography follow-up after bioresorbable vascular scaffold implantation in patients with ST-segment elevation myocardial infarction. Catheter Cardiovasc Interv 2015;**86**(4):E180-9.

84. Kochman J, Tomaniak M, Pietrasik A, Koltowski L, Rdzanek A, Huczek Z, Mazurek T, Jakala J, Zabek A, Legutko J, Kochman W, Filipiak KJ. Bioresorbable everolimus-eluting vascular scaffold in patients with ST-segment elevation myocardial infarction: Optical coherence tomography evaluation and clinical outcomes. Cardiol J 2015;**22**(3):315-22.

85. Widimsky P, Petr R, Tousek P, Maly M, Linkova H, Vrana J, Hajsl M, Budesinsky T, Lisa L, Kocka V. One-Year Clinical and Computed Tomography Angiographic Outcomes After Bioresorbable Vascular Scaffold Implantation During Primary Percutaneous Coronary Intervention for ST-Segment-Elevation Myocardial Infarction: The PRAGUE-19 Study. Circ Cardiovasc Interv 2015;**8**(12):e002933.

86. Chakraborty R, Patra S, Banerjee S, Pande A, Khan A, Mandol PC, Ghosh D, De SK, Das SS, Nag R. Outcome of everolimus eluting bioabsorbable vascular scaffold (BVS) compared to non BVS drug eluting stent in the management of ST-segment elevation myocardial infarction (STEMI) - A comparative study. Cardiovasc Revasc Med 2016;**17**(3):151-4.

87. Fam JM, Felix C, van Geuns RJ, Onuma Y, Van Mieghem NM, Karanasos A, van der Sijde J, De Paolis M, Regar E, Valgimigli M, Daemen J, de Jaegere P, Zijlstra F, Diletti R. Initial experience with everolimus-eluting bioresorbable vascular scaffolds for treatment of patients presenting with acute myocardial infarction: a propensity-matched comparison to metallic drug eluting stents 18-month follow-up of the BVS STEMI first study. EuroIntervention 2016;**12**(1):30-7.

88. Tousek P, Kocka V, Maly M, Kozel M, Petr R, Hajsl M, Jarkovsky J, Lisa L, Budesinsky T, Widimsky P. Long-term follow-up after bioresorbable vascular scaffold implantation in STEMI patients: PRAGUE-19 study update. EuroIntervention 2016;**12**(1):23-9.

89. Brugaletta S, Gori T, Low AF, Tousek P, Pinar E, Gomez-Lara J, Ortega-Paz L, Schulz E, Chan MY, Kocka V, Hurtado J, Gomez-Hospital JA, Giacchi G, Munzel T, Lee CH, Cequier A, Valdes M, Widimsky P, Serruys PW, Sabate M. ABSORB bioresorbable vascular scaffold vs. everolimus-eluting metallic stent in ST-segment elevation myocardial infarction (BVS EXAMINATION study): 2-Year results from a propensity score matched comparison. Int J Cardiol 2016;**214**:483-4.

90. Tousek P, Kocka V, Maly M, Kozel M, Robert P, Hajsl M, Jarkovsky J, Widimsky P. Two-year follow-up after bioresorbable vascular scaffold implantation in STEMI patients - Results from PRAGUE-19 study. Int J Cardiol 2016;**209**:20-1.

91. Sotomi Y, Miyazaki Y, Colet C, Asano T, Suwannasom P, Tijssen J, de Winter RJ, Waksman R, Lipinski MJ, Onuma Y, Serruys PW. Does acute coronary syndrome impact on the incidence of thrombosis after the implantation of Absorb bioresorbable vascular scaffold? EuroIntervention 2016.

92. Cockburn J, Shaw E, Bhindi R, Hansen P. Treatment of a left anterior descending artery chronic total occlusion using a bio-absorbable scaffold, utilising optical coherence tomography. Int J Cardiol 2013;**167**(5):e123-6.

93. La Manna A, Ohno Y, Attizzani GF, Tamburino C. Successful retrograde recanalization of chronic total coronary occlusion with multiple bioresorbable vascular scaffolds ('full polymer jacket'): initial experience and rationale. Eur Heart J 2013;**34**(37):2925.

94. Gori T, Guagliumi G, Munzel T. Absorb bioresorbable scaffold implantation for the treatment of an ostial chronic total occlusion. Int J Cardiol 2014;**172**(2):e377-8.

95. Rama-Merchan JC, Mattesini A, Dall'Ara G, Mario CD. Chronic total occlusion successfully treated with a bioresorbable everolimus-eluting vascular scaffold. Postepy Kardiol Interwencyjnej 2014;**10**(2):128-9.

96. Naganuma T, Latib A, Panoulas VF, Sato K, Miyazaki T, Nakamura S, Colombo A. One-year follow-up optical coherence tomography after implantation of bioresorbable vascular scaffolds for a chronic coronary total occlusion. JACC Cardiovasc Interv 2014;**7**(10):e157-9.

97. Medda M, Casilli F, Bande M, Latini MG, Ghommidh M, Del Furia F, Inglese L. Bioresorbable vascular scaffold (BVS) for in-stent chronic total occlusion: Antegrade recanalization and IVUS-guided BVS implantation by radial access. Cardiovasc Revasc Med 2016;**17**(1):63-5.

98. Wiebe J, Liebetrau C, Dorr O, Most A, Weipert K, Rixe J, Bauer T, Mollmann H, Elsasser A, Hamm CW, Nef HM. Feasibility of everolimus-eluting bioresorbable vascular scaffolds in patients with chronic total occlusion. Int J Cardiol 2015;**179**:90-4.

99. Vaquerizo B, Barros A, Pujadas S, Bajo E, Estrada D, Miranda-Guardiola F, Rigla J, Jimenez M, Cinca J, Serra A. Bioresorbable everolimus-eluting vascular scaffold for the treatment of chronic total occlusions: CTO-ABSORB pilot study. EuroIntervention 2015;**11**(5):555-63.

100. Ojeda S, Pan M, Romero M, Suarez de Lezo J, Mazuelos F, Segura J, Espejo S, Morenate C, Blanco M, Martin P, Medina A, Suarez de Lezo J. Outcomes and computed tomography scan follow-up of bioresorbable vascular scaffold for the percutaneous treatment of chronic total coronary artery occlusion. Am J Cardiol 2015;**115**(11):1487-93.

101. Goktekin O, Yamac AH, Latib A, Tastan A, Panoulas VF, Sato K, Erdogan E, Uyarel H, Shah I, Colombo A. Evaluation of the Safety of Everolimus-Eluting Bioresorbable Vascular Scaffold (BVS) Implantation in Patients With Chronic Total Coronary Occlusions: Acute Procedural and Short-Term Clinical Results. J Invasive Cardiol 2015;**27**(10):461-6.

102. La Manna A, Chisari A, Giacchi G, Capodanno D, Longo G, Di Silvestro M, Capranzano P, Tamburino C. Everolimus-eluting bioresorbable vascular scaffolds versus second generation drug-eluting stents for percutaneous treatment of chronic total coronary occlusions: Technical and procedural outcomes from the GHOST-CTO registry. Catheter Cardiovasc Interv 2016.

103. Vaquerizo B, Barros A, Pujadas S, Bajo E, Jimenez M, Gomez-Lara J, Jacobi F, Salvatella N, Pons G, Cinca J, Serra A. One-Year Results of Bioresorbable Vascular Scaffolds for Coronary Chronic Total Occlusions. Am J Cardiol 2016;**117**(6):906-17.

104. Ozel E, Tastan A, Ozturk A, Ozcan EE, Kilicaslan B, Ozdogan O. Procedural and one-year clinical outcomes of bioresorbable vascular scaffolds for the treatment of chronic total occlusions: a single-centre experience. Cardiovasc J Afr 2016;**27**:1-5.

105. Lesiak M, Lanocha M, Araszkiewicz A, Siniawski A, Grygier M, Pyda M, Olasinska-Wisniewska A, Iwanczyk S, Skorupski W, Mitkowski P, Lesiak MB, Grajek S. Percutaneous coronary intervention for chronic total occlusion of the coronary artery with the implantation of bioresorbable everolimus-eluting scaffolds. Poznan CTO-Absorb Pilot Registry. EuroIntervention 2016;**12**(2):e144-51.

106. Fam JM, Ojeda S, Garbo R, Latib A, La Manna A, Vaquerizo B, Boukhris M, Vlachojannis GJ, van Geuns RJ, Ezhumalai B, Kawamoto H, van der Sijde J, Felix C, Pan M, Serdoz R, Boccuzzi GG, De Paolis M, Sardella G, Tamburino C, Smits PC, Di Mario C, Seth A, Serra A, Colombo A, Serruys P, Galassi AR, Zijlstra F, van Mieghem NM, Diletti R. Everolimus Eluting Bioresorbable Vascular Scaffold for Treatment of Complex Chronic Total Occlusions. EuroIntervention 2017.

107. Mitomo S, Naganuma T, Fujino Y, Kawamoto H, Basavarajaiah S, Pitt M, Yin WH, Tresukosol D, Colombo A, Nakamura S. Bioresorbable Vascular Scaffolds for the Treatment of Chronic Total Occlusions: An International Multicenter Registry. Circ Cardiovasc Interv 2017;**10**(1).

108. Farooq V, Serruys PW, Heo JH, Gogas BD, Onuma Y, Perkins LE, Diletti R, Radu MD, Raber L, Bourantas CV, Zhang Y, van Remortel E, Pawar R, Rapoza RJ, Powers JC, van Beusekom HM, Garcia-Garcia HM, Virmani R. Intracoronary optical coherence tomography and histology of overlapping everolimus-eluting bioresorbable vascular scaffolds in a porcine coronary artery model: the potential implications for clinical practice. JACC Cardiovasc Interv 2013;**6**(5):523-32.

109. Farooq V, Onuma Y, Radu M, Okamura T, Gomez-Lara J, Brugaletta S, Gogas BD, van Geuns RJ, Regar E, Schultz C, Windecker S, Lefevre T, Brueren BR, Powers J, Perkins LL, Rapoza RJ, Virmani R, Garcia-Garcia HM, Serruys PW. Optical coherence tomography (OCT) of overlapping bioresorbable scaffolds: from benchwork to clinical application. EuroIntervention 2011;**7**(3):386-99.

110. Biscaglia S, Campo G, Tebaldi M, Tumscitz C, Pavasini R, Fileti L, Secco GG, Di Mario C, Ferrari R. Bioresorbable vascular scaffold overlap evaluation with optical coherence tomography after implantation with or without enhanced stent visualization system (WOLFIE study): a two-centre prospective comparison. Int J Cardiovasc Imaging 2016;**32**(2):211-23.

111. Ielasi A, Miyazaki T, Geraci S, Testa L, Abdel-Wahab M, Kawamoto H, Ruparelia N, Sato T, Caramanno G, Bedogni F, Tespili M, Colombo A, Latib A. Hybrid strategy with a bioresorbable scaffold and a drug-coated balloon for diffuse coronary artery disease: the "no more metallic cages" multicentre pilot experience. EuroIntervention 2016;**11**(14):e1589-95.

112. Biscaglia S, Ugo F, Ielasi A, Secco GG, Durante A, D'Ascenzo F, Cerrato E, Balghith M, Pasquetto G, Penzo C, Fineschi M, Bonechi F, Templin C, Menozzi M, Aquilina M, Rognoni A, Capasso P, Di Mario C, Brugaletta S, Campo G. Bioresorbable Scaffold vs. Second Generation Drug Eluting Stent in Long Coronary Lesions requiring Overlap: A Propensity-Matched Comparison (the UNDERDOGS study). Int J Cardiol 2016;**208**:40-5.

113. Panoulas VF, Kawamoto H, Sato K, Miyazaki T, Naganuma T, Sticchi A, Latib A, Colombo A. Clinical Outcomes After Implantation of Overlapping Bioresorbable Scaffolds vs New Generation Everolimus Eluting Stents. Rev Esp Cardiol (Engl Ed) 2016.

114. Ortega-Paz L, Capodanno D, Giacchi G, Gori T, Nef H, Latib A, Caramanno G, Di Mario C, Naber C, Lesiak M, Capranzano P, Wiebe J, Mehilli J, Araszkiewicz A, Pyxaras S, Mattesini A, Geraci S, Naganuma T, Colombo A, Munzel T, Sabate M, Tamburino C, Brugaletta S. Impact of overlapping on 1-year clinical outcomes in patients undergoing everolimus-eluting bioresorbable scaffolds implantation in routine clinical practice: Insights from the European multicenter GHOST-EU registry. Catheter Cardiovasc Interv 2016.

115. Attizzani GF, Ohno Y, Capranzano P, La Manna A, Francaviglia B, Grasso C, Sgroi C, Tamburino C, Longo G, Fujino Y, Capodanno D, Tamburino C. Initial experience of percutaneous coronary intervention in bifurcations with bioresorbable vascular scaffolds using different techniques--insights from optical coherence tomography. Int J Cardiol 2013;**170**(2):e33-5.

116. Dzavik V, Colombo A. The absorb bioresorbable vascular scaffold in coronary bifurcations: insights from bench testing. JACC Cardiovasc Interv 2014;**7**(1):81-8.

117. Costopoulos C, Naganuma T, Latib A, Colombo A. Optical coherence tomography of a bifurcation lesion treated with bioresorbable vascular scaffolds with the "mini-crush" technique. JACC Cardiovasc Interv 2013;**6**(12):1326-7.

118. Sgueglia GA, D'Errico F, Gioffre G, De Santis A, Gaspardone A. First ad hoc bioresorbable vascular scaffold bench test: a glimpse into percutaneous bifurcation interventions. Int J Cardiol 2014;**172**(3):604-6.

119. Seth A, Sengottuvelu G, Ravisekar V. Salvage of side branch by provisional "TAP technique" using Absorb bioresorbable vascular scaffolds for bifurcation lesions: first case reports with technical considerations. Catheter Cardiovasc Interv 2014;**84**(1):55-61.

120. Ormiston JA, Webber B, Ubod B, Webster MW, White J. Absorb everolimus-eluting bioresorbable scaffolds in coronary bifurcations: a bench study of deployment, side branch dilatation and post-dilatation strategies. EuroIntervention 2015;**10**(10):1169-77.

121. Kawamoto H, Panoulas VF, Sato K, Miyazaki T, Latib A, Colombo A. Two-Year Follow-Up OCT Images of 2 Bifurcation Lesions Treated With Bioresorbable Vascular Scaffolds. JACC Cardiovasc Imaging 2015;**8**(5):617-8.

122. Tamburino C, Latib A, van Geuns RJ, Sabate M, Mehilli J, Gori T, Achenbach S, Alvarez MP, Nef H, Lesiak M, Di Mario C, Colombo A, Naber CK, Caramanno G, Capranzano P, Brugaletta S, Geraci S, Araszkiewicz A, Mattesini A, Pyxaras SA, Rzeszutko L, Depukat R, Diletti R, Boone E, Capodanno D, Dudek D. Contemporary practice and technical aspects in coronary intervention with bioresorbable scaffolds: a European perspective. EuroIntervention 2015;**11**(1):45-52.

123. Diletti R, Tchetche D, Barbato E, Latib A, Farah B, van Geuns RJ, Colombo A, Fajadet J, van Mieghem NM. Bioresorbable scaffolds for treatment of coronary bifurcation lesions: Critical appraisal and future perspectives. Catheter Cardiovasc Interv 2016.

124. Kawamoto H, Ruparelia N, Tanaka A, Chieffo A, Latib A, Colombo A. Bioresorbable Scaffolds for the Management of Coronary Bifurcation Lesions. JACC Cardiovasc Interv 2016;**9**(10):989-1000.

125. Derimay F, Souteyrand G, Motreff P, Guerin P, Pilet P, Ohayon J, Darremont O, Rioufol G, Finet G. Sequential Proximal Optimizing Technique in Provisional Bifurcation Stenting With Everolimus-Eluting Bioresorbable Vascular Scaffold: Fractal Coronary Bifurcation Bench for Comparative Test Between Absorb and XIENCE Xpedition. JACC Cardiovasc Interv 2016;**9**(13):1397-406.

126. Lassen JF, Holm NR, Banning A, Burzotta F, Lefevre T, Chieffo A, Hildick-Smith D, Louvard Y, Stankovic G. Percutaneous coronary intervention for coronary bifurcation disease: 11th consensus document from the European Bifurcation Club. EuroIntervention 2016;**12**(1):38-46.

127. Kawamoto H, Latib A, Ruparelia N, Miyazaki T, Sticchi A, Naganuma T, Sato K, Figini F, Chieffo A, Carlino M, Montorfano M, Colombo A. Clinical outcomes following bioresorbable scaffold implantation for bifurcation lesions: Overall outcomes and comparison between provisional and planned double stenting strategy. Catheter Cardiovasc Interv 2015;**86**(4):644-52.

128. Tanaka A, Latib A, Kawamoto H, Jabbour RJ, Mangieri A, Pagnesi M, Montalto C, Regazzoli D, Ancona M, Chieffo A, Carlino M, Montorfano M, Colombo A. Clinical outcomes following bifurcation double-stenting with bioresorbable scaffolds. Catheter Cardiovasc Interv 2016.

129. Suarez de Lezo J, Martin P, Pan M, Ojeda S, Novoa J, Segura J, Mazuelos F, Romero M, Medina A, Suarez de Lezo J. Bioresorbable Vascular Scaffold for the Treatment of Coronary Bifurcation Lesions: Immediate Results and 1-year Follow-up. Rev Esp Cardiol (Engl Ed) 2016;**69**(6):554-62.

130. Wiebe J, Dorr O, Bauer T, Liebetrau C, Boeder N, Mollmann H, Hamm CW, Nef HM. Everolimus-eluting bioresorbable scaffold implantation for the treatment of bifurcation lesions - Implications from early clinical experience during daily practice. Cardiovasc Revasc Med 2016.

131. Naganuma T, Colombo A, Lesiak M, Capodanno D, Gori T, Nef H, Caramanno G, Naber C, Di Mario C, Ruparelia N, Capranzano P, Wiebe J, Araszkiewicz A, Geraci S, Kawamoto H, Pyxaras S, Mattesini A, Munzel T, Tamburino C, Latib A. Bioresorbable vascular scaffold use for coronary bifurcation lesions: A substudy from GHOST EU registry. Catheter Cardiovasc Interv 2016.

132. Capodanno D, Gori T, Nef H, Latib A, Mehilli J, Lesiak M, Caramanno G, Naber C, Di Mario C, Colombo A, Capranzano P, Wiebe J, Araszkiewicz A, Geraci S, Pyxaras S, Mattesini A, Naganuma T, Munzel T, Tamburino C. Percutaneous coronary intervention with everolimus-eluting bioresorbable vascular scaffolds in routine clinical practice: early and midterm outcomes from the European multicentre GHOST-EU registry. EuroIntervention 2015;**10**(10):1144-53.

133. Muramatsu T, Onuma Y, van Geuns RJ, Chevalier B, Patel TM, Seth A, Diletti R, Garcia-Garcia HM, Dorange CC, Veldhof S, Cheong WF, Ozaki Y, Whitbourn R, Bartorelli A, Stone GW, Abizaid A, Serruys PW. 1-year clinical outcomes of diabetic patients treated with everolimus-eluting bioresorbable vascular scaffolds: a pooled analysis of the ABSORB and the SPIRIT trials. JACC Cardiovasc Interv 2014;**7**(5):482-93.

134. Brugaletta S, Heo JH, Garcia-Garcia HM, Farooq V, van Geuns RJ, de Bruyne B, Dudek D, Smits PC, Koolen J, McClean D, Dorange C, Veldhof S, Rapoza R, Onuma Y, Bruining N, Ormiston JA, Serruys PW. Endothelial-dependent vasomotion in a coronary segment treated by ABSORB everolimus-eluting bioresorbable vascular scaffold system is related to plaque composition at the time of bioresorption of the polymer: indirect finding of vascular reparative therapy? Eur Heart J 2012;**33**(11):1325-33.

135. Sarno G, Bruining N, Onuma Y, Garg S, Brugaletta S, De Winter S, Regar E, Thuesen L, Dudek D, Veldhof S, Dorange C, Garcia-Garcia HM, Ormiston JA, Serruys PW. Morphological and functional evaluation of the bioresorption of the bioresorbable everolimus-eluting vascular scaffold using IVUS, echogenicity and vasomotion testing at two year follow-up: a patient level insight into the ABSORB A clinical trial. Int J Cardiovasc Imaging 2012;**28**(1):51-8.

136. Bourantas CV, Serruys PW, Nakatani S, Zhang YJ, Farooq V, Diletti R, Ligthart J, Sheehy A, van Geuns RJ, McClean D, Chevalier B, Windecker S, Koolen J, Ormiston J, Whitbourn R, Rapoza R, Veldhof S, Onuma Y, Garcia-Garcia HM. Bioresorbable vascular scaffold treatment induces the formation of neointimal cap that seals the underlying plaque without compromising the luminal dimensions: a concept based on serial optical coherence tomography data. EuroIntervention 2015;**11**(7):746-56.

137. Nakatani S, Ishibashi Y, Sotomi Y, Perkins L, Eggermont J, Grundeken MJ, Dijkstra J, Rapoza R, Virmani R, Serruys PW, Onuma Y. Bioresorption and Vessel Wall Integration of a Fully Bioresorbable Polymeric Everolimus-Eluting Scaffold: Optical Coherence Tomography, Intravascular Ultrasound, and Histological Study in a Porcine Model With 4-Year Follow-Up. JACC Cardiovasc Interv 2016;**9**(8):838-51.

138. Campos CM, Ishibashi Y, Eggermont J, Nakatani S, Cho YK, Dijkstra J, Reiber JH, Sheehy A, Lane J, Kamberi M, Rapoza R, Perkins L, Garcia-Garcia HM, Onuma Y, Serruys PW. Echogenicity as a surrogate for bioresorbable everolimus-eluting scaffold degradation: analysis at 1-, 3-, 6-, 12- 18, 24-, 30-, 36- and 42-month follow-up in a porcine model. Int J Cardiovasc Imaging 2015;**31**(3):471-82.

139. Nakatani S, Onuma Y, Ishibashi Y, Eggermont J, Zhang YJ, Campos CM, Cho YK, Liu S, Dijkstra J, Reiber JH, Perkins L, Sheehy A, Veldhof S, Rapoza R, van Es GA, Garcia-Garcia HM, van Geuns RJ, Serruys PW. Temporal evolution of strut light intensity after implantation of bioresorbable polymeric intracoronary scaffolds in the ABSORB cohort B trial-an application of a new quantitative method based on optical coherence tomography. Circ J 2014;**78**(8):1873-81.

140. Brugaletta S, Gomez-Lara J, Bruining N, Radu MD, van Geuns RJ, Thuesen L, McClean D, Koolen J, Windecker S, Whitbourn R, Oberhauser J, Rapoza R, Ormiston JA, Garcia-Garcia HM, Serruys PW. Head to head comparison of optical coherence tomography, intravascular ultrasound echogenicity and virtual histology for the detection of changes in polymeric struts over time: insights from the ABSORB trial. EuroIntervention 2012;**8**(3):352-8.

141. Shin ES, Garcia-Garcia HM, Garg S, Ligthart J, Thuesen L, Dudek D, Ormiston JA, Serruys PW. Assessment of the serial changes of vessel wall contents in atherosclerotic coronary lesion with bioresorbable everolimus-eluting vascular scaffolds using Shin's method: an IVUS study. Int J Cardiovasc Imaging 2011;**27**(7):931-7.

142. Gomez-Lara J, Brugaletta S, Diletti R, Gogas BD, Farooq V, Onuma Y, Gobbens P, Van Es GA, Garcia-Garcia HM, Serruys PW. Agreement and reproducibility of gray-scale intravascular ultrasound and optical coherence tomography for the analysis of the bioresorbable vascular scaffold. Catheter Cardiovasc Interv 2012;**79**(6):890-902.

143. Gogas BD, Radu M, Onuma Y, Perkins L, Powers JC, Gomez-Lara J, Farooq V, Garcia-Garcia HM, Diletti R, Rapoza R, Virmani R, Serruys PW. Evaluation with in vivo optical coherence tomography and histology of the vascular effects of the everolimus-eluting bioresorbable vascular scaffold at two years following implantation in a healthy porcine coronary artery model: implications of pilot results for future pre-clinical studies. Int J Cardiovasc Imaging 2012;**28**(3):499-511.

144. Nakatani S, Sotomi Y, Ishibashi Y, Grundeken MJ, Tateishi H, Tenekecioglu E, Zeng Y, Suwannasom P, Regar E, Radu MD, Raber L, Bezerra H, Costa MA, Fitzgerald P, Prati F, Costa RA, Dijkstra J, Kimura T, Kozuma K, Tanabe K, Akasaka T, Di Mario C, Serruys PW, Onuma Y. Comparative analysis method of permanent metallic stents (XIENCE) and bioresorbable poly-L-lactic (PLLA) scaffolds (Absorb) on optical coherence tomography at baseline and follow-up. EuroIntervention 2015;**11**(6).

145. Simsek C, Karanasos A, Magro M, Garcia-Garcia HM, Onuma Y, Regar E, Boersma E, Serruys PW, van Geuns RJ. Long-term invasive follow-up of the everolimus-eluting bioresorbable vascular scaffold: five-year results of multiple invasive imaging modalities. EuroIntervention 2016;**11**(9):996-1003.

146. Karanasos A, Simsek C, Gnanadesigan M, van Ditzhuijzen NS, Freire R, Dijkstra J, Tu S, Van Mieghem N, van Soest G, de Jaegere P, Serruys PW, Zijlstra F, van Geuns RJ, Regar E. OCT assessment of the long-term vascular healing response 5 years after everolimus-eluting bioresorbable vascular scaffold. J Am Coll Cardiol 2014;**64**(22):2343-56.

147. Serruys PW, Ormiston J, van Geuns RJ, de Bruyne B, Dudek D, Christiansen E, Chevalier B, Smits P, McClean D, Koolen J, Windecker S, Whitbourn R, Meredith I, Wasungu L, Ediebah D, Veldhof S, Onuma Y. A Polylactide Bioresorbable Scaffold Eluting Everolimus for Treatment of Coronary Stenosis: 5-Year Follow-Up. J Am Coll Cardiol 2016;**67**(7):766-76.

148. Serruys PW, Onuma Y, Ormiston JA, de Bruyne B, Regar E, Dudek D, Thuesen L, Smits PC, Chevalier B, McClean D, Koolen J, Windecker S, Whitbourn R, Meredith I, Dorange C, Veldhof S, Miquel-Hebert K, Rapoza R, Garcia-Garcia HM. Evaluation of the second generation of a bioresorbable everolimus drug-eluting vascular scaffold for treatment of de novo coronary artery stenosis: six-month clinical and imaging outcomes. Circulation 2010;**122**(22):2301-12.

149. Gomez-Lara J, Radu M, Brugaletta S, Farooq V, Diletti R, Onuma Y, Windecker S, Thuesen L, McClean D, Koolen J, Whitbourn R, Dudek D, Smits PC, Regar E, Veldhof S, Rapoza R, Ormiston JA, Garcia-Garcia HM, Serruys PW. Serial analysis of the malapposed and uncovered struts of the new

generation of everolimus-eluting bioresorbable scaffold with optical coherence tomography. JACC Cardiovasc Interv 2011;**4**(9):992-1001.

150. Gomez-Lara J, Brugaletta S, Farooq V, Onuma Y, Diletti R, Windecker S, Thuesen L, McClean D, Koolen J, Whitbourn R, Dudek D, Smits PC, Chevalier B, Regar E, Veldhof S, Rapoza R, Ormiston JA, Garcia-Garcia HM, Serruys PW. Head-to-head comparison of the neointimal response between metallic and bioresorbable everolimus-eluting scaffolds using optical coherence tomography. JACC Cardiovasc Interv 2011;**4**(12):1271-80.

151. Bourantas CV, Papafaklis MI, Kotsia A, Farooq V, Muramatsu T, Gomez-Lara J, Zhang YJ, Iqbal J, Kalatzis FG, Naka KK, Fotiadis DI, Dorange C, Wang J, Rapoza R, Garcia-Garcia HM, Onuma Y, Michalis LK, Serruys PW. Effect of the endothelial shear stress patterns on neointimal proliferation following drug-eluting bioresorbable vascular scaffold implantation: an optical coherence tomography study. JACC Cardiovasc Interv 2014;**7**(3):315-24.

152. Bourantas CV, Farooq V, Zhang Y, Muramatsu T, Gogas BD, Thuesen L, McClean D, Chevalier B, Windecker S, Koolen J, Ormiston J, Whitbourn R, Dorange C, Rapoza R, Onuma Y, Garcia-Garcia HM, Serruys PW. Circumferential distribution of the neointima at six-month and two-year follow-up after a bioresorbable vascular scaffold implantation: a substudy of the ABSORB Cohort B Clinical Trial. EuroIntervention 2015;**10**(11):1299-306.

153. Serruys PW, Onuma Y, Garcia-Garcia HM, Muramatsu T, van Geuns RJ, de Bruyne B, Dudek D, Thuesen L, Smits PC, Chevalier B, McClean D, Koolen J, Windecker S, Whitbourn R, Meredith I, Dorange C, Veldhof S, Hebert KM, Rapoza R, Ormiston JA. Dynamics of vessel wall changes following the implantation of the absorb everolimus-eluting bioresorbable vascular scaffold: a multi-imaging modality study at 6, 12, 24 and 36 months. EuroIntervention 2014;**9**(11):1271-84.

154. Tateishi H, Suwannasom P, Sotomi Y, Nakatani S, Ishibashi Y, Tenekecioglu E, Abdelghani M, Cavalcante R, Zeng Y, Grundeken MJ, Albuquerque FN, Veldhof S, Onuma Y, Serruys PW. Edge Vascular Response After Resorption of the Everolimus-Eluting Bioresorbable Vascular Scaffold- A 5-Year Serial Optical Coherence Tomography Study. Circ J 2016;**80**(5):1131-41.

155. Sotomi Y, Ishibashi Y, Suwannasom P, Nakatani S, Cho YK, Grundeken MJ, Zeng Y, Tateishi H, Smits PC, Barragan P, Kornowski R, Gershlick AH, Windecker S, van Geuns RJ, Bartorelli AL, de Winter RJ, Tijssen J, Serruys PW, Onuma Y. Acute Gain in Minimal Lumen Area Following Implantation of Everolimus-Eluting ABSORB Biodegradable Vascular Scaffolds or Xience Metallic Stents: Intravascular Ultrasound Assessment From the ABSORB II Trial. JACC Cardiovasc Interv 2016;**9**(12):1216-27.

156. Brugaletta S, Gomez-Lara J, Diletti R, Farooq V, van Geuns RJ, de Bruyne B, Dudek D, Garcia-Garcia HM, Ormiston JA, Serruys PW. Comparison of in vivo eccentricity and symmetry indices between metallic stents and bioresorbable vascular scaffolds: insights from the ABSORB and SPIRIT trials. Catheter Cardiovasc Interv 2012;**79**(2):219-28.

157. Mauri L, Kereiakes DJ, Yeh RW, Driscoll-Shempp P, Cutlip DE, Steg PG, Normand SL, Braunwald E, Wiviott SD, Cohen DJ, Holmes DR, Jr., Krucoff MW, Hermiller J, Dauerman HL, Simon DI, Kandzari DE, Garratt KN, Lee DP, Pow TK, Ver Lee P, Rinaldi MJ, Massaro JM, Investigators DS. Twelve or 30 months of dual antiplatelet therapy after drug-eluting stents. N Engl J Med 2014;**371**(23):2155-66.

158. Fajadet J, Haude M, Joner M, Koolen J, Lee M, Tolg R, Waksman R. Magmaris preliminary recommendation upon commercial launch: a consensus from the expert panel on 14 April 2016. EuroIntervention 2016;**12**(7):828-33.

159. U.S. Department of Health and Human Services FaDACfDaRH. Use of International Standard ISO 10993-1, "Biological evaluation of medical devices - Part 1: Evaluation and testing within a risk management process: Guidance for Industry and Food and Drug Administration Staff. 2016.

160. Schwartz RS, Edelman ER, Carter A, Chronos N, Rogers C, Robinson KA, Waksman R, Weinberger J, Wilensky RL, Jensen DN, Zuckerman BD, Virmani R, Consensus C. Drug-eluting stents in preclinical studies: recommended evaluation from a consensus group. Circulation 2002;**106**(14):1867-73.

161. Faxon DP, Balelli LA, Sandborn T, Haudenschild C, Valeri R, Ryan TJ. The effect of antiplatelet therapy on platelet accumulation after experimental angioplasty in the rabbit iliac model. Int J Cardiol 1992;**36**(1):41-7.

162. Malle C, Tada T, Steigerwald K, Ughi GJ, Schuster T, Nakano M, Massberg S, Jehle J, Guagliumi G, Kastrati A, Virmani R, Byrne RA, Joner M. Tissue characterization after drug-eluting stent implantation using optical coherence tomography. Arterioscler Thromb Vasc Biol 2013;**33**(6):1376-83.

163. Nissen SE, Gurley JC, Grines CL, Booth DC, McClure R, Berk M, Fischer C, DeMaria AN. Intravascular ultrasound assessment of lumen size and wall morphology in normal subjects and patients with coronary artery disease. Circulation 1991;**84**(3):1087-99.

164. Mintz GS, Kent KM, Pichard AD, Satler LF, Popma JJ, Leon MB. Contribution of inadequate arterial remodeling to the development of focal coronary artery stenoses. An intravascular ultrasound study. Circulation 1997;**95**(7):1791-8.

165. Huang D, Swanson EA, Lin CP, Schuman JS, Stinson WG, Chang W, Hee MR, Flotte T, Gregory K, Puliafito CA, et al. Optical coherence tomography. Science 1991;**254**(5035):1178-81.

166. Kawase Y, Hoshino K, Yoneyama R, McGregor J, Hajjar RJ, Jang IK, Hayase M. In vivo volumetric analysis of coronary stent using optical coherence tomography with a novel balloon occlusion-flushing catheter: a comparison with intravascular ultrasound. Ultrasound Med Biol 2005;**31**(10):1343-9.

167. Yun SH, Tearney GJ, Vakoc BJ, Shishkov M, Oh WY, Desjardins AE, Suter MJ, Chan RC, Evans JA, Jang IK, Nishioka NS, de Boer JF, Bouma BE. Comprehensive volumetric optical microscopy in vivo. Nat Med 2006;**12**(12):1429-33.

168. Onuma Y, Serruys PW, Perkins LE, Okamura T, Gonzalo N, Garcia-Garcia HM, Regar E, Kamberi M, Powers JC, Rapoza R, van Beusekom H, van der Giessen W, Virmani R. Intracoronary optical coherence tomography and histology at 1 month and 2, 3, and 4 years after implantation of everolimus-eluting bioresorbable vascular scaffolds in a porcine coronary artery model: an attempt to decipher the human optical coherence tomography images in the ABSORB trial. Circulation 2010;**122**(22):2288-300.

169. Lane JP, Perkins LE, Sheehy AJ, Pacheco EJ, Frie MP, Lambert BJ, Rapoza RJ, Virmani R. Lumen gain and restoration of pulsatility after implantation of a bioresorbable vascular scaffold in porcine coronary arteries. JACC Cardiovasc Interv 2014;**7**(6):688-95.

170. Strandberg E, Zeltinger J, Schulz DG, Kaluza GL. Late positive remodeling and late lumen gain contribute to vascular restoration by a non-drug eluting bioresorbable scaffold: a four-year intravascular ultrasound study in normal porcine coronary arteries. Circ Cardiovasc Interv 2012;**5**(1):39-46.

171. Cutlip DE, Windecker S, Mehran R, Boam A, Cohen DJ, van Es GA, Steg PG, Morel MA, Mauri L, Vranckx P, McFadden E, Lansky A, Hamon M, Krucoff MW, Serruys PW. Clinical end points in coronary stent trials: a case for standardized definitions. Circulation 2007;**115**(17):2344-51.

Supplementary Appendix to

REPORT OF THE ESC-EAPCI TASK FORCE ON THE EVALUATION AND USE OF BIORESORBABLE SCAFFOLDS FOR PERCUTANEOUS CORONARY INTERVENTION

Task Force Members:

Robert A. Byrne (DE), Giulio G. Stefanini (IT), Davide Capodanno (IT), Yoshi Onuma (NL), Andreas Baumbach (UK), Javier Escaned (ES), Michael Haude (DE), Stefan James (SE), Michael Joner (DE), Peter Jüni (CH), Adnan Kastrati (DE), Semih Oktay (USA), William Wijns (IE), Patrick W. Serruys (NL), Stephan Windecker (CH)

18 APRIL 2017

Supplementary Table 1. Overview of the current status of development of bioresorbable scaffolds

Company	Product name	Biodegradable material used for backbone	Coating	Drug elution	Other features	Phase of development
Abbott	Absorb	PLLA	PDLLA	Everolimus	strut thickness 150 µm	CE mark, FDA approval
Abbott	Absorb GT1	PLLA	PDLLA	Everolimus	strut thickness 150 µm	CE mark, FDA approval
ART	ART Pure	PDLLA	none	none	NA	CE mark
BIOTRONIK	Magmaris	WE43 alloy, 93% Mg, and 7% rare earth elements	PLLA	Sirolimus	strut thickness 150 µm	CE mark
Elixir	DESolve 100	PLLA	bioresorbable polymer	Novolimus	strut thickness 100 µm	CE mark
Elixir	DESolve 150	PLLA	bioresorbable polymer	Novolimus	strut thickness 150 µm	CE mark
Elixir	DESolve XL	PLLA	bioresorbable polymer	Novolimus	NA	CE mark
REVA	Fantom	Desaminotyrosine polycarbonate	Desaminotyrosine polycarbonate	Sirolimus	strut thickness 125 µm	CE mark approval submitted
Amaranth Medical	APTITUDE	PLLA	NA	Sirolimus	strut thickness 120 µm	Clinical studies underway
Amaranth Medical	FORTITUDE	PLLA	bioresorbable polymer	Sirolimus	strut thickness 150 µm	Clinical studies underway

Boston Scientific	FAST	PLLA	PLGA	Everolimus	strut thickness 100 µm	Clinical studies underway
Huaan	XINSORB	PLA/PCL/PGA	PDLLA+PLLA	Sirolimus	strut thickness 160 µm	Clinical studies underway
Kyoto Medical	IGAKI-TAMAI	PLLA	none	none	strut thickness 170 µm	Clinical studies underway
Lepu	NeoVas	PLLA	PDLA	Sirolimus	strut thickness 170 µm	Clinical studies underway
Manli Cardiology	Mirage	PLLA	PLLA	Sirolimus	strut thickness 125 µm for <=3 mm and 150 µm for ≥3.5 mm	Clinical studies underway
Meril	MeRes100	PLLA	PDLLA	Sirolimus	strut thickness 100 µm	Clinical studies underway
MicroPort	Firesorb	PLLA	PDLLA	Sirolimus	100 µm (2.5, 2.75 mm) and 125 µm (3.0, 4.0 mm)	Clinical studies underway
Xenogenics	Ideal BioStent	polylactide anhydride mixed with a polymer of salicylic acid with a sebacic acid linker	Salicilate linked with adipic acid	Sirolimus	strut thickness 175 µm	Clinical studies underway
Arterius	ArterioSorb	PLLA	Bioresorbable polymer	Sirolimus	2 versions: 95 and 120 µm (3.5 mm	Preclinical study underway

					device)	
Cardionovum	ReNATURAL (M) ReNATURAL (P)	(M)=metal, (P)=PLLA	NA	Sirolimus	NA	Preclinical study underway
Elixir	AMITY	PLLA	bioresorbable polymer	Novolimus	strut thickness 100 µm	Preclinical study underway
Elixir	DESolve Cx	PLLA	bioresorbable polymer	Novolimus	strut thickness 120 µm	Preclinical study underway
Envision Scientific	IMBIBE	magnesium	Nanocarrier layer: Top-coat that carries sirolimus Sandwich layer: Scaffold degradation-controlling jacket with PLA and sirolimus	Sirolimus	strut thickness 120 µm	Preclinical study underway
LifeTech	LifeTech Iron-Based BRS	Nitrided iron	"special" polymer	Sirolimus	strut thickness 70 to 80 µm	Preclinical study underway
Medtronic	Mg Spiral	Magnesium	“family of degradable polymers”	Sirolimus	strut thickness 120 µm	Preclinical study underway
OrbusNeich	On-AVS	PLLA, PLCL, PDLA	PLLA+PDLA	Sirolimus	strut thickness 150 µm, coated with +CD34 antibody	Preclinical study underway
QualiMed	Unity BRS	Magnesium	PLGA	Sirolimus	strut thickness 120 µm	Preclinical study underway
S3V	Avatar	Not available	Bioresorbable polymer	NA	NA	Preclinical study

						underway
Scitech	Scitech MBRS	Magnesium	NA	none	NA	Preclinical study underway
Terumo Corporation	Terumo/ART DCBS	PDLLA	Bioresorbable polymer	Sirolimus	strut thickness 170 µm	Preclinical study underway
Zorion Medical	ZMED	Magnesium/PLGA	NA	NA	NA	Preclinical study underway
Abbott	Next-Gen Absorb	PLLA	PDLLA	Everolimus	strut thickness 100 µm	In development
Sahajanand	Sahajanand Bioabsorbable	PLLA	Bioresorbable polymer	Sirolimus	NA	In development
Amaranth Medical	MAGNITUDE	PLLA	Bioresorbable polymer	Sirolimus	strut thickness 100 µm	No information
MicroPort	Firefalcon	PLLA	NA	NA	NA	No information
Shanghai Bio-Heart	Galaxy	PLA	Bioresorbable polymer	Sirolimus	NA	No information

Abbreviations: BRS = bioresorbable scaffolds; PLLA = poly-L-lactide; PDLLA = poly(L-lactide-co-D,L-lactide); PLGA = poly lactic-co-glycolic acid; PLA = poly(lactic acid); PCL = polycaprolactone; PGA = polyglycolic acid; PDLA = poly-D-lactide; TMC = trimethylene carbonate; NA = data not available.

Supplementary Table 2. Clinical outcomes in studies of bioresorbable scaffolds in patients with acute coronary syndromes

Study	Year	BVS	Controls	Sites	UA/NSTEMI	STEMI	Outcomes
Gori et al. [70]	2014	150	103 DES	1	56%	44%	• In-hospital: death 0.7%, MI 2.1%, definite ST 1.4% • 30-day: death 1.4%, MI 4.0%, TLR 0.0%, definite ST 2.0%, probable ST 0.7%, MACE 10.7%
POLAR-ACS [71]	2014	100	-	12	84%	16%	• In-hospital: death 0.0%, MI 3.1%, TLR 0.0%, definite ST 0.0%, MACE 2.0% • 12-month: death 0.0%, MI 3.1%, TLR 2.0%, definite ST 2.0%, MACE 4.1%
Gori et al. [72]	2015	133	-	1	62%	38%	• 6-month: cardiac death 3.0%, MI 4.5%, TLR 4.5%, TVR 5.3%, definite ST 2.3%, probable ST 0.8%, MACE 9.0% • 12-month: cardiac death 3.0%, MI 6.8%, TLR 6.8%, TVR 10.6%, definite ST 2.3%, probable ST 0.8%, MACE 13.5%
Felix et al. [73]	2016	255	95 SA	2	53%	47%	• 12-month: death 0.0%, cardiac death 0.0%, MI 5.1%, TLR 3.1%, TVR 3.5%, definite ST 2.0%, probable ST 0.4%, MACE 5.5%
Rzeszutko et al. [74]	2016	250	215 SA	30	74%	26%	• 12-month: death 0.8%, MI 2.0%, TLR 2.4%, TVR 3.5%, definite ST 0.8%, MACE 4.4%
Schnorbus et al. [75]	2017	697	780 SA	11	64%	36%	• 12-month: death 1.8%, MI 2.1%, TLR 4:7%, TVR 7:8%, definite ST 2:6%, MACE 6.4%

Outcome data are reported for the bioresorbable scaffold group, at the longest follow-up available. Abbreviations: BVS, bioresorbable vascular scaffolds; DES, drug-eluting stent; MACE, major adverse cardiac events; MI, myocardial infarction; TLR, target lesion revascularization; SA, stable angina; ST, scaffold thrombosis; UA, unstable angina.

Supplementary Table 3. Clinical outcomes in studies of bioresorbable scaffolds in patients with ST-segment elevation myocardial infarction

Study	Year	BVS	Controls	Sites	Follow up	Outcomes
Kajiya et al.[77]	2013	11	-	1	53.0±45.9 days	Death 9.1%, MI 0.0%, definite ST 0.0%, MACE 9.1%
BVS STEMI First [78]	2014	49	-	1	30 days	Cardiac death 0.0%, MI 2.6%, TVR 0.0%, definite ST 0.0%, MACE 2.6%
Wiebe et al. [79]	2014	25	-	1	132.7±68.7 days	Death 4.0%, MI 0.0%, TLR 0.0%, TVR 4.0%, definite ST 0.0%, MACE 8.0%
PRAGUE 19 [80]	2014	41	57 BMS or DES	2	6 months	Death 0.0%, MI 2.4%, TLR 2.4%, TVR 2.4%, definite ST 2.4%, MACE 4.9%
BVS-RAI [81]	2015	74	-	11	6 months	Death 0.0%, MI 2.7%, TLR 4.1%, definite ST 1.3%
BVS-RAI [82]	2015	122	441	11	220 (IQR 178-369) days	Death 0.8%, MI 4.1%, TLR 4.1%, TVR 4.1%, definite ST 2.5%
Kochman et al. [84]	2015	23	-	1	229 (IQR 199-248) days	Death 0.0%, MI 4.3%, definite ST 4.3%
Kochman et al. [83]	2015	19	-	1	11.6±2.3 months	Death 0.0%, MI 0.0%, TLR 0.0%, definite ST 0.0%
BVS-EXAMINATION [48]	2015	290	580 BMS or DES	6	12 months	Cardiac death 2.1%, MI 2.1%, TLR 1.7%, definite ST 1.7%, MACE 4.1%
PRAGUE 19 [85]	2015	67	-	2	12 months	Death 2.9%, MI 2.9%, TLR 1.5%, definite ST 1.5%
TROFI II [37]	2015	95	96	8	6 months	Death 0.0%, MI 1.1, TLR 2.1%, ischemic driven TLR: 1.1%, non-ischemic driven TLR: 1.1%; definite ST 1.0%, DOCE.1%
Chakraborty et al. [86]	2016	35	180 DES	1	11.5±5 months	Death 1.0%, MI 0.0%, TLR 0.0%, TVR 0.0%, definite ST 0.0%

BVS STEMI First [87]	2016	151	151 DES	1	18 months	Death 2.8%, MI 6.3%, TLR 5.7%, definite ST 4.3%, MACE 9.8%
PRAGUE 19 [90]	2016	40	53 BMS or DES	2	24 months	Death 2.5%, MI 2.5%, TVR 2.5%, MACE 7.5%
BVS-EXAMINATION [89]	2016	290	580 BMS or DES	6	24 months	Definite ST 3.3%, MACE 6.2%
PRAGUE 19 [88]	2016	69	125 BMS or DES	2	24 months	MACE 7.2%

Outcome data are reported for the bioresorbable scaffold group, at the longest follow-up available. Abbreviations: BMS, bare metal stent; BVS, bioresorbable vascular scaffolds; DES, drug-eluting stent; DOCE, device-oriented composite events; IQR, interquartile range; MACE, major adverse cardiac events; MI, myocardial infarction; TLR, target lesion revascularization; SA, stable angina; ST, scaffold thrombosis

Supplementary Table 4. Clinical outcomes in studies of bioresorbable vascular scaffolds in patients with chronic total occlusions

Study	Year	CTO	Controls	Sites	Follow up	Outcomes
Wiebe et al.[98]	2015	23	-	1	108 (IQR 79.5-214.5) days	Death 0.0%, MI 0.0%, TLR 4.3%, definite ST 4.3%, MACE 4.3%
CTO-ABSORB [99]	2015	35	-	1	6 months	Death 0.0%, MI 0.0%, TLR 0.0%, definite ST 0.0%, MACE 0.0%
Ojeda et al. [100]	2015	46		1	13±5 months	Death 0.0%, MI 0.0%, TLR 4.8%
Goktekin et al. [101]	2015	76	-	3	11 (IQR 7-18) months	Death 0.0%, MI 0.0%, TLR 4.3%, MACE 4.3%, ST 0.0%
GHOST-CTO [102]	2016	42	54	1	In hospital	MACE 0.0%
CTO-ABSORB [103]	2016	35	-	1	12 months	Death 0.0%, MI 0.0%, TLR 0.0%, definite ST 0.0%, MACE 0.0%
Ozel et al. [104]	2016	41	-	1	12 months	Death 0.0%, MI 2.4%, TLR 2.4%, TVR 12.2%
Lesiak et al. [105]	2016	40	-	1	9 months	Death 0.0%, MI 2.5%, TLR 2.5%, definite ST 2.5%, MACE 2.5%
Fam et al. [106]	2017	105	-	MC	6 months	Death 0.0%, MI 1.0%, TLR 1.0%
Mitomo et al. [107]	2017	65	-	5	450 (IQR 230-703) days	Death 0.0%, MI 0.0%, TLR 0.0%

Outcome data are reported for the bioresorbable scaffold group, at the longest follow-up available. Abbreviations: BMS, bare metal stent; CTO, chronic total occlusion; IQR, interquartile range; MACE, major adverse cardiac events; MI, myocardial infarction; MC, multicenter (not otherwise specified); TLR, target lesion revascularization; ST, scaffold thrombosis.