



European Association of Cardiovascular Imaging (EACVI) position paper: multimodality imaging in pericardial disease

Bernard Cosyns^{1*}, Sven Plein², Petros Nihoyanopoulos³, Otto Smiseth⁴, Stephan Achenbach⁵, Maria Joao Andrade⁶, Mauro Pepi⁷, Arsen Ristic⁸, Massimo Imazio⁹, Bernard Paelinck¹⁰, and Patrizio Lancellotti¹¹ On behalf of the European Association of Cardiovascular Imaging (EACVI) and European Society of Cardiology Working Group (ESC WG) on Myocardial and Pericardial diseases

¹Department of Cardiology, Universtair Ziekenhuis Brussel, Centrum Voor Hart-en Vaatziekten and CHIREC, 101 Laarbeeklaan, 1090 Brussels, Belgium; ²The Division of Cardiovascular and Diabetes Research, Multidisciplinary Cardiovascular Research Centre, Leeds Institute of Genetics, Health and Therapeutics, University of Leeds, Leeds, UK; ³Department of Cardiology, Imperial College, NHLI Hammersmith Hospital London, London, UK; ⁴Division of Cardiovascular and Pulmonary Diseases, Oslo University Hospital, Oslo, Norway; ⁵Department of Cardiology, University Hospital Erlangen, Medizinische Klinik 2, Erlangen, Germany; ⁶Department of Cardiology, Hospital Santa Cruz, Instituto Cardiovascular de Lisboa, Lisboa, Portugal; ⁷Department of Cardiology, Centro Cardiologico Monzino, IRCCS, Milan, Italy; ⁸Department of Cardiology, Clinical Center of Serbia, Belgrad, Serbia; ⁹Department of Cardiology, Maria Vittoria Hospital, Turin, Italy; ¹⁰Cardiac Imaging, Department of Cardiac Surgery, Antwerp University Hospital, Antwerp, Belgium; and ¹¹Department of Cardiology, University of Liege Hospital, GIGA Cardiovascular Sciences, Heart Valve Clinic, CHU Sart Tilman, Liege, Belgium

Received 29 May 2014; accepted after revision 31 May 2014

Although pericardial diseases are common in the daily clinical practice and can result in a significant morbidity and mortality, imaging of patients with suspected or known pericardial disorders remain challenging. Multimodality imaging is part of the management of pericardial diseases. Echocardiography, cardiac computed tomography, and cardiovascular magnetic resonance are often used as complementary imaging modalities. The choice of one or multiple imaging modalities is driven by the clinical context or conditions of the patient. The scope of the present document is to highlight the respective role of each technique according to the clinical context in the diagnosis and management of pericardial diseases.

Keywords

Pericardial disease • Pericardial effusion • Constrictive pericarditis • Echocardiography
• Cardiac computed tomography • Cardiac magnetic resonance imaging

Introduction

Pericardial disease represents a wide spectrum of processes involving or damaging the pericardium. Imaging is essential for an appropriate diagnosis of pericardial disease and its complications and plays an important role in its management. In addition to chest radiography, three main non-invasive imaging techniques are available for assessing the pericardium in clinical practice: echocardiography, cardiac computed tomography (CT) and cardiovascular magnetic resonance (CMR). All these imaging modalities have evolved over time and a critical appraisal of their strengths and limitations is required for an integrated use in order to address to specific clinical needs. The different imaging modalities are often complementary and the choice of one or multiple imaging modalities is driven by the clinical context or conditions of the patient. The scope of the present document is to

highlight the respective role of each technique according to the clinical context in the diagnosis of pericardial disease.

Imaging modalities in pericardial disease

Among all imaging modalities that can be used for the evaluation of pericardial disease, chest X-ray, echocardiography, cardiac CT, and CMR are the most common. Chest X-ray is, however, of limited value, unless the pericardial effusion is massive (typical bottle-like shape cardiomegaly with large pericardial effusions) or pericardial calcifications are present (<25% of cases of constrictive pericarditis). An additional role of chest X-ray is the detection of concomitant lung, mediastinal, and pleural diseases that may be responsible of pericardial manifestations (i.e. pulmonary tuberculosis, lung cancer).¹

* Corresponding author. Tel: +32 23890440, Fax: +32 23873065, Email: bcosyns@gmail.com

Published on behalf of the European Society of Cardiology. All rights reserved. © The Author 2014. For permissions please email: journals.permissions@oup.com.

Echocardiography

Transthoracic Doppler echocardiography is considered as the first-line imaging modality in almost all types of pericardial diseases because it is simple and quick to perform, widely available and safe.² However, two-dimensional (2D) echocardiography has several weaknesses, mainly related to its dependence on a good acoustic window, and to the inability to image the entire pericardium.³ New developments may be helpful to reduce or to avoid some of these limitations. Image quality has improved dramatically with new probes with better crystals, better spatial resolution and signal-noise ratio. The use of tissue harmonic imaging has also improved the field of view reducing the inadequate examinations to 5–10%. In contrast echocardiography, micro-bubbles small enough to cross the pulmonary capillaries are injected intravenously and opacify the left ventricular (LV) cavity and the myocardium. The main application of contrast echocardiography is improved delineation of the endocardial border (better LV function and volumes assessment), improved tissue characterization, and myocardial perfusion. In pericardial disease, the use of contrast agents may improve the detection of pericardial effusion especially in the acute setting of myocardial infarction (MI) with pseudo-aneurysm and free-wall rupture.⁴ Tissue Doppler imaging velocity analysis is now part of all echocardiographic examinations in patients with pericardial disease for making the difference between constrictive pericarditis and restrictive cardiomyopathy. A proposed e' cut-off value <7 cm/s supports the diagnosis of restrictive cardiomyopathy. Deformation imaging has entered the clinical arena mainly to assess the impact of various pathological conditions on ventricular function. Strain is a measure of how much an object has been deformed, and several formulas can be used to calculate different types of strain. In cardiac imaging, strain is most often calculated as per cent or fractional change in myocardial dimension, during each cardiac cycle. Strain can be measured by echocardiography using tissue Doppler,⁵ but the preferred modality is speckle-tracking echocardiography (STE).^{6,7}

In addition, echocardiography allows the assessment of the twist-motion of the LV about its long axis.

LV rotation can be measured clinically by STE and twist and torsion can be calculated.^{8,9} Twist refers to the absolute apex-to-base difference in LV rotation and is measured as twist angle and is expressed in degrees. The term torsion refers to the base-to-apex gradient in rotation angle along the LV long axis and is expressed in degrees per centimetre.

In a normal individual, the heart slides and twists easily within the parietal pericardium, which is lubricated by a small amount of fluid. The importance of this motion has been illustrated in experiments in which the epicardium was fixed to the pericardium.¹⁰ In this study, pericardial adhesions reduced LV twist by limiting the free motion of the heart inside the pericardium. Pericardial diseases cause subepicardial tethering and predominant loss of circumferential strain and LV twist mechanics while relatively sparing subendocardial function.¹¹

In patients with the congenital absence of the pericardium, a reduction in LV twist has been reported.¹² Consistent with this clinical observation from a small number of patients, it was observed in a dog model that opening the pericardium was associated with a reduction

in LV twist.¹³ The authors speculated that the reduction in LV twist is related to a change from elliptical to a more global shape of the LV after pericardial opening.

Finally, three-dimensional echocardiography has the potential to provide a complete evaluation of the entire pericardium in any anatomical plane, and, therefore, to detect loculated effusions. New softwares for an accurate quantification of the volume of liquid in the pericardium are under evaluation.

Cardiac CT

CT is a widely available technique with a short acquisition time of a few seconds. Modern computed CT scanners have a spatial resolution well <1.0 mm. High temporal resolution and dedicated image acquisition techniques, which either trigger image acquisition to the patient's electrocardiogram or retrospectively select X-ray data acquired during suitable segments of the cardiac cycle for image reconstruction, provide for the ability to obtain data sets largely free of motion artefact.¹⁴ While cardiac CT is in most cases performed to visualize the coronary arteries, it does provide high-resolution imaging of all cardiac structures, including the pericardium. The pericardium can be visualized both in non-contrast and contrast-enhanced CT data sets. Following the administration of i.v. contrast, enhancement of thickened pericardium can be observed in case of suspected pericarditis or tumour infiltration.^{3,15–17} However, the CT attenuation of pericardium is similar to that of the myocardium. Hence, the pericardium can only be clearly visualized, where it is surrounded by fat and not immediately adjacent to the myocardium (Figure 1). It usually appears as a thin line and is best delineated on the anterior face of the heart. Lack of visualization by CT, especially on the posterior surface of the heart, is not a sufficient criterion to make the diagnosis of absent pericardium. Furthermore, CT is particularly sensitive for identifying pericardial calcification. CT can obtain secondary functional information, such as enlargement of the atria and venae cavae in cases of pericardial constriction, but ventricular functional parameters can be acquired only with retrospective ECG-gated acquisitions, which are associated with an increased radiation dose. Moreover, CT density measurements may enable the initial characterization of pericardial fluid better than echocardiography. On CT, generally, pericardial effusions are of low density in the range of 0 to 20 Hounsfield units (HU). When the effusion contains higher amounts of protein, such as in bacterial infections, or when it is haemorrhagic, its density may raise to 50 HU and more. Inflamed pericardium may also show contrast enhancement.¹⁸

CMR

CMR is a useful additional test for the diagnosis of many pericardial diseases, especially if echocardiography is equivocal, localized disease is suspected, echocardiographic image quality is suboptimal or if additional pathology is suspected. CMR can provide information on the extent of pericardial disease, abnormalities in surrounding structures and allows an accurate measurement of pericardial and related structures. It provides superior tissue characterization including an estimate of inflammation. Investigating pericardial disease with CMR includes morphological imaging to assess pericardial structure and to perform tissue characterization and functional imaging to measure ventricular function and intracardiac flows.

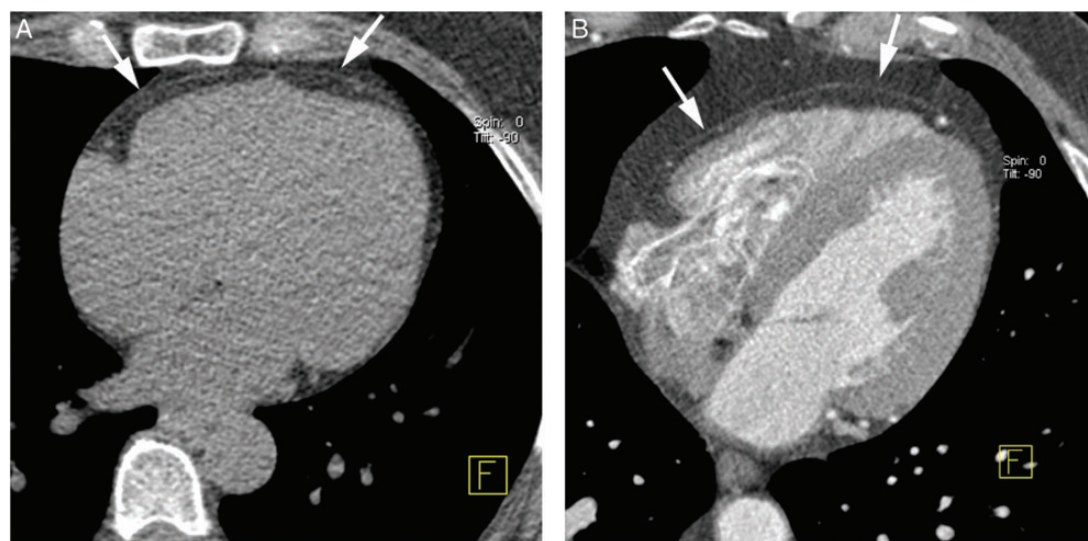


Figure 1: Visualization of the pericardium in computed tomography. Both in non-contrast acquisitions (A) as well as in contrast-enhanced acquisitions (B), the pericardium can be visualized as a thin line embedded in the epicardiac and paracardiac fat (arrows). Where the pericardium is immediately adjacent to the myocardium, it can often not be visualized. Frequently, this is the case along the posterior margin of the heart.

Black blood T1-weighted spin-echo CMR is used for morphological assessment of the pericardium, the intrathoracic and mediastinal structures. Typically, a stack of axially oriented images covering the thorax and further images in standardized cardiac planes, such as the LV short axis, are acquired. From black blood images, the pericardial thickness can be measured and any thoracic abnormalities, such as lymphnodes, pleural effusions, or masses, can be identified.

Black blood T2-weighted spin-echo CMR images highlight fluid-rich structures, such as pericardial effusion or myocardial oedema, which may occur in concomitant myocardial disease such as myocarditis. T2-weighted images are typically acquired in identical scan planes as T1-weighted images and contribute to tissue characterization of pericardial and other mass lesions.

High-resolution gradient-echo cine-images with steady-state-free-precession pulse sequences are typically acquired in a stack covering the heart in the LV short-axis planes and in orthogonal long-axis planes. These images allow accurate quantitation of cardiac chamber size and function, including pathological effects such as RV/RA collapse. In pericardial disease, cine-images also contribute to the measurement of pericardial thickness and pericardial effusion.

Real-time cine imaging with fast but lower-resolution cine CMR techniques is used to assess dynamic physiological effects of pericardial disease such as ventricular interdependence. For this purpose, real-time cine-images are typically acquired in the several LV short-axis views and the horizontal long-axis views during respiration.

CMR tagging techniques can be added to the imaging protocol to delineate adhesion of the pericardial layers in constrictive pericarditis. These are best acquired in targeted planes depending on the observed pathology.

Dynamic contrast-enhanced CMR imaging is recommended to assess the blood supply of pericardial or cardiac mass lesions.

Late gadolinium enhancement (LGE) can be useful to assess inflammatory pericarditis, where the pericardium can show strong signal

enhancement, and concomitant myocardial pathology (e.g. myocarditis). In addition, the method contributes to the tissue characterization of masses.

Velocity-encoded CMR can be performed to delineate flow patterns in suspected restrictive cardiac filling.

Advantages and limitations of each imaging modalities are summarized in Table 1.

Normal findings

Normal anatomy and physiology

Understanding the anatomy of the pericardium as well as the interaction between pericardial pathology and cardiovascular function is key to detecting and assessing pericardial disease. The pericardium is a double-layered membrane, which forms a sac surrounding the heart and the origin of the great vessels. The outer fibrous layer has attachments to the surrounding structures, while the inner serous layer lies adjacent to the surface of the heart. The external surface of the heart is also covered with a simple serous membrane, the epicardium, beneath which is a thin layer of dense fibrous connective tissue and variable amounts of adipose tissue. The pericardial lining secretes pericardial fluid (pericardial fluid volume normally <35 mL of serous fluid), which lubricates the surfaces of the heart and provides a minimal friction environment during mechanical function. At the base of the heart, the reflections of the pericardial sac between the great vessels form several extensions of the pericardial cavity called pericardial sinuses: the transverse sinus, dorsal to the ascending aorta, and the oblique sinus located behind the left atrium (LA), so that the posterior wall of the LA is actually separated from the pericardial space.

In normal conditions, in the absence of pericardial disease, the discrimination of the pericardium from the myocardium, using imaging

Table 1 Advantages and limitations of imaging modalities in pericardial disease

Echocardiography	Cardiac CT	CMR
Advantages		
First line for diagnosis and follow-up	Better anatomic description	Better anatomic description
Widely available	Evaluation of associated/extracardiac disease	Evaluation of associated/extracardiac disease
Low cost	Pre-operative planning	Pre-operative planning
Safe and repeatable	Detection of pericardial calcification	Repeatable
Bedside (critically ill and pericardiocentesis)		
Modalities		
M-mode	Axial imaging	Bright blood-single-shot SSFP
Two-dimensional echocardiography	Multiplanar reconstruction	Black blood images (+STIR)
Doppler	Volume rendered imaging	Tagged cine-images
Tissue Doppler velocities	Cine-imaging	Bright blood cine-images
Deformation Imaging		Late gadolinium enhancement images
3D echocardiography		Real-time gradient-echo cine-images
Contrast echocardiography		
Twist and rotation		
Limitations		
Limited windows	Ionizing radiation	Time-consuming, high cost
Poor quality imaging	Iodinated contrast	Difficult in case of arrhythmias
Operator dependent	Functional evaluation only possible with retrospective-gated studies	Contraindicated with some devices (pacemakers, AICD. . .)
Limited tissue characterization	Difficult in case of arrhythmias	Calcifications not well visualized
	Need for breath-hold	Gadolinium not recommended if glomerular filtration rate <30 mL/min)
	Haemodynamically stable patients only	Need for breath-hold
		Haemodynamically stable patients only

SSFP, steady-state-free precession; STIR, short inversion time inversion-recovery.
Adapted from Verhaert et al.¹⁵

techniques, is difficult, and requires the presence of epicardial fat or pericardial fluid.

Normal findings

Echocardiography

Echocardiographically, the pericardium is visualized as a thin, hyper-echogenic linear echo-dense structure surrounding the heart, most evident at the posterior cardiac interface. The pericardium can usually be visualized in all standard echocardiographic windows such that diffuse pericardial pathology can be observed in most views. Localized pericardial disease, such as loculated fluid collections or haematomas, may require more focused examinations. In patients with pericardial fluid or infiltration, the pericardium appears more prominent and distinction between the parietal and visceral layers is often more evident. Normal pericardial thickness is <3 mm, but its appearance on transthoracic echocardiography is influenced by image quality and instrument settings. In general, for the evaluation of pericardial thickness, sensitivity is greater with transoesophageal than transthoracic echocardiography. However, accuracy is higher with other imaging modalities, such as cardiac CT or CMR.

Cardiac CT

When assessing the thickness of the pericardium, care has to be taken to assure that measurements are made in planes, which provide an exactly orthogonal view onto the pericardium. The normal thickness of the pericardium on high-resolution CT scans was found to be between 1 and 2 mm, the upper limit of normal of the thinnest point of the pericardium was 0.7 mm in thin-slice CT and 1.2 mm in thick-slice CT.¹⁹ The upper limit of normal of the thickest section is 2 mm in high-resolution CT.^{3,16} However, even thicknesses up to 4 mm have been reported as normal.^{3,20} The most problematic issue regarding the assessment of pericardial thickening is the fact that, again due to an overlap in CT attenuation values, it may be difficult to distinguish a slightly thickened pericardium from small collections of pericardial fluid (Figure 2).

CMR

The normal pericardium is best measured from black blood spin-echo or cine gradient-echo CMR images, where it appears as a thin low-intensity layer surrounded in most regions by high-signal fatty tissue.^{21,22} Normal pericardium on CMR is usually considered to be <2 mm thick, but analogous to CT, an upper limit for normal pericardial thickness has not been conclusively defined. CMR also

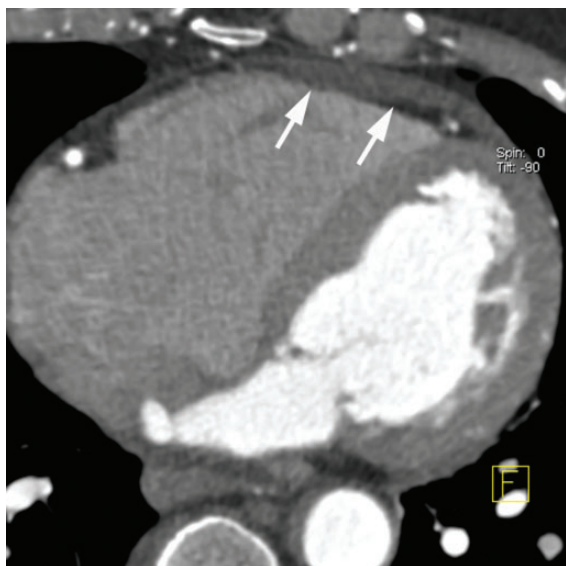

Figure 2: Small accumulations of fluid can mimic pericardial thickening in CT, since the CT attenuation of fluid and pericardial tissue can overlap. Here, some pericardial fluid creates the impression of thickened pericardium anterior to the right ventricle (arrows).

allows the assessment of the transverse pericardial sinus and the pre-aortic and retro-aortic pericardial recesses. The pericardial space normally contains a small amount of pericardial fluid that can be demonstrated on black blood and cine-images. On cine-images, unrestricted movement of the myocardium against the pericardium is observed in normal cases.

Use of non-invasive imaging in various clinical scenarios

Acute pericardial disease

The clinical syndrome of acute pericarditis is commonly encountered in clinical practice (Figure 3). According to the 2004 ESC recommendations,²³ acute pericarditis may present with or without clinical signs of cardiac tamponade. Cardiac tamponade requires a specific management as set out below. The use of the available non-invasive imaging modalities for the management of each individual patient is guided by the initial findings and clinical course.²⁴ A distinction between patients with a non-complicated course and/or small amount of effusion and patients with a complicated course (recurrence, refractory to medical treatment) and/or moderate or large amount of effusion has to be made.

In most patients, the cause of acute pericarditis is thought to be idiopathic because the yield of diagnostic tests to confirm aetiology has been relatively low. Known causes include viral and bacterial micro-organisms (especially tuberculosis which nowadays represents the most important cause of pericardial diseases all over the world), systemic diseases, neoplastic invasion of the pericardium, uraemia, invasive cardiothoracic procedures, and chest trauma.²⁵

Tuberculous pericarditis is still a major cause of the disease in developing countries and also in immunocompromised patients, like patients with AIDS. Acute pericarditis has been reported in as many as 25% of post-MI patients, and may also occur in association with acute aortic dissection.²⁶

In the vast majority of patients, the diagnosis of acute pericarditis is easily made, based on the history of chest pain, the presence of a pericardial friction rub, and the typical changes on electrocardiogram. Elevated markers of acute inflammation are often present.²⁷

Echocardiography remains the initial imaging method of choice for the majority of patients in whom acute pericarditis is suspected and, most of the times, it is the only imaging modality needed. Detection of pericardial effusion is considered diagnostic criteria for pericarditis.²⁸

Uncomplicated acute pericarditis/small amount of or no effusion

Although in patients with a clear diagnosis of uncomplicated idiopathic acute pericarditis imaging may not be required, the threshold for ordering a transthoracic echocardiogram (TTE) is usually low. Although a pericardial effusion may be absent in a majority of patients with acute pericarditis (up to 60%), it is useful to confirm the diagnosis when a pericardial effusion is found. In most cases, pericardial effusions are small and not a cause for concern.

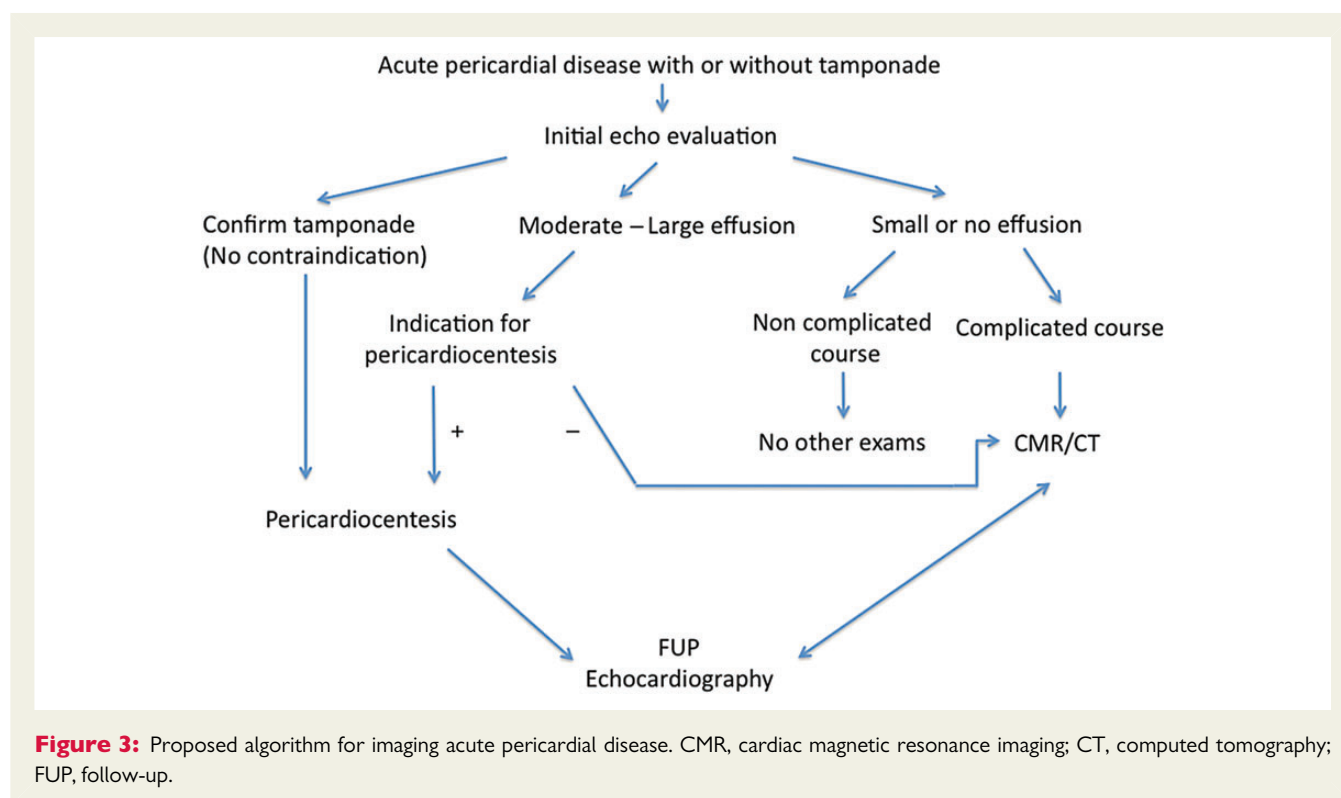
Echocardiography can also be useful when the diagnosis is uncertain to assist in the differential diagnosis with acute coronary syndrome, aortic dissection, and pulmonary embolism. It may also be valuable to unmask the underlying cause of pericarditis or, in patients who have concomitant myocarditis and elevated troponin values, to delineate if associated myocarditis is severe enough to alter ventricular function. No other imaging modalities are usually required in this setting. CMR may be of added value in the clinical context of associated myocarditis even in the absence of wall motion abnormalities on echocardiography.

Recommendations

Acute pericarditis with small or no effusion (non-complicated course)	Class
TTE to confirm clinical diagnosis	Recommended
CMR to confirm clinical diagnosis if clinical context of myocarditis	Recommended
CT/CMR to confirm clinical diagnosis if echocardiography inconclusive	Not recommended
TOE if poor TTE quality of imaging	Not recommended
TTE for follow-up	Not recommended

Complicated acute pericarditis/moderate-to-large effusion without tamponade

TTE is advised when pericarditis is associated with indicators of worse outcome (fever $>38^{\circ}$, subacute course, or failure of initial response to standard therapy), and mandatory when there is suspected or known previous heart disease, concern for features of constrictive physiology (in cases of prolonged or recurrent pericarditis). Moreover, by exclusion of a large pericardial effusion, 2D echocardiography is particularly helpful to assist in the decision to treat patients



in an outpatient setting, whenever other poor prognostic indicators are absent. According to the aetiology of pericarditis, the acute inflammatory response can produce either serous (more common in viral pericarditis) or haemorrhagic and exudative fluid (the case of tuberculous, neoplastic, and purulent pericarditis). Depending on the velocity of the fluid accumulation and on the total volume reached, diastolic filling of the right heart may be impaired, even in the absence of clinical cardiac tamponade. This situation may require drainage and aetiology search, because large pericardial effusions are more frequent in pericarditis of non-idiopathic origins. Pericardiocentesis is also indicated whenever tuberculous or purulent aetiology is suspected, or for large or symptomatic effusions refractory to medical treatment.^{29,30}

Additional examinations (TOE, CT, and CMR) can be proposed when TTE is non-diagnostic (obstructive lung disease, obesity, early after cardiac surgery). It is also reasonable to move to CT or, in stable patients, CMR when there is a traumatic aetiology, particularly when associated lesions in adjacent structures are suspected (penetrating injury, gastric, or oesophageal perforation). Both CT or CMR are indicated when pericarditis is associated with neoplastic diseases (lung or breast tumours), for the evaluation of the extension and staging of the disease and also post-MI when doubts persist regarding the possibility of haemopericardium secondary to contained myocardial free-wall rupture. In patients with recurrent pericarditis, CMR may help monitoring the presence and severity of active inflammatory changes, guiding the clinician in respect to the continuance of anti-inflammatory therapy.³¹

Pericardial fluid can reliably be detected by CT and is often an incidental finding.³² Small amounts of fluid in the pericardial space and

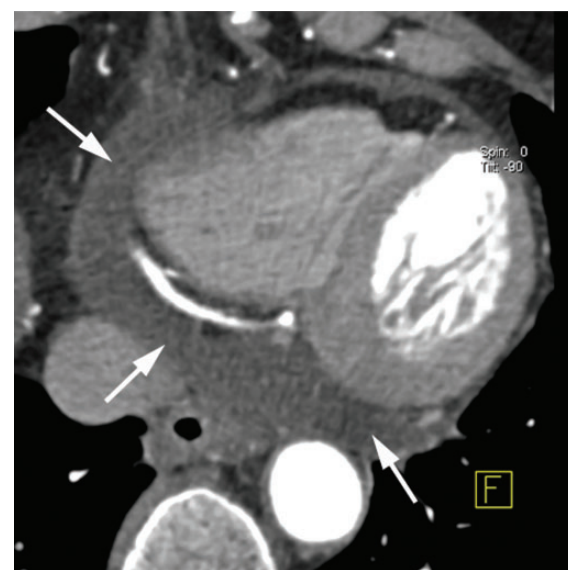

Figure 4: Normal accumulation of pericardial fluid around the inferior margin of the heart (arrows).

pericardial recesses, especially in the posterior and inferior margin of the heart, as well as around the left atrial appendage, can frequently be observed in healthy individuals.¹⁶ In cases of pericardial effusion, CT can clearly delineate the anatomic distribution of pericardial fluid (Figures 4 and 5). CT attenuation numbers measured in the pericardial

fluid may give some hints regarding the type and genesis of the effusion. Densities higher than water (above ~ 10 HU) suggest a high protein content. The density of haemorrhagic effusions is typically >30 HU. However, in cases of older haemorrhagic effusions, the density decreases over time.¹⁶ For the identification of acute haemorrhagic when compared with non-haemorrhagic effusions, a CT attenuation value >30 HU provided a sensitivity of 100% and specificity of 70%.³³

By CMR, pericardial effusions are clearly demonstrated with cine and black blood images. CMR provides more detailed visualization of pericardial effusion than transthoracic echocardiography,

especially of loculated or regional effusions and can guide pericardiocentesis (Figure 6). Through wider coverage of the thorax, CMR may identify the cause of a pericardial effusion and related pathology such as tumour or aortic disease. Signal characteristics with different CMR techniques may help differentiate between transudates and exudates: transudates typically have low signal on T1-weighted CMR images and high signal on gradient-echo cine-images, while protein-rich exudates show high signal on T1-weighted CMR. Signal characteristics of haemorrhagic effusions depend on the duration of the pathology. In acute pericarditis and myo-pericarditis, high signal in the pericardial layers on late gadolinium enhanced CMR images suggest acute

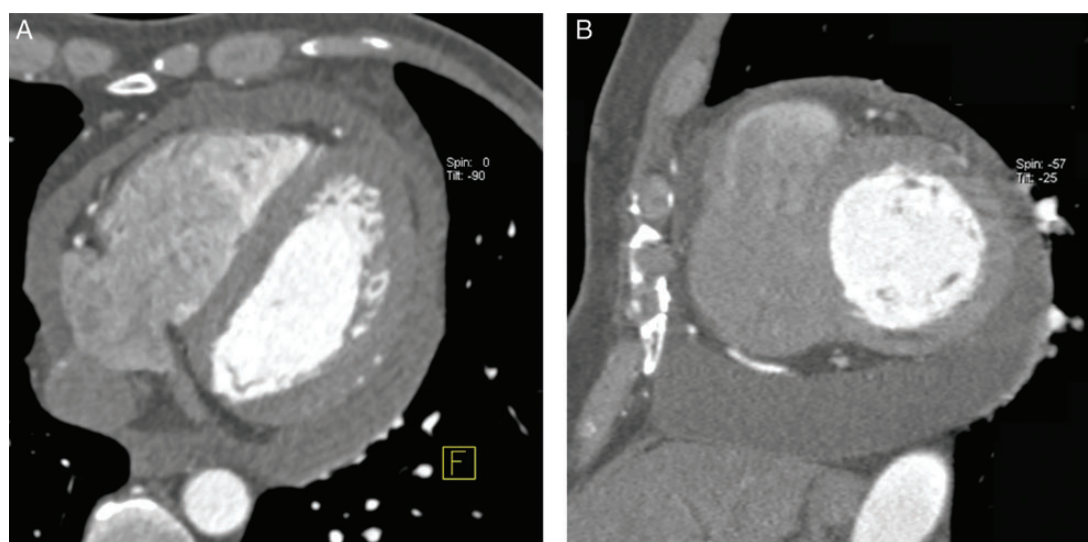


Figure 5: Circular pericardial effusion in transaxial orientation (A) and a 'short-axis' multiplanar reformatted image (B).

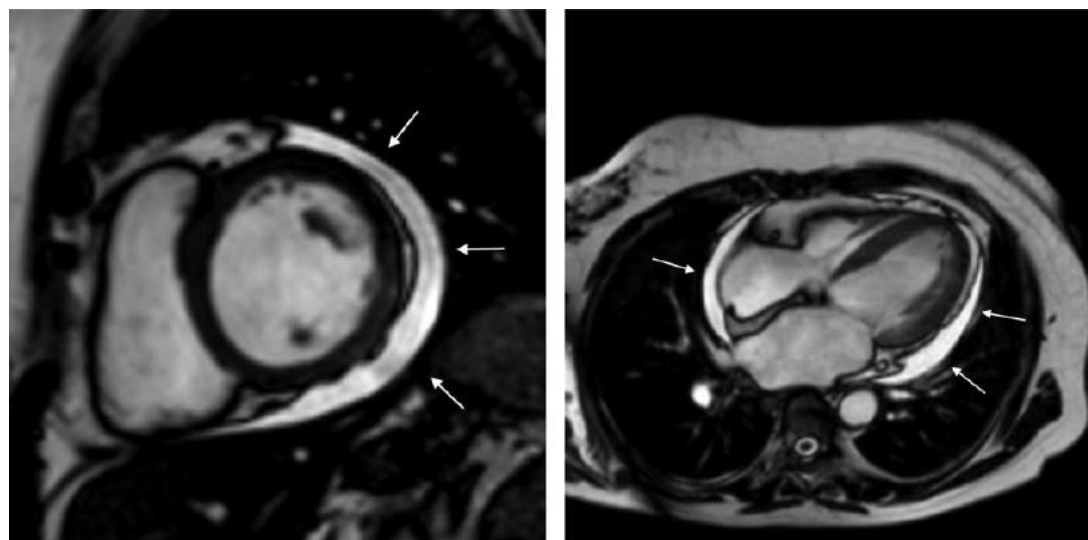


Figure 6: Loculated pericardial effusion (arrows) demonstrated with cine CMR images in orthogonal planes.

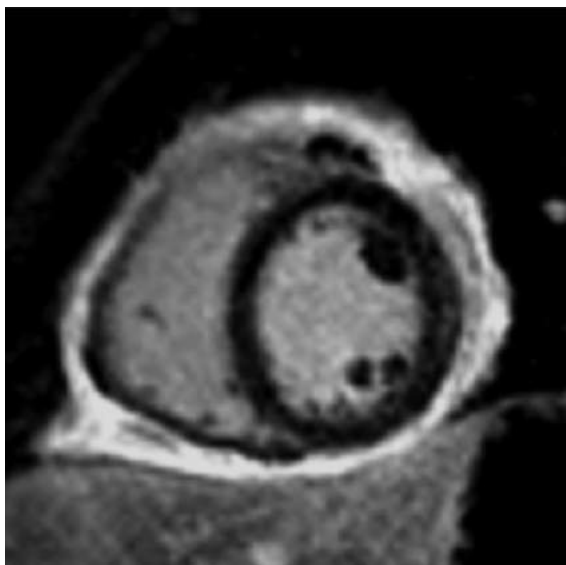


Figure 7: Acute pericardial inflammation demonstrated with late gadolinium enhanced CMR.

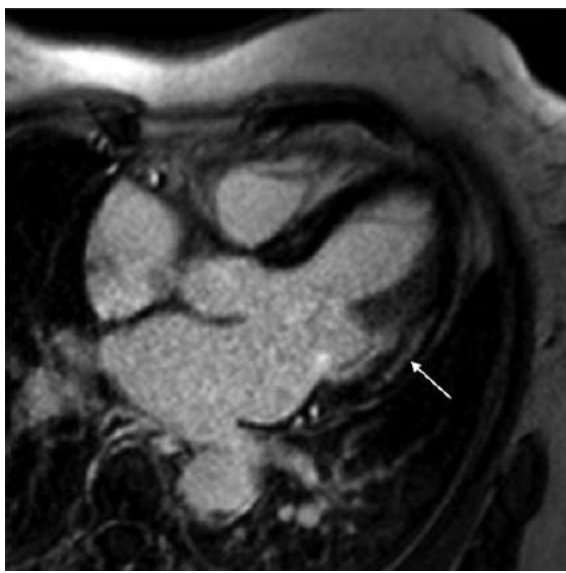


Figure 8: Mid-myocardial enhancement on late gadolinium enhanced CMR (arrow) in acute myocarditis.

inflammation (Figure 7).³⁴ Features of associated myocarditis are mid or epicardial areas of high signal on T2-weighted images (myocardial oedema), T1-weighted early gadolinium enhancement images (hyperaemia or capillary leak) and LGE images (oedema and/or fibrosis) together with regional wall motion abnormalities on cine CMR^{35,36} (Figure 8). CT and CMR are especially useful for the study of loculated effusions.

Recommendations

Acute pericarditis with complicated course and/or moderate-to-severe effusion and no tamponade	Class
TTE to confirm clinical diagnosis	Recommended
TOE if poor TTE quality of imaging	Recommended
TTE to indicate, contraindicate pericardiocentesis	Recommended
TTE to guide and for follow-up of pericardiocentesis	Recommended
CT/CMR to confirm clinical diagnosis in case of high suspicion of aortic dissection	Reasonable
CT/CMR to confirm the clinical diagnosis in case of trauma or associated disorders	Reasonable
CT/MRI to confirm clinical diagnosis if echocardiography inconclusive	Reasonable
CMR to confirm clinical diagnosis in case of myocarditis	Recommended
CMR for follow-up of pericardiocentesis	Reasonable
TTE for follow-up	Reasonable

Specific clinical conditions

In particular clinical conditions, the recommendations have to be adapted. Pericarditis is not infrequent in patients with severe renal failure and usually resolves with free-heparin daily haemodialysis. In these patients, the use of CT with contrast is not recommended due to nephrotoxicity of these products. Similarly, gadolinium-based contrast agents in CMR should be used with caution or avoided in patients with advanced renal failure (glomerular filtration rate <30 mL/min/1.73 m²) because of the risk of nephrogenic systemic fibrosis.³⁷

Pericardial effusion is a common complication of MI and may be attributed to epicardial irritation in transmural infarction, increased in venous and capillary pressure in heart failure, or subacute LV wall rupture. Pericardial effusion is generally small.

Cardiac tamponade occurs in 1% of patients with fibrinolytic-treated acute MI and is associated with increased 30-day mortality. Time from symptom onset to treatment strongly predicts the development of tamponade, underscoring the need for continued efforts to increase speed to revascularization in acute MI. Increasing age, anterior MI location, female sex, and increased time from symptom onset to treatment are significant independent predictors of tamponade. In post-infarction patients, the use of contrast echocardiography can help to diagnose pseudo-aneurysm or free wall rupture. Meta-analysis has even shown a beneficial effect in terms of prognosis in this setting.⁴ In this population, CMR allows the assessment of the extent and staging of the disease. If doubts persist, CMR's ability to detect the presence of haemopericardium may support indirectly the diagnosis of contained myocardial free-wall rupture. Irradiation is of particular concern in pregnant women presenting with pericardial disease, or in foetuses with pericardial disease.³⁸ For this reason, CT is contraindicated during pregnancy. Although CMR can be used safely in this condition, it is not routinely recommended, and echocardiography remains the examination recommended.

Recommendations

Imaging pericardium in specific conditions

A. Renal failure		Class
TTE to confirm clinical diagnosis		Recommended
TOE if poor TT quality of imaging		Recommended
TTE for diagnosis, guiding and follow-up of pericardiocentesis		Recommended
CT/CMR to confirm clinical diagnosis if echocardiography inconclusive (except non-contrast CT or CMR)		Not recommended
B. Post-infarction		
TTE to confirm clinical diagnosis		Recommended
Contrast echocardiography (aneurysm, free wall rupture)		Reasonable
TOE if poor TT quality of imaging		Reasonable
CT/CMR to confirm clinical diagnosis if echocardiography inconclusive (e.g. haemopericardium)		Reasonable
C. Pregnancy		
TTE to confirm clinical diagnosis		Recommended
CT/CMR to confirm clinical diagnosis if echocardiography inconclusive		Not recommended
TTE for guiding and follow-up of pericardiocentesis		Recommended
D. Foetal		
TTE to confirm clinical diagnosis		Recommended
CT/CMR to confirm clinical diagnosis if echocardiography inconclusive		Not recommended

Cardiac tamponade

Cardiac tamponade is a condition involving compression of the heart caused by blood or fluid accumulation in the pericardial sac and occurs when the pressure in the pericardial space exceeds the pressure in one or more cardiac chambers causing decreased cardiac output. Occurrence of tamponade can be acute, subacute, regional (or characterized by low pressure). Blood or fluid collects within the pericardium and this prevents the ventricles from expanding fully in diastole so they cannot adequately fill, and thus, pump enough blood to meet metabolic requirements. Acute tamponade is sudden and life threatening if not treated promptly. It is an emergency clinical condition often associated with hypotension, as well as chest pain and dyspnoea, and should be suspected in patients in cardiogenic shock, especially if they have increased jugular venous pressure or pulseless electrical activity. Cardiac tamponade always requires hospitalization. It occurs when the pericardial space fills up with fluid faster than the pericardial sac can stretch. If the amount of fluid increases slowly (such as in hypothyroidism) the pericardial sac can expand to contain up to 1–2 L before the occurrence of cardiac tamponade. If the fluid occurs rapidly as it may occur after trauma, cardiac surgery or myocardial rupture, as little as 200–300 mL can cause cardiac tamponade.

The presence of pericardial effusion in tamponade can readily be identified with echocardiography.³⁹ Typically, the heart is of normal size. Both the atria and the ventricles are small (underfilled) with good systolic function (compensatory hyperkinesis). Pericardial effusion is often symmetrical, both anteriorly and posteriorly from

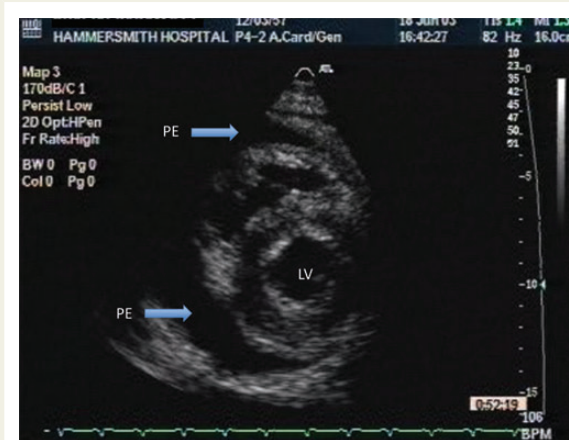


Figure 9: Parasternal short-axis view from a patient with moderate concentric pericardial effusion (arrows). LV, left ventricle; PE, pericardial effusion.

parasternal long- or short-axis projections, but also posteriorly, behind the posterior wall (Figure 9). In ambulatory patients, the pericardial effusion will be more important near the LV posterior wall, due to the effects of gravity. In bed-bound patients, either following surgery or any cardiac interventions, the effusion may be predominantly anterior. Unless the effusion is very large, the rate of fluid accumulation determines the development of tamponade, rather than its size. It is possible to have tamponade with only a small pericardial effusion of 10 mm, if the fluid is rapidly developing. Conversely, no tamponade may be present even with a large pericardial effusion, if it has accumulated slowly.

It is generally easy to estimate the amount of pericardial effusion by measuring the size of effusion in centimetres, usually from parasternal projections, perpendicular to the ventricular walls in diastole

- (1) Minimal pericardial effusion, usually of no haemodynamic consequences, when seen only in systole;
- (2) <1 cm: will correspond to ~300 mL;
- (3) 1–2 cm: ~500 mL;
- (4) >2 cm: typically in excess of 700 mL.
- (5) 'Swinging heart': this is a large pericardial effusion when effectively the heart wobbles and is often associated with tamponade and electrical alternance on the ECG.

Apical and subcostal projections are also important in order to determine the extent of effusion if there is clinical evidence of tamponade, to identify the optimal location for pericardiocentesis.

In patients with tamponade, there may be a large respiratory variation in chamber dimensions. Figure 10 is an M-mode echocardiogram from a patient with cardiac tamponade. It shows an inspiratory increase of RV size with concomitant decrease in LV size. Conversely, during expiration the RV is reduced in size with concomitant increase in LV size. Note that there is only a small concentric pericardial effusion at ~1 cm. While normally the atria are constrained within the pericardium, in tamponade, there is typically an early diastolic collapse of the RA free wall better seen from apical four-chamber projections (Figure 11).

Ventricular interdependence: normally, the pericardium allows the normal left and right ventricular filling to occur without restriction. When there is pericardial tamponade, the right ventricle cannot expand in diastole when it fills, so the ventricular septum shifts to the left, and the left ventricle then becomes underfilled. This shifting of the ventricular septum can be elicited by respiratory manoeuvres. It is a reflection of ventricular interdependence and can be recognized in both pericardial tamponade and pericardial constriction. Doppler assessment provides unique information regarding the haemodynamics of pericardial tamponade.³⁹

In a normal individual, changes in intrathoracic (pleural) pressures are faithfully transmitted almost equally to the cardiac chambers, and pulmonary veins and capillaries. Thus, the effective filling gradient (EFG) of the LV (pressure difference between pulmonary capillaries

and left ventricle) changes only slightly through the respiratory cycle. In patients with tamponade; however, changes in intrathoracic pressure are transmitted well to the pulmonary veins and capillaries but are poorly transmitted to the left ventricle due to a distended pericardial sac. Therefore, the EFG of the LV is markedly reduced during inspiration compared with expiration, resulting in reduced LV filling and, therefore, reduced LV outflow and stroke volume.¹

As a result, the following Doppler features are observed during inspiration: in the left heart, there will be a reduction in EFG due to a reduction in pulmonary capillary pressure while LA and LV diastolic pressures are relatively maintained due to reduced transmission of intrathoracic pressure into the heart. Therefore, LV filling will be reduced. Consequently, the transmitral Doppler early diastolic (E)-wave and in turn LV outflow will be reduced. In the right heart, the opposite is observed; RV filling is increased with increased RV volume as the septum moves to the left (ventricular interdependence), increased tricuspid E-wave and increased RV outflow velocity (Figure 12).

In cases where haemodynamic assessment with echocardiography is atypical and the presence of cardiac tamponade is still uncertain, CMR provides a useful adjunct or confirmatory test to exclude localized or loculated tamponade, but has limited indication in urgent cases. The CMR criteria for a functionally important effusion are similar to echocardiography, but may be more readily identified if echocardiographic images are of substandard quality; diastolic compression of the RV free wall, early systolic collapse of the RA, distortion of the LV and RV morphology, and potentially displacement of the interventricular septum to the left side during early inspiration (ventricular interdependence, Figure 13), although this is more commonly seen in constrictive pericarditis.^{40,41}

Although, CT and CMR have no role in acute life-threatening cardiac tamponade, CT may help to determine the feasibility of percutaneous pericardiocentesis especially in loculated or complex effusions.⁴²

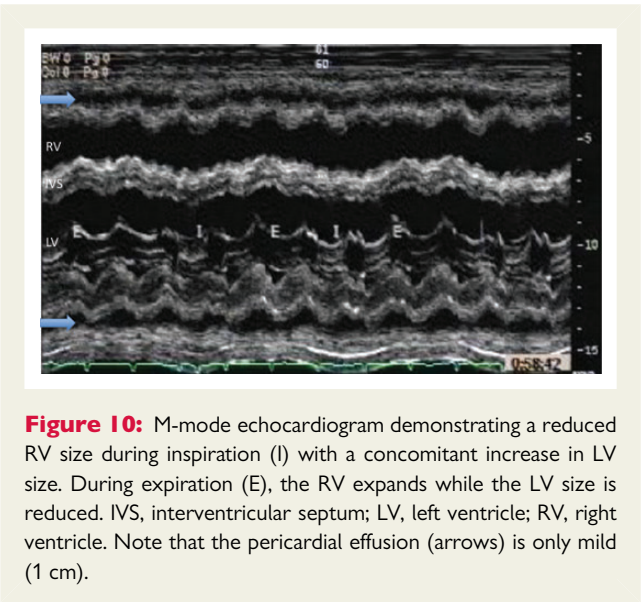


Figure 10: M-mode echocardiogram demonstrating a reduced RV size during inspiration (I) with a concomitant increase in LV size. During expiration (E), the RV expands while the LV size is reduced. IVS, interventricular septum; LV, left ventricle; RV, right ventricle. Note that the pericardial effusion (arrows) is only mild (1 cm).

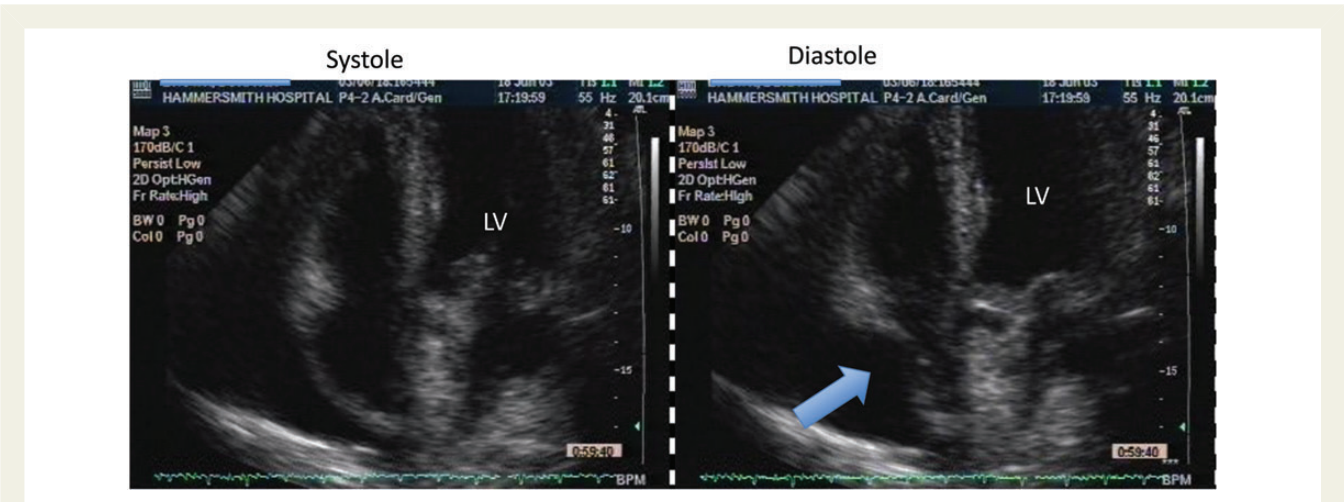


Figure 11: Apical projections from a patient with a moderate pericardial effusion (left) with diastolic RA collapse (right) suggestive of pericardial tamponade (arrow). LV, left ventricle. RA, right atrium.

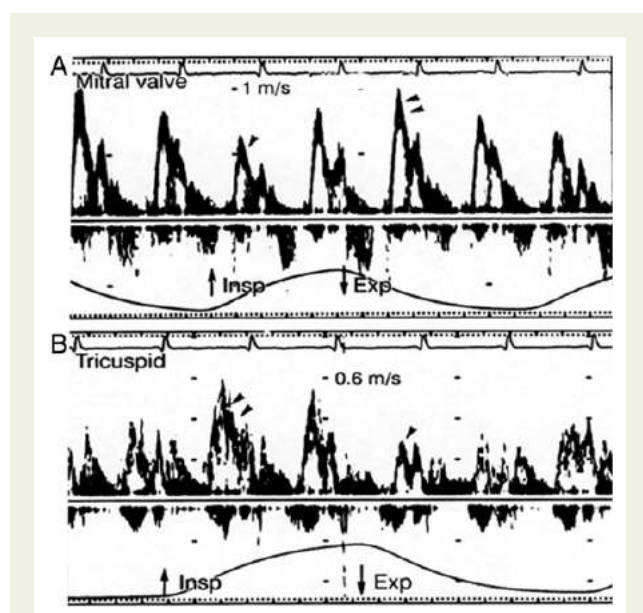


Figure 12: (A) On the left side, during inspiration, the mitral inflow is reduced almost immediately and increased during expiration (arrowheads) (B) On the right side, there is an increase of tricuspid E-wave and a reduction during expiration (arrowheads).

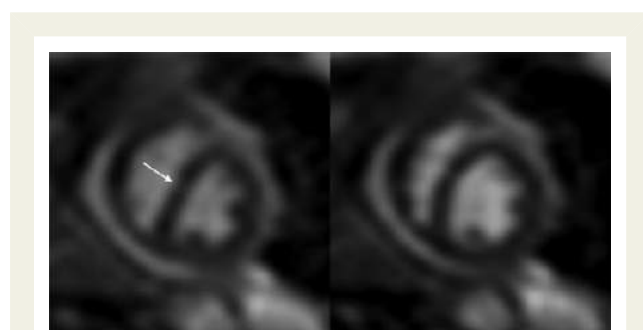


Figure 13: Interventricular dependence in constrictive pericarditis on real-time cine CMR. The interventricular septum bulges towards the left ventricle on early inspiration (arrow).

Pericardiocentesis

Patients with tamponade

In patients with tamponade, pericardiocentesis may be life-saving and should be performed quickly when the diagnosis of tamponade has been made. The biggest advantage of echocardiography is that it is a non-invasive bedside investigation and therefore, uniquely placed for both the diagnosis and guidance of drainage of the effusion. Other imaging modalities such as CMR may provide similar information to echocardiography about the presence of effusion, but only limited information about haemodynamics, which effectively constitute the diagnosis of tamponade. In addition, they may delay a potentially life-saving pericardial drainage and therefore, are not recommended as first-line imaging modality in this setting.

Drainage of an acute or chronic effusion producing cardiac tamponade may be performed with percutaneous pericardiocentesis

or subxiphoid pericardiocentesis. Percutaneous pericardiocentesis has been described in detail by several authors^{43–47} who proposed improvement of the technique from the blind procedure through echo-guided and contrast echo-guided pericardiocentesis. The previously used subcostal blind puncture of the pericardium has been abandoned because of the significant incidence of complications and mortality.⁴⁸ Numerous investigators have recognized the usefulness and safety of 2D echocardiography-guided pericardiocentesis to reduce the risk of cardiac puncture. The addition of contrast echocardiography can further improve the safety of the procedure by reducing the likelihood of heart puncture. During the procedure, the ideal entry point (minimal distance from skin to pericardial fluid without intervening structures) can be defined by echocardiography. The subxiphoid approach has been used most commonly, with a long needle with a mandrel (Tuohy or thin walled 18-gauged) directly to the left shoulder at a 30° angle to the skin. This route is extrapleural and avoids the coronary, pericardial, and internal mammary artery. The operator, under echo assistance, attempts to aspirate fluid and inject immediately after 6 mL of agitated saline thus confirming that the needle is entered into the pericardial sac (microbubbles should clearly create contrast into pericardial fluid) (Figure 14). After the correct introduction of the needle, a guidewire and a catheter (generally multi-holed pig-tail) may be advanced into the pericardial sac and drainage may be performed. The Tuohy needle from the subxiphoid approach thanks to its curved tip greatly facilitates guidance of the wire and catheter to the posterior pericardial space so that the standard Seldinger technique may be successful not only in massive and diffused effusions, but also in loculated posterior ones.⁴⁷

Another alternative approach (vs. subxiphoid pericardiocentesis) has been proposed either in acute medical or post-cardiac surgical tamponade or for cardiac perforation complicating catheter-based procedures.⁴⁹ Two-dimensional echocardiography allows the examiner to locate the largest collection of pericardial fluid in closest proximity to the transducer. Accordingly the apical or anterior route may be decided. The role of echo and contrast saline is the same as in the previous described subxiphoid procedure.

Both in subxiphoid and apical approaches, echo-guided pericardiocentesis may be further improved in terms of safety and monitoring by fluoroscopic guidance.

Using an intrapericardial catheter for extended drainage (vs. pericardiocentesis without pericardial catheter) is safe and may be effective in order to decrease recurrences; this has been demonstrated in retrospective series (the majority with malignancies).^{50,51} Thus, a complete and prolonged evacuation of the fluid may probably enhance apposition of the visceral and parietal pericardium.

Surgical drainage of a pericardial effusion is usually performed through a limited subxiphoid incision.^{52–55} Generally, the more invasive technique (subxiphoid surgical pericardiectomy) may be selected in cases in which percutaneous pericardiocentesis is unsuccessful or when echocardiographic examination discourages a percutaneous approach.

Complications of pericardiocentesis are rare when echo and fluoroscopic guidance are used correctly. Echocardiographic monitoring throughout the procedure is very useful. Immediately after the drainage signs of clinical tamponade (heart rate, arterial pressure) should be monitored, as well as echo findings such as, changes in cardiac chamber compression and mitral and aortic flow. Generally,

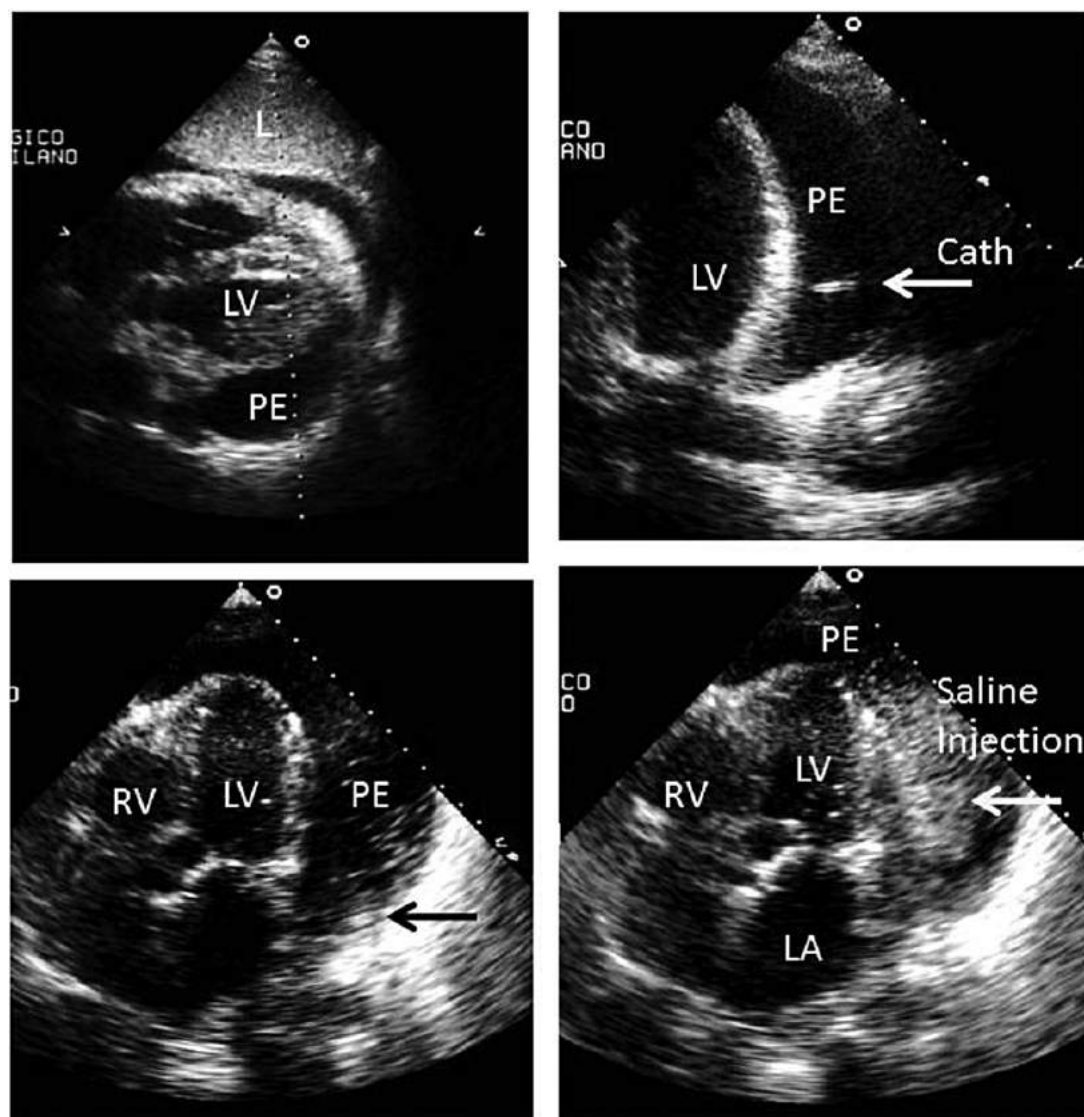


Figure 14: Echocardiography without and with contrast injection before pericardiocentesis. RV, right ventricle; LV, left ventricle; LA, left atrium; PE, pericardial effusion; Cath, drainage catheter; L, leaver.

signs of compression (both right atrial and ventricular collapse) and inspiratory variation of left-side valve flow disappear immediately after the initial drainage of the pericardial sac (even with a few millilitre of pericardial drainage). The complete or almost complete reduction of pericardial effusion may be continuously monitored by echo using an ideal view (generally the four-chamber view during the subxiphoid pericardiocentesis).

Depending on the clinical presentation and clinical findings, after pericardial drainage, an individualized echo follow-up may be scheduled in each patient. Generally, inside the hospital, a daily check may be performed to evaluate pericardial effusion recurrence. After patient discharge, a weekly echocardiographic evaluation may be useful to facilitate the clinician in choosing the correct medical strategy. There are no rules to check changes in the quantity of pericardial effusion (small, moderate, and severe), but digital storage of a

complete examination may certainly facilitate comparisons among several echocardiograms.

Generally, echocardiography remains the method of choice for the follow-up of pericardial diseases in the majority of cases. However, in many clinical scenarios, echocardiography alone may be insufficient. This is certainly true in the diagnostic process, but may be also considered in the follow-up of complex cases even though these considerations are largely based on individualized approaches. Given that it does not expose patients to ionizing radiation and that it provides freely definable imaging planes, CMR is an ideal test for the longitudinal follow-up of patients with pericardial disease.

Patients without tamponade

Pericardial drainage in the absence of cardiac tamponade or signs of haemodynamic impairment is still controversial. However, nearly

one-third of patients with large idiopathic pericardial effusions develop cardiac tamponade unexpectedly.⁵⁶ Routine pericardial drainage procedures have a very low diagnostic yield in patients with large pericardial effusion without tamponade or suspected purulent pericarditis and no clear benefit is obtained with this approach.⁵⁷ In general, outcomes depend on the underlying diseases and are not influenced by drainage of pericardial fluid.⁵⁸ However, in many advanced malignancies, pericardial drainage may be associated with instillation into the pericardial sac of different agents with sclerosing or cytostatic activity, like tetracyclines, belomycin, thiopeta, or radionuclides.^{59–61}

Imaging in specific conditions potentially requiring pericardiocentesis

Pericardial effusion after invasive procedures. The incidence of cardiac perforation and pericardial tamponade is increasing in the era of new coronary interventional devices. Tamponade after percutaneous coronary intervention is not rare (overall incidence 0.2%); it can have a delayed off-set and thus, occur outside the catheterization suite.⁶² The same is true for electrophysiological procedures. Therefore, echocardiographically guided rescue pericardiocentesis for cardiac tamponade after catheter-based procedures has been extensively studied. This method appears safe and effective for reversing haemodynamic instability.⁴⁹ The importance of an immediate drainage in different cardiac catheter-based procedures is further underlined in recent years due to several new 'complex' procedures including left atrial appendage closure, mitral clip, transfemoral aortic valve implantation, and others.

Haemopericardium is not rare after cardiac catheter-based procedures and echo-guided pericardiocentesis is much more important in this situation since the operator may immediately exclude heart puncture. In a patient population that is reasonably representative of that in most community hospitals in the USA,⁶³ the most common cause of bloody pericardial effusion in patients with signs or symptoms of cardiac tamponade is now iatrogenic disease. Of the noniatrogenic causes, malignancy, complications of acute MI, and idiopathic disease predominated. Fluoroscopy-guided pericardiocentesis has also been demonstrated as a safe and effective management strategy for cardiac tamponade developed in the cardiac catheterization laboratory. A reduction in the excursion of cardiac silhouette on fluoroscopy is an early diagnostic sign of cardiac tamponade.⁶⁴

Pericardial effusion and cardiac tamponade after cardiac surgery.

Pericardial effusion is not a rare complication of cardiac surgery.^{65,66} Haemodynamic instability due to pericardial effusion occurs in 1.5% of patients, and symptoms are frequently non-specific. Virtually, all pericardial effusions are generally found by the fifth post-operative day; they peak on the 10th day and resolve within 1 month. However, late cardiac tamponade has also been described⁶⁷ and haemodynamic impairment has several differences in comparison with 'medical' effusion. In fact loculated effusions are very frequent (up to 58%) and 6% of cases may have isolated effusion along the right atrial wall. Pericardial clots particularly at the level of the right chambers may produce low-cardiac output soon after open-heart surgery, with haemodynamic signs that are very similar to constrictive pericarditis. Transoesophageal echocardiography may be indicated in these cases to image adequately the right atrium, the junction between the superior vena cava and the atrium and the pericardial clot.⁶⁸ Alternatively, CT or CMR may be used. In all these cases echocardiography is very useful in

choosing the more correct approach to relieve cardiac tamponade (percutaneous pericardiocentesis, subxiphoid surgical drainage, or even pericardial inspection after sternotomy in cases in whom bleeding is suspected). Figure 15 shows an example in which pericardiocentesis was not appropriate (loculated haematoma compressing the right atrium and LA), and urgent cardiac surgery was performed to relieve cardiac compression.

Recommendations

Cardiac tamponade and pericardiocentesis	Class
TTE to confirm clinical diagnosis	Recommended
TOE if poor TTE quality of imaging	Recommended
TTE to indicate, contraindicate pericardiocentesis	Recommended
TTE to guide and for follow-up of pericardiocentesis	Recommended
CT/CMR to confirm clinical diagnosis in case of high suspicion of aortic dissection	Reasonable
CT/CMR to confirm the clinical diagnosis in case of trauma	Reasonable
CT/CMR to confirm clinical diagnosis if echocardiography inconclusive	Not recommended
CMR for follow-up of pericardiocentesis	Reasonable

Constriction

Chronic constriction

Constrictive pericarditis is a condition caused by a thick non-compliant inflamed, fibrotic, and/or calcified pericardium, which inhibits cardiac filling by preventing full transmission of respiratory intrathoracic pressure changes to cardiac cavities. Constrictive pericarditis is mainly related to cardiac surgery, pericarditis, and mediastinal radiation therapy in the developed countries.^{69,70} Immunosuppression and tuberculosis are other causes of constriction, in both developed and underdeveloped countries.⁷¹ In chronic constriction, there is no pericardial effusion. Perhaps the sign that is most obvious and should alert the echocardiographer towards the diagnosis of constriction is the abnormal ventricular septal motion to the left in early diastole, in inspiration, as in pericardial tamponade due to the ventricular interdependence (septal bounce). This is exaggerated during inspiration where the RV fills ahead of the LV and pushes the septum to the left. As in pericardial tamponade, the now thickened pericardium prevents full transmission of respiratory changes of intrapleural pressures to the intracardiac cavities, creating a marked respiratory variation in the left-side pressure difference between the pulmonary vein and the LA, which is reduced during inspiration (reduced EFG). Therefore, the mitral inflow and pulmonary venous diastolic flow velocities decrease immediately after the onset of inspiration and increase with expiration ($\geq 25\%$ expiratory increase in transmitral E-wave velocity). Changes in the right side are the opposite and reciprocal with inspiratory increase of tricuspid inflow ($\geq 40\%$ inspiratory increase in transtricuspid E-wave velocity) and outflow.⁷²

Other echocardiographic findings include a normal ventricular systolic function and thickened pericardium. Although pericardial thickening is not specific, it may be better visualized using TOE. With TTE, this is better seen either from parasternal long-axis projections at the

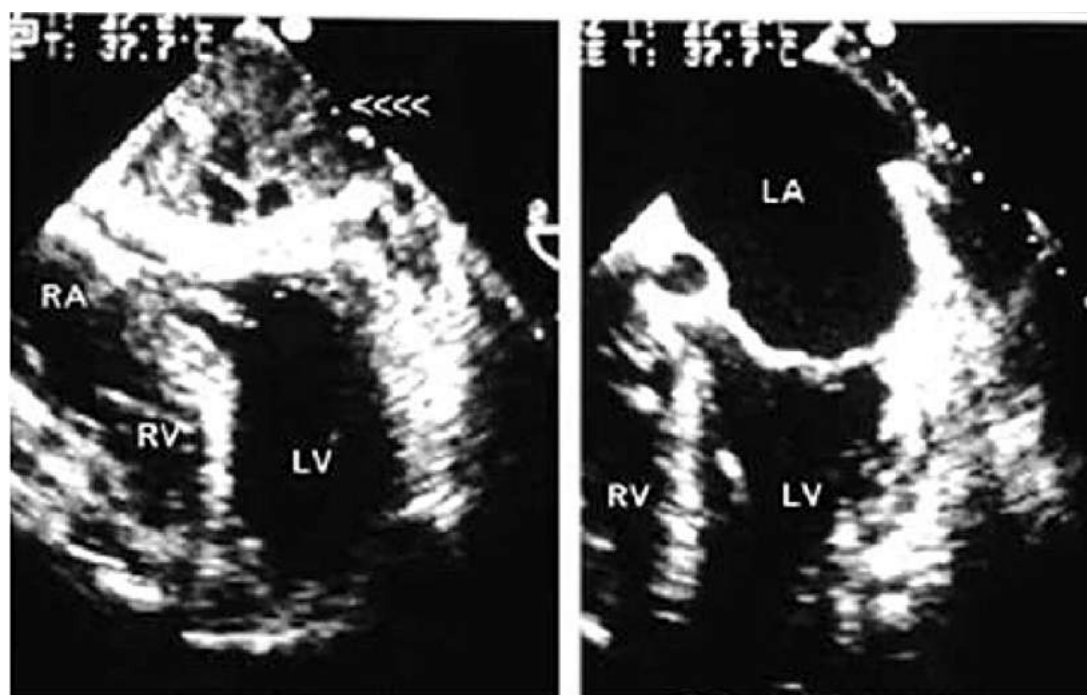


Figure 15: Transoesophageal transversal view of pericardial post-operative clots before and after surgical removal.

back of the heart or better from parasternal short-axis projections with the overall gain right down in order to enhance the echoes arising from the posterior pericardium. When this is done, then the pericardial layers may be seen as two bright lines moving in parallel throughout the cardiac cycle. When this is visualized, it is very specific and together with the septal bounce; it will contribute to a positive diagnosis of pericardial constriction. In addition, the inferior vena cava is dilated with little respiratory variation indicative of elevated right atrial pressures.

Mitral inflow velocities may not show respiratory variation in up to 50% patients with constrictive pericarditis as the filling pressures may be altered due to marked diuresis, which will tend to reduce intrathoracic and intracardiac pressures. Therefore, the absence of respiratory variation of mitral inflow in patients with clinical evidence of significant systemic venous congestion does not exclude the diagnosis of constrictive pericarditis.⁷²

The respiratory variation of Doppler velocities can also be seen in other conditions such as chronic obstructive lung disease, right ventricular infarct, sleep apnoea, asthma, and pulmonary embolism due to increased intrapleural (intrathoracic) pressure drop with inspiration not all transmitted to heart.

Systolic function is preserved in pericardial constriction and this can also be demonstrated by the high mitral annular systolic velocities, but also by the high systolic myocardial velocities, strain and strain rate.⁷³

Cardiac catheterization allows simultaneous right ventricular and LV pressure recordings, demonstrating equalization of pressures at end-diastole, which gives the typical 'square root' or 'dip and plateau' sign (Figure 16). Although not specific to constriction, this may add to the diagnosis in concert with other clinical and echocardiographic findings.

Thickened pericardium by CT can be found in a multitude of situations, including the early post-operative period, uraemia, rheumatic heart disease, sarcoidosis, or as a consequence of radiation therapy (Figure 17). Increased thickness of the pericardium *per se* does not constitute proof of constriction.¹⁵ About 20% of cases may display constrictive features without pericardial thickening.⁷² Also, CT cannot assess the haemodynamic relevance of a thickened pericardium. Hence the appearance of 'pericardial thickening' on CT can be supportive in cases of suspected constriction, but it does not prove the condition. Similarly, a normal pericardial thickness cannot rule out constriction.⁷⁴ CT imaging can clearly delineate the presence and the exact extent of pericardial calcification (Figure 18). In the clinical setting of suspected constriction, pericardial calcification should be considered a significant finding.²⁰ However, again, calcification alone does not allow making a diagnosis of 'pericardial constriction'. CMR can demonstrate the thickening and, although less reliably than CT, calcification of the pericardium that are usually associated with constrictive pericardial disease (Figure 19). Comparable with echocardiography, dilated RA, and an elongated RV can be detected and real-time cine CMR demonstrates ventricular interdependence.⁴¹ Pericardial adhesions between the thickened pericardium and the epicardial surface of the myocardium with reduced mobility of the myocardium may be highlighted by tagged cine CMR imaging.^{75,76} CMR findings are used to plan invasive treatment, such as pericardiectomy, complementing findings on echocardiography and/or CT. CMR is frequently used to plan the management of pericardial masses, in particular surgical interventions. Cardiac mortality and morbidity at pericardiectomy is mainly caused by the pre-surgically unrecognized presence of myocardial atrophy or myocardial fibrosis. Using CMR for excluding patients with extensive

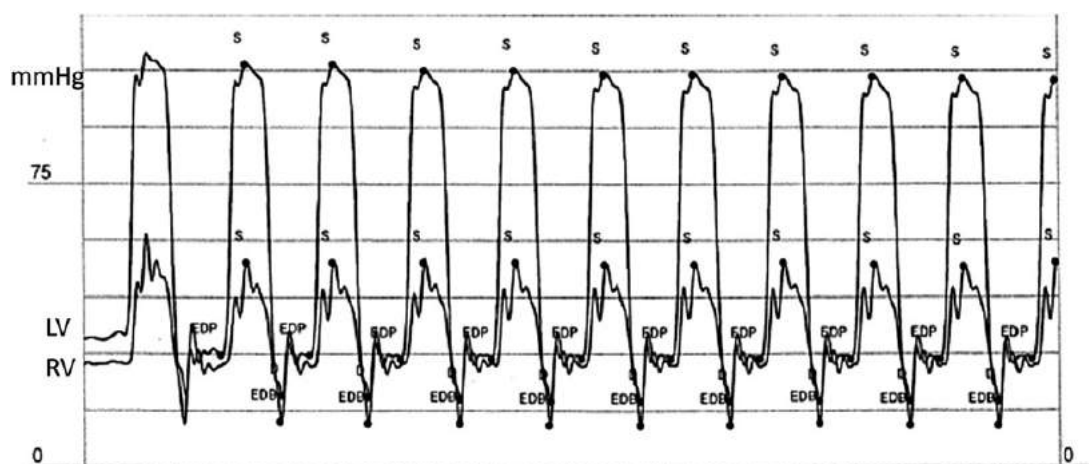


Figure 16: Simultaneous right ventricular and left ventricular pressure recordings, demonstrating equalization of pressures at end-diastole (EDP) which gives the typical 'square root'.

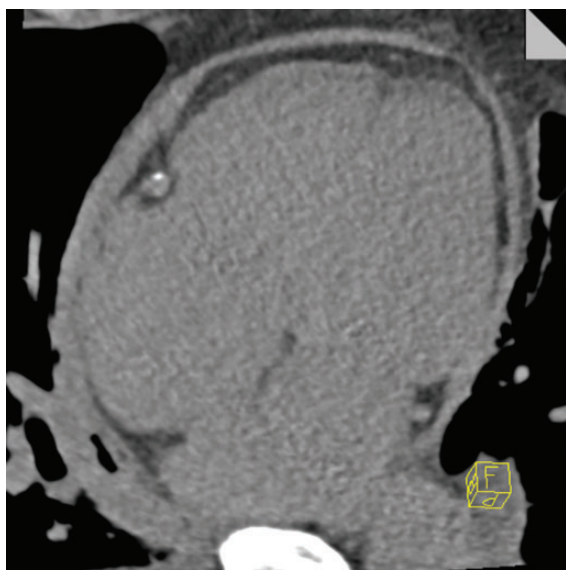


Figure 17: Thickened pericardium—without calcification—in a non-contrast CT acquisition of a patient with constrictive pericarditis.

myocardial fibrosis and/or atrophy significantly reduces the mortality rate for pericardiectomy.⁷⁷ Moreover, CMR pericardial LGE and inflammatory biomarkers could predict the reversibility of CP after anti-inflammatory therapy.

Constriction vs. restriction

In most clinical scenarios, the distinction between constriction and restriction will be guided by the patient's history. (i.e. of surgery or infection—tuberculosis). However, in some patients presenting with elevated filling pressures (diastolic heart failure) and/or pulmonary hypertension the differential diagnosis between pericardial

constriction and restrictive cardiomyopathy can be more challenging. In the majority of patients with suspected restrictive cardiomyopathy, the cause of their pathology is cardiac amyloidosis, which has specific echocardiographic signs, including reduced contractility, so that in reality the differential diagnosis from constrictive pericarditis is rarely an issue. Other forms of restrictive cardiomyopathies, however, may be more important for the differential diagnosis with constriction, including post-radiotherapy, sarcoidosis, haemochromatosis, endomyocardial fibroelastosis, and primary restrictive cardiomyopathy.

In constrictive pericarditis, the most striking findings are ventricular septal motion abnormalities, which do not occur in restriction.

Restrictive cardiomyopathy is characterized by the restrictive Doppler physiology with increased E velocity, decreased A velocity, E/A ratio greater than 2, and shortened deceleration time of E-wave. Hepatic vein diastolic flow reversals occur with inspiration instead of expiration.

Tissue Doppler recording of mitral annulus has become an important means to differentiate myocardial restrictive from pericardial constrictive heart failure. Typically, mitral annular e' velocity is well preserved in constriction (often >7 cm/s) (unless mitral annulus calcification and/or LV dysfunction) but significantly diminished in restriction. Despite elevated LV filling pressures (restrictive transmitral flow pattern) E/e' remains low in constrictive pericarditis (annulus paradoxus). Mitral inflow propagation velocity (PFV) measured by colour M-mode is also helpful in distinguishing restriction (PFV <45 cm/s) from constriction (PFV >45 cm/s). However, it is more difficult to perform than TDI.⁷³

As shown by Leitman *et al.*,⁷⁸ LV rotation and torsion may be markedly reduced in patients with acute inflammatory pericardial disease. In these patients, there were also reductions in myocardial longitudinal and circumferential strains. This is probably due to a mixed pericardial and myocardial involvement in most patients with pericarditis.

The marked reduction in LV torsion in patients with perimyocarditis probably reflects reduction in myocardial function predominantly in the subepicardial layer which is composed of the spiral oblique myocardial fibres which account for the normal counter-

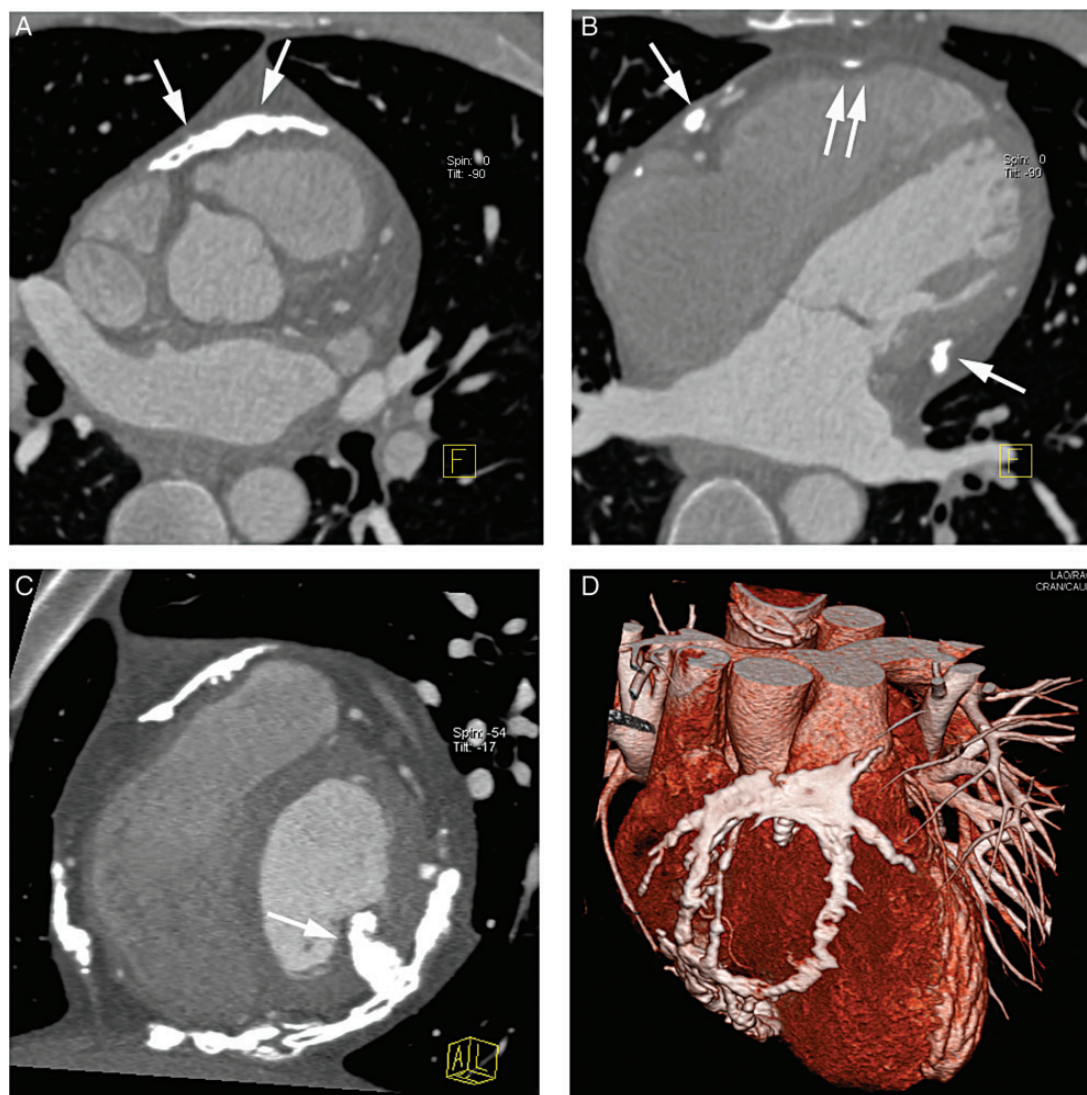


Figure 18: Pericardial calcification. In transaxial slices (A and B), the calcified pericardial sections can clearly be seen. Note the impression of the right ventricle (double arrows in B), indicating the haemodynamic effects of the calcification. (C) An of-axis reconstruction, similar to a 'short-axis' view of the heart. Note the infiltration of the myocardium by pericardial calcification (arrow in C). A three-dimensional surface-weighted reconstruction.

clockwise rotation of the LV apex and clockwise rotation of the base. In addition, pericardial adhesions may limit the free motion of the ventricle within the pericardium and thereby reduce LV twist.

The changes in LV torsion in constrictive pericarditis are in principle similar to the findings in perimyocarditis, i.e. a marked decrease in LV torsion, which is mainly due to a reduction in apical rotation.⁷⁹ Constrictive pericarditis is also associated with reductions in LV longitudinal, circumferential, and radial strains.⁸⁰ The reduction in subepicardial function in constrictive pericarditis may be attributed to myocardial atrophy and fibrosis as well as calcium deposition due to longstanding disease. In myocardial infiltration leading to restrictive physiology, abnormal LV contraction is usually seen alongside characteristic changes on LGE CMR, with diffuse signal enhancement.⁷⁸

Effusive-constrictive pericarditis and transient constrictive pericarditis

Both pericardial effusion and constrictive pericarditis may co-exist in effusive-constrictive pericarditis. There is a pericardial effusion and evidence of increased filling pressure with constriction.^{81,82} Owing to the decrease in intrapericardial pressure, pericardiocentesis can solve the constrictive physiology but sometimes constrictive haemodynamics can still persist even after the pericardial effusion is removed. Pericardiocentesis is the treatment of choice of effusive-constrictive pericarditis. In patients in whom constriction persists despite fluid removal, it may be due to reversible inflammation that may resolve with anti-inflammatory medications, this condition has been termed transient constrictive pericarditis.⁸³ Gadolinium

enhancement of the pericardium has the ability to predict reversibility of the constrictive physiology.³¹ If the medical treatment is unsuccessful after a few months of follow-up, a pericardiectomy has to be planned. In this particular condition, a close follow-up with echo or CMR to assess the decrease in typical signs and haemodynamics of constriction is mandatory. The effusion can be followed on anatomical and cine CMR images and inflammatory response to medications at the level of the pericardium can be followed using contrast CMR.

Recommendations

Constrictive pericarditis	
A. Chronic constrictive pericarditis	Class
TTE to confirm clinical diagnosis	Recommended
TOE if poor TT quality of imaging (thickness of pericardium)	Recommended
CT/CMR to confirm clinical diagnosis if echocardiography inconclusive	Reasonable
CT for planning a pericardiectomy (calcification, coronary arteries, lung damage, previous CT surgery, ...)	Reasonable
CMR for planning pericardiectomy (degree of myocardial fibrosis and atrophy, lung damage, ...)	Recommended
TTE for follow-up	Recommended
CMR for follow-up	Reasonable
B. Effusive-constrictive pericarditis	Class
TTE to confirm clinical diagnosis and for follow-up post-pericardiocentesis	Recommended
CT/CMR to confirm clinical diagnosis if echocardiography inconclusive	Reasonable
CMR with contrast to evaluate inflammation	Reasonable
CMR for follow-up	Reasonable

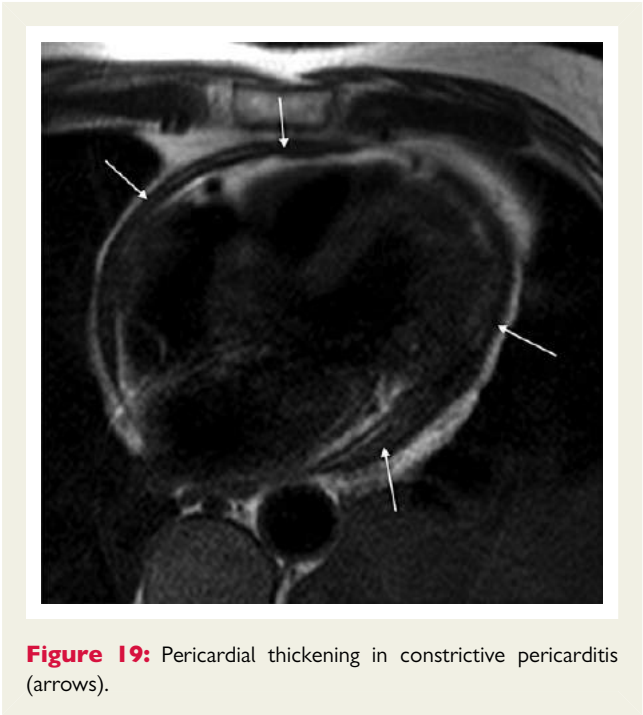


Figure 19: Pericardial thickening in constrictive pericarditis (arrows).

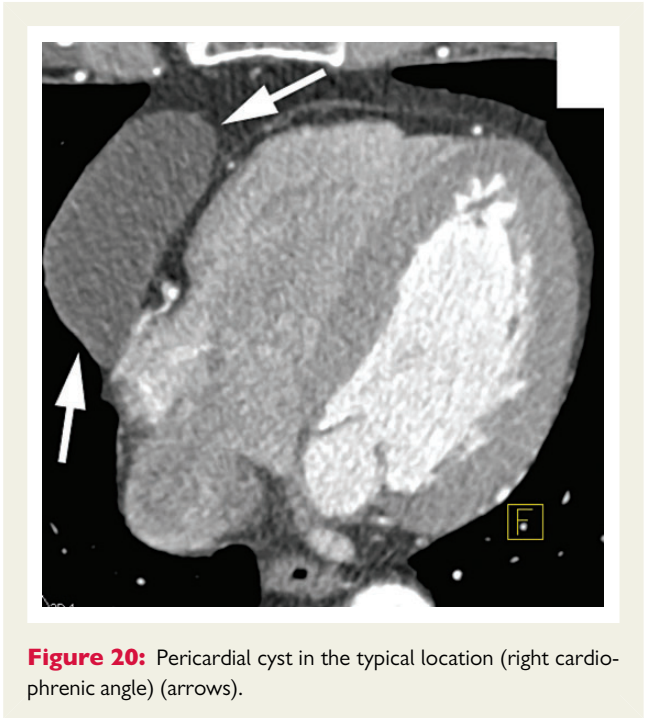


Figure 20: Pericardial cyst in the typical location (right cardiophrenic angle) (arrows).

Pericardial tumours, cysts, and diverticula

Most pericardial tumours are secondary lesions due to the local spread of lung and mediastinal tumours or due to metastatic lesions from lung and breast cancers, lymphomas, and melanoma. Primary malignant tumours are rare, 50% of them are mesothelioma. Other causes are sarcoma, haemangioma, and teratoma. A pericardial effusion is often associated. The most common cause of benign tumour of the pericardium is a lipoma. Gossypibomas (foreign-body granulomas) can also be seen following trauma or surgery. Although TTE may serve as a screening and follow-up tool, most neoplasms are best studied with CT or CMR for a better characterization of the lesion and evaluation of the adjacent structure of the tumour spread, and to assess the presence of calcification and lymphadenopathy.³ CMR does not provide a histological diagnosis, but it can provide by its excellent soft tissue differentiation and large field of view clues for diagnosis and tissue characterization and can allow delineation, extent, and origin of tumour. Most tumours will display contrast enhancement and delayed contrast wash-out.^{3,84}

Cysts are rare, benign, congenital, fluid-filled-loculated-free space adjacent to cardiac border most of the time at the right costophrenic angle. The size may vary from 2 to 28 cm² and their rupture may cause tamponade. In addition to echocardiography, CT and CMR are techniques of choice to identify the thin walls of these oval, homogeneous masses. Cysts have a density of 30–40 HU on CT (Figure 20), showing no enhancement with contrast.⁸⁵ With CMR, these structures show intermediate to low-intensity T1-signal and high T2-weighted signal intensity with no contrast enhancement. Diverticula are out-pouching of the pericardial sac and may be differentiated from cysts based on the presence of a communication with the pericardial space and the changes in size related to the body position.⁸⁶

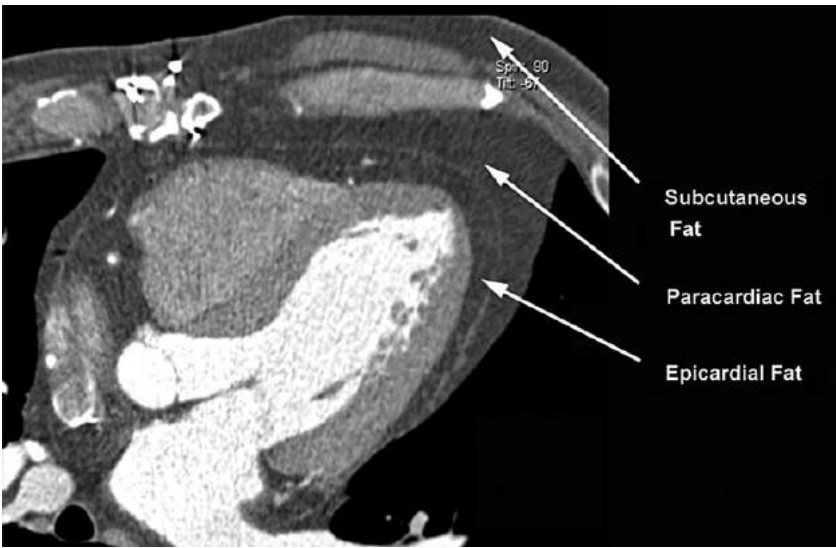


Figure 21: Epicardial fat (often referred to as ‘pericardial fat’), paracardiac fat, and subcutaneous fat in computed tomography. Epicardial fat is correlated with coronary atherosclerosis and the amount of epicardial fat is predictive for future cardiovascular events.

Congenital disease

Congenital absence of the pericardium is very rare, but can also arise after trauma. It is of a little clinical importance when complete but may be fatal when it is partial because of a potential herniation of a part of the heart. Most commonly, partial absence of the pericardium is left and is usually suspected when the posterior wall motion is exaggerated or when the right ventricle appears falsely enlarged due to the left shift. Extreme levorotation and displacement of the apex may be displaced in the axilla leading to a compressed appearance of the atria. Interposition of lung tissue between aorta and pulmonary artery or between the basis of the heart and the diaphragm is specific signs. The potential associated malformations (such as bicuspid valve, patent ductus arteriosus, atrial septal defect, and mitral stenosis) should be explored.

Recommendations

Masses and tumours of the pericardium	
TTE to confirm clinical diagnosis	Recommended
TOE if poor TT quality of imaging	Recommended
CT/CMR to confirm clinical diagnosis and for further evaluation of the mass and lymphadenopathy detection	Recommended
Pericardial cysts and diverticula	
TTE to confirm clinical diagnosis and follow-up	Recommended
Contrast echocardiography to exclude anomalous systemic vein	Reasonable
CT/CMR to confirm clinical diagnosis	Recommended
CT for follow-up	Not recommended
Congenital absence of the pericardium	
TTE to confirm clinical diagnosis and associated malformation detection	Recommended
CT/CMR to confirm clinical diagnosis and associated malformation detection	Reasonable

Pericardial fat

The adipose tissue within the pericardium sac is called ‘epicardial fat’ (frequently, it is incorrectly referred to as ‘pericardial fat’, Figure 21). An increasing evidence has been accumulated which demonstrates a relationship between epicardial fat volume and coronary atherosclerosis.⁸⁷ In the past decade, there has been growing interest in the relationship between epicardial fat and cardiovascular disease. Besides computed tomography, which does not require the injection of contrast agent for this purpose, echocardiography and CMR can also be used to quantify epicardial adipose tissue. With 2D-echocardiography, epicardial fat is identified as the echo-free space between the epicardial layers on 2D-images and its thickness is measured on the free wall of the right ventricle from both parasternal long-axis and short-axis views at end-diastole. The maximum value at any site is measured, and the average value is considered. However, computed tomography provides high-spatial resolution and true volume coverage of the heart and, therefore, constitutes the most straightforward approach to quantifying epicardial fat. The extent of epicardial fat and its differentiation from extra-cardiac tissue or myocardial infiltration is usually straight-forward with CMR. By combining T1-weighted images without and with fat saturation preparation, fat can be confidently identified. Especially in suspected infiltration of the RV free wall on echocardiography, CMR can be a useful second-line investigation.

At the current time, pericardial fat quantification is not included in recommended algorithms for risk stratification. However, the available data are intriguing enough to warrant further research.

Conflict of interest: none declared.

References

1. Ling LH, Oh JK, Breen JF, Schaff HV, Danielson GK, Mahoney DW et al. Calcific constrictive pericarditis: is it still with us? *Ann Intern Med* 2000;**132**:444–50.
2. Cosyns B, Garbi M, Separovic J, Pasquet A, Lancellotti P. Education Committee of the European Association of Cardiovascular Imaging A. Update of the echocardiography

- core syllabus of the European Association of Cardiovascular Imaging (EACVI). *Eur Heart J Cardiovasc Imaging* 2013;**14**:837–9.
3. Wang ZJ, Reddy GP, Gotway MB, Yeh BM, Hetts SW, Higgins CB. CT and MR imaging of pericardial disease. *Radiographics* 2003;**23 Spec No**:S167–80.
 4. Main ML, Ryan AC, Davis TE, Albano MP, Kusnetzky LL, Hibberd M. Acute mortality in hospitalized patients undergoing echocardiography with and without an ultrasound contrast agent (multicenter registry results in 4,300,966 consecutive patients). *Am J Cardiol* 2008;**102**:1742–6.
 5. Urheim S, Edvardsen T, Torp H, Angelsen B, Smiseth OA. Myocardial strain by Doppler echocardiography. Validation of a new method to quantify regional myocardial function. *Circulation* 2000;**102**:1158–64.
 6. Amundsen BH, Helle-Valle T, Edvardsen T, Torp H, Crosby J, Lyseggen E et al. Non-invasive myocardial strain measurement by speckle tracking echocardiography: validation against sonomicrometry and tagged magnetic resonance imaging. *J Am Coll Cardiol* 2006;**47**:789–93.
 7. Mor-Avi V, Lang RM, Badano LP, Belohlavek M, Cardim NM, Derumeaux G et al. Current and evolving echocardiographic techniques for the quantitative evaluation of cardiac mechanics: ASE/EAE consensus statement on methodology and indications endorsed by the Japanese Society of Echocardiography. *Eur J Echocardiogr* 2011;**12**:167–205.
 8. Notomi Y, Lysyansky P, Setser RM, Shiota T, Popovic ZB, Martin-Miklovic MG et al. Measurement of ventricular torsion by two-dimensional ultrasound speckle tracking imaging. *J Am Coll Cardiol* 2005;**45**:2034–41.
 9. Helle-Valle T, Crosby J, Edvardsen T, Lyseggen E, Amundsen BH, Smith HJ et al. New noninvasive method for assessment of left ventricular rotation: speckle tracking echocardiography. *Circulation* 2005;**112**:3149–56.
 10. Alharthi MS, Jiamsripong P, Calleja A, Sengupta PP, McMahon EM, Khandheria B et al. Selective echocardiographic analysis of epicardial and endocardial left ventricular rotational mechanics in an animal model of pericardial adhesions. *Eur J Echocardiogr* 2009;**10**:357–62.
 11. Sengupta PP, Narula J. Reclassifying heart failure: predominantly subendocardial, subepicardial, and transmural. *Heart Fail Clin* 2008;**4**:379–82.
 12. Tanaka H, Oishi Y, Mizuguchi Y, Miyoshi H, Ishimoto T, Nagase N et al. Contribution of the pericardium to left ventricular torsion and regional myocardial function in patients with total absence of the left pericardium. *J Am Soc Echocardiogr* 2008;**21**:268–74.
 13. Chang SA, Kim HK, Kim YJ, Cho GY, Oh S, Sohn DW. Role of pericardium in the maintenance of left ventricular twist. *Heart* 2010;**96**:785–90.
 14. Halliburton SS. Recent technologic advances in multi-detector row cardiac CT. *Cardiol Clin* 2009;**27**:655–64.
 15. Verhaert D, Gabriel RS, Johnston D, Lytle BW, Desai MY, Klein AL. The role of multi-modality imaging in the management of pericardial disease. *Circ Cardiovasc Imaging* 2010;**3**:333–43.
 16. O'Leary SM, Williams PL, Williams MP, Edwards AJ, Roobottom CA, Morgan-Hughes GJ et al. Imaging the pericardium: appearances on ECG-gated 64-detector row cardiac computed tomography. *Br J Radiol* 2010;**83**:194–205.
 17. Rajiah P, Kanne JP. Computed tomography of the pericardium and pericardial disease. *J Cardiovasc Comput Tomogr* 2010;**4**:3–18.
 18. Imazio M, Brucato A, Derosa FG, Lestuzzi C, Bombana E, Scipione F et al. Aetiological diagnosis in acute and recurrent pericarditis: when and how. *J Cardiovasc Med (Hagerstown)* 2009;**10**:217–30.
 19. Bull RK, Edwards PD, Dixon AK. CT dimensions of the normal pericardium. *Br J Radiol* 1998;**71**:923–5.
 20. Breen JF. Imaging of the pericardium. *J Thorac Imaging* 2001;**16**:47–54.
 21. Sechtem U, Tscholakoff D, Higgins CB. MRI of the normal pericardium. *Am J Roentgenol* 1986;**147**:239–44.
 22. Stark DD, Higgins CB, Lanzer P, Lipton MJ, Schiller N, Crooks LE et al. Magnetic resonance imaging of the pericardium: normal and pathologic findings. *Radiology* 1984;**150**:469–74.
 23. Maisch B, Hufnagel G, Kolsch S, Funck R, Richter A, Rupp H et al. Treatment of inflammatory dilated cardiomyopathy and (peri)myocarditis with immunosuppression and i.v. immunoglobulins. *Herz* 2004;**29**:624–36.
 24. Lange RA, Hillis LD. Clinical practice. Acute pericarditis. *N Engl J Med* 2004;**351**:2195–202.
 25. Khandaker MH, Espinosa RE, Nishimura RA, Sinak LJ, Hayes SN, Melduni RM et al. Pericardial disease: diagnosis and management. *Mayo Clin Proc* 2010;**85**:572–93.
 26. Dorfman TA, Aql R. Regional pericarditis: a review of the pericardial manifestations of acute myocardial infarction. *Clin Cardiol* 2009;**32**:115–20.
 27. Sagrista-Sauleda J, Merce AS, Soler-Soler J. Diagnosis and management of pericardial effusion. *World J Cardiol* 2011;**3**:135–43.
 28. Maisch B, Seferovic PM, Ristic AD, Erbel R, Rienmuller R, Adler Y et al. Guidelines on the diagnosis and management of pericardial diseases executive summary; the Task force on the diagnosis and management of pericardial diseases of the European Society of Cardiology. *Eur Heart J* 2004;**25**:587–610.
 29. Imazio M, Adler Y. Management of pericardial effusion. *Eur Heart J* 2013;**34**:1186–97.
 30. Imazio M, Spodick DH, Brucato A, Trincherio R, Adler Y. Controversial issues in the management of pericardial diseases. *Circulation* 2010;**121**:916–28.
 31. Feng D, Glockner J, Kim K, Martinez M, Syed IS, Araoz P et al. Cardiac magnetic resonance imaging pericardial late gadolinium enhancement and elevated inflammatory markers can predict the reversibility of constrictive pericarditis after anti-inflammatory medical therapy: a pilot study. *Circulation* 2011;**124**:1830–7.
 32. Bogaert J, Centonze M, Vanneste R, Franccone M. Cardiac and pericardial abnormalities on chest computed tomography: what can we see? *Radiol Med* 2010;**115**:175–90.
 33. Rifkin RD, Mernoff DB. Noninvasive evaluation of pericardial effusion composition by computed tomography. *Am Heart J* 2005;**149**:1120–7.
 34. Taylor AM, Dymarkowski S, Verbeken EK, Bogaert J. Detection of pericardial inflammation with late-enhancement cardiac magnetic resonance imaging: initial results. *Eur Radiol* 2006;**16**:569–74.
 35. Skouri HN, Dec GW, Friedrich MG, Cooper LT. Noninvasive imaging in myocarditis. *J Am Coll Cardiol* 2006;**48**:2085–93.
 36. Mahrholdt H, Wagner A, Deluigi CC, Kispert E, Hager S, Meinhardt G et al. Presentation, patterns of myocardial damage, and clinical course of viral myocarditis. *Circulation* 2006;**114**:1581–90.
 37. Kawel N, Nacif M, Zavodni A, Jones J, Liu S, Sibley CT et al. T1 mapping of the myocardium: intra-individual assessment of the effect of field strength, cardiac cycle and variation by myocardial region. *J Cardiovasc Magn Reson* 2012;**14**:27.
 38. Ain DL, Narula J, Sengupta PP. Cardiovascular imaging and diagnostic procedures in pregnancy. *Cardiol Clin* 2012;**30**:331–41.
 39. Tsang TS, Oh JK, Seward JB. Diagnosis and management of cardiac tamponade in the era of echocardiography. *Clin Cardiol* 1999;**22**:446–52.
 40. Franccone M, Dymarkowski S, Kalantzi M, Bogaert J. Real-time cine MRI of ventricular septal motion: a novel approach to assess ventricular coupling. *J Magn Reson Imaging* 2005;**21**:305–9.
 41. Giorgi B, Mollet NR, Dymarkowski S, Rademakers FE, Bogaert J. Clinically suspected constrictive pericarditis: MR imaging assessment of ventricular septal motion and configuration in patients and healthy subjects. *Radiology* 2003;**228**:417–24.
 42. Friedrich MG, Sechtem U, Schulz-Menger J, Holmvang G, Alakija P, Cooper LT et al. Cardiovascular magnetic resonance in myocarditis: a JACC White Paper. *J Am Coll Cardiol* 2009;**53**:1475–87.
 43. Callahan JA, Seward JB, Tajik AJ. Cardiac tamponade: pericardiocentesis directed by two-dimensional echocardiography. *Mayo Clin Proc* 1985;**60**:344–7.
 44. Dubourg O, Ferrier A, Gueret P, Farcot JC, Terdjman M, Rocha P et al. Two-dimensional contrast echocardiography during the drainage of hemopericardium with tamponade. *Presse Med* 1983;**12**:2225–8.
 45. Chandraratna PA, Reid CL, Nimalasuriya A, Kawanishi D, Rahimtoola SH. Application of 2-dimensional contrast studies during pericardiocentesis. *Am J Cardiol* 1983;**52**:1120–2.
 46. Callahan JA, Seward JB, Tajik AJ, Holmes DR Jr, Smith HC, Reeder GS et al. Pericardiocentesis assisted by two-dimensional echocardiography. *J Thorac Cardiovasc Surg* 1983;**85**:877–9.
 47. Pepi M. Ultrasound-guided pericardiocentesis. *Cardiologia* 1995;**40**:783–5.
 48. Wong B, Murphy J, Chang CJ, Hassenein K, Dunn M. The risk of pericardiocentesis. *Am J Cardiol* 1979;**44**:1110–4.
 49. Tsang TS, Freeman WK, Barnes ME, Reeder GS, Packer DL, Seward JB. Rescue echocardiographically guided pericardiocentesis for cardiac perforation complicating catheter-based procedures. The Mayo Clinic experience. *J Am Coll Cardiol* 1998;**32**:1345–50.
 50. Rafique AM, Patel N, Biner S, Eshaghian S, Mendoza F, Cercce B et al. Frequency of recurrence of pericardial tamponade in patients with extended versus nonextended pericardial catheter drainage. *Am J Cardiol* 2011;**108**:1820–5.
 51. Buchanan CL, Sullivan VV, Lampman R, Kulkarni MG. Pericardiocentesis with extended catheter drainage: an effective therapy. *Ann Thorac Surg* 2003;**76**:817–20.
 52. McDonald JM, Meyers BF, Guthrie TJ, Battafarano RJ, Cooper JD, Patterson GA. Comparison of open subxiphoid pericardial drainage with percutaneous catheter drainage for symptomatic pericardial effusion. *Ann Thorac Surg* 2003;**76**:811–5; discussion 6.
 53. Tsang TS, Enriquez-Sarano M, Freeman WK, Barnes ME, Sinak LJ, Gersh BJ et al. Consecutive 1127 therapeutic echocardiographically guided pericardiocenteses: clinical profile, practice patterns, and outcomes spanning 21 years. *Mayo Clin Proc* 2002;**77**:429–36.
 54. Susini G, Pepi M, Sisillo E, Bortone F, Salvi L, Barbier P et al. Percutaneous pericardiocentesis versus subxiphoid pericardiotomy in cardiac tamponade due to post-operative pericardial effusion. *J Cardiothorac Vasc Anesth* 1993;**7**:178–83.
 55. Becit N, Unlu Y, Ceviz M, Kocogullari CU, Kocak H, Gurlertop Y. Subxiphoid pericardiotomy in the management of pericardial effusions: case series analysis of 368 patients. *Heart* 2005;**91**:785–90.
 56. Sagrista-Sauleda J, Angel J, Permanyer-Miralda G, Soler-Soler J. Long-term follow-up of idiopathic chronic pericardial effusion. *N Engl J Med* 1999;**341**:2054–9.

57. Merce J, Sagrista-Sauleda J, Permanyer-Miralda G, Soler-Soler J. Should pericardial drainage be performed routinely in patients who have a large pericardial effusion without tamponade? *Am J Med* 1998;**105**:106–9.
58. Levine MJ, Lorell BH, Diver DJ, Come PC. Implications of echocardiographically assisted diagnosis of pericardial tamponade in contemporary medical patients: detection before hemodynamic embarrassment. *J Am Coll Cardiol* 1991;**17**:59–65.
59. Maisch B, Ristic AD. Practical aspects of the management of pericardial disease. *Heart* 2003;**89**:1096–103.
60. Maisch B, Ristic AD, Pankuweit S, Neubauer A, Moll R. Neoplastic pericardial effusion. Efficacy and safety of intrapericardial treatment with cisplatin. *Eur Heart J* 2002;**23**:1625–31.
61. Spodick DH. Intrapericardial therapeutics and diagnostics. *Am J Cardiol* 2000;**85**:1012–4.
62. Holmes DR Jr, Nishimura R, Fountain R, Turi ZG. Iatrogenic pericardial effusion and tamponade in the percutaneous intracardiac intervention era. *JACC Cardiovasc Interv* 2009;**2**:705–17.
63. Atar S, Chiu J, Forrester JS, Siegel RJ. Bloody pericardial effusion in patients with cardiac tamponade: is the cause cancerous, tuberculous, or iatrogenic in the 1990s? *Chest* 1999;**116**:1564–9.
64. Huang XM, Hu JQ, Zhou F, Qin YW, Cao J, Zhou BY et al. Early diagnosis and rescue pericardiocentesis for acute cardiac tamponade during radiofrequency ablation for arrhythmias. Is fluoroscopy enough? *Pacing Clin Electrophysiol* 2011;**34**:9–14.
65. Pepi M, Muratori M, Barbier P, Doria E, Arena V, Berti M et al. Pericardial effusion after cardiac surgery: incidence, site, size, and haemodynamic consequences. *Br Heart J* 1994;**72**:327–31.
66. Kuvini JT, Harati NA, Pandian NG, Bojar RM, Khabbaz KR. Postoperative cardiac tamponade in the modern surgical era. *Ann Thorac Surg* 2002;**74**:1148–53.
67. Meurin P, Weber H, Renaud N, Larrazet F, Tabet JY, Demolis P et al. Evolution of the postoperative pericardial effusion after day 15: the problem of the late tamponade. *Chest* 2004;**125**:2182–7.
68. Beppu S, Tanaka N, Nakatani S, Ikegami K, Kumon K, Miyatake K. Pericardial clot after open heart surgery: its specific localization and haemodynamics. *Eur Heart J* 1993;**14**:230–4.
69. Ling LH, Oh JK, Schaff HV, Danielson GK, Mahoney DW, Seward JB et al. Constrictive pericarditis in the modern era: evolving clinical spectrum and impact on outcome after pericardiectomy. *Circulation* 1999;**100**:1380–6.
70. Schwefer M, Aschenbach R, Heidemann J, Mey C, Lapp H. Constrictive pericarditis, still a diagnostic challenge: comprehensive review of clinical management. *Eur J Cardiothorac Surg* 2009;**36**:502–10.
71. Mayosi BM. Contemporary trends in the epidemiology and management of cardiomyopathy and pericarditis in sub-Saharan Africa. *Heart* 2007;**93**:1176–83.
72. Oh JK, Hatle LK, Seward JB, Danielson GK, Schaff HV, Reeder GS et al. Diagnostic role of Doppler echocardiography in constrictive pericarditis. *J Am Coll Cardiol* 1994;**23**:154–62.
73. Palka P, Lange A, Donnelly JE, Nihoyannopoulos P. Differentiation between restrictive cardiomyopathy and constrictive pericarditis by early diastolic Doppler myocardial velocity gradient at the posterior wall. *Circulation* 2000;**102**:655–62.
74. Talreja DR, Edwards WVD, Danielson GK, Schaff HV, Tajik AJ, Tazelaar HD et al. Constrictive pericarditis in 26 patients with histologically normal pericardial thickness. *Circulation* 2003;**108**:1852–7.
75. Kojima S, Yamada N, Goto Y. Diagnosis of constrictive pericarditis by tagged cine magnetic resonance imaging. *N Engl J Med* 1999;**341**:373–4.
76. Francione M, Dymarkowski S, Kalantzi M, Rademakers FE, Bogaert J. Assessment of ventricular coupling with real-time cine MRI and its value to differentiate constrictive pericarditis from restrictive cardiomyopathy. *Eur Radiol* 2006;**16**:944–51.
77. Reinmuller R, Gurgan M, Erdmann E, Kemkes BM, Kreutzer E, Weinhold C. CT and MR evaluation of pericardial constriction: a new diagnostic and therapeutic concept. *J Thorac Imaging* 1993;**8**:108–21.
78. Leitman M, Bachner-Hinzenon N, Adam D, Fuchs T, Theodorovich N, Peleg E et al. Speckle tracking imaging in acute inflammatory pericardial diseases. *Echocardiography* 2011;**28**:548–55.
79. Sengupta PP, Krishnamoorthy VK, Abhayaratna WP, Korinek J, Belohlavek M, Sundt TM 3rd et al. Disparate patterns of left ventricular mechanics differentiate constrictive pericarditis from restrictive cardiomyopathy. *JACC Cardiovasc Imaging* 2008;**1**:29–38.
80. Sengupta PP, Tajik AJ, Chandrasekaran K, Khandheria BK. Twist mechanics of the left ventricle: principles and application. *JACC Cardiovasc Imaging* 2008;**1**:366–76.
81. Sagrista-Sauleda J, Angel J, Sanchez A, Permanyer-Miralda G, Soler-Soler J. Effusive-constrictive pericarditis. *N Engl J Med* 2004;**350**:469–75.
82. Hancock EW. A clearer view of effusive-constrictive pericarditis. *N Engl J Med* 2004;**350**:435–7.
83. Haley JH, Tajik AJ, Danielson GK, Schaff HV, Mulvagh SL, Oh JK. Transient constrictive pericarditis: causes and natural history. *J Am Coll Cardiol* 2004;**43**:271–5.
84. Hoffmann U, Globits S, Frank H. Cardiac and paracardiac masses. Current opinion on diagnostic evaluation by magnetic resonance imaging. *Eur Heart J* 1998;**19**:553–63.
85. Demos TC, Budorick NE, Posniak HV. Benign mediastinal cysts: pointed appearance on CT. *J Comput Assist Tomogr* 1989;**13**:132–3.
86. Jeung MY, Gasser B, Gangi A, Bogorin A, Charneau D, Wihlm JM et al. Imaging of cystic masses of the mediastinum. *Radiographics* 2002;**22 Spec No**:S79–93.
87. Rosito GA, Massaro JM, Hoffmann U, Ruberg FL, Mahabadi AA, Vasan RS et al. Pericardial fat, visceral abdominal fat, cardiovascular disease risk factors, and vascular calcification in a community-based sample: the Framingham Heart Study. *Circulation* 2008;**117**:605–13.