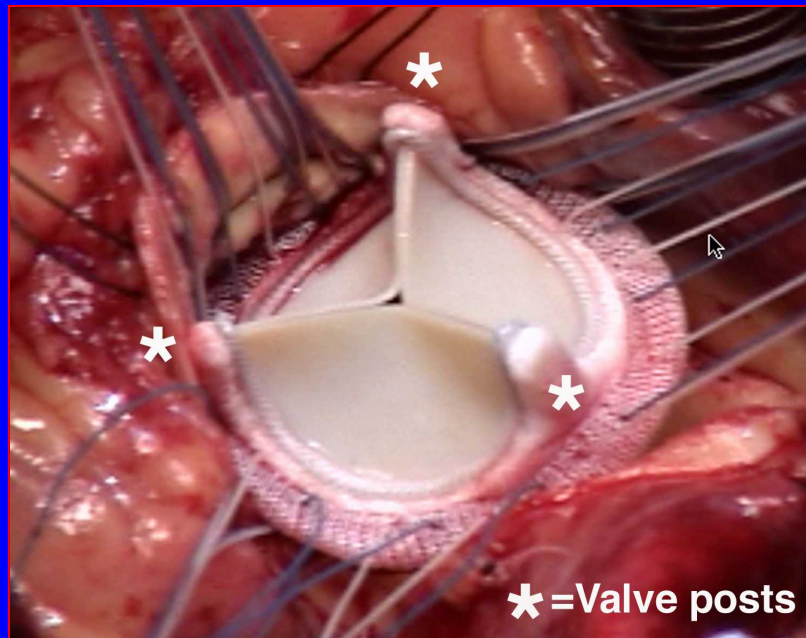


# Are We Managing Prosthetic Valve Endocarditis Correctly ?

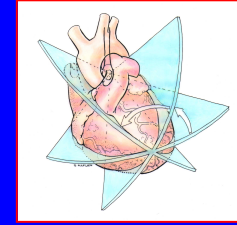
## The Best Approach to Diagnosis



**Catherine M. Otto, MD**  
**Professor of Medicine**  
**University of Washington**

# Diagnosis of Prosthetic Valve Endocarditis

## Duke Major Criteria



### ***Positive blood cultures***

Typical microorganisms from 2 separate BCs  
Persistently positive BCs

### ***Evidence of endocardial involvement***

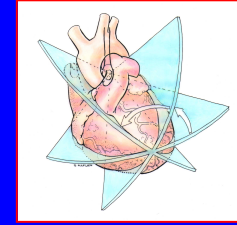
Positive echo for endocarditis

- Vegetation
- Abscess
- Prosthetic valve dehiscence

**New valvular regurgitation**

# Diagnosis of Prosthetic Valve Endocarditis

## Duke Minor Criteria



- ***Predisposing Condition***
- ***Fever > 38° C***
- ***Vascular phenomenon***  
(arterial emboli, pulmonary infarct, mycotic aneurysm, etc)
- ***Immunologic phenomenon***  
(glomerulonephritis, Osler's nodes, etc)
- ***Other microbiologic evidence***

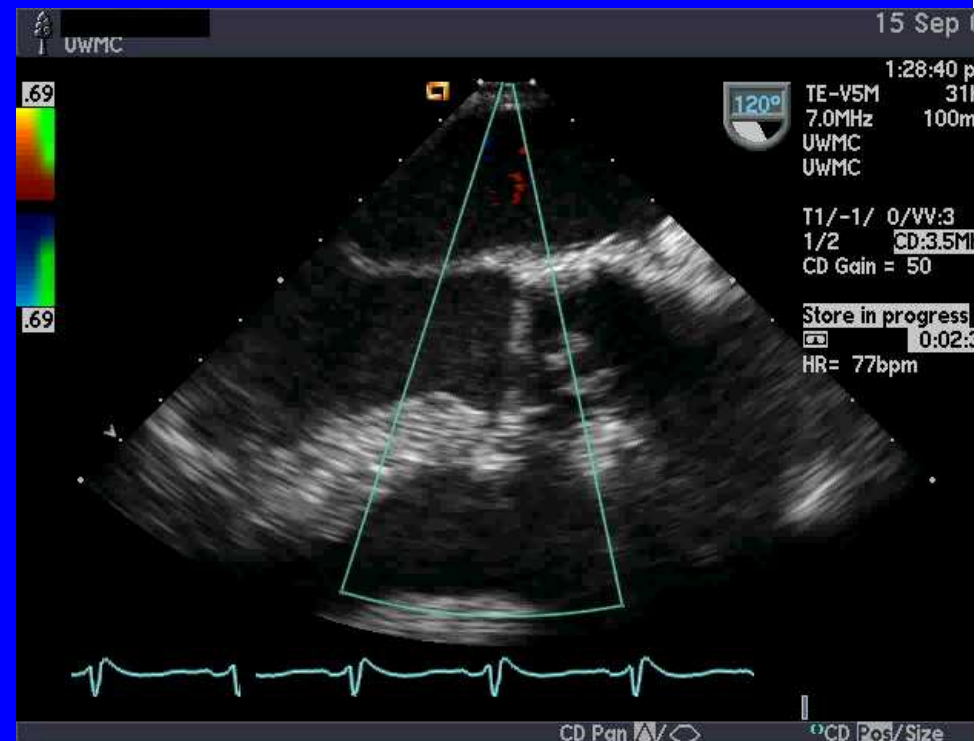
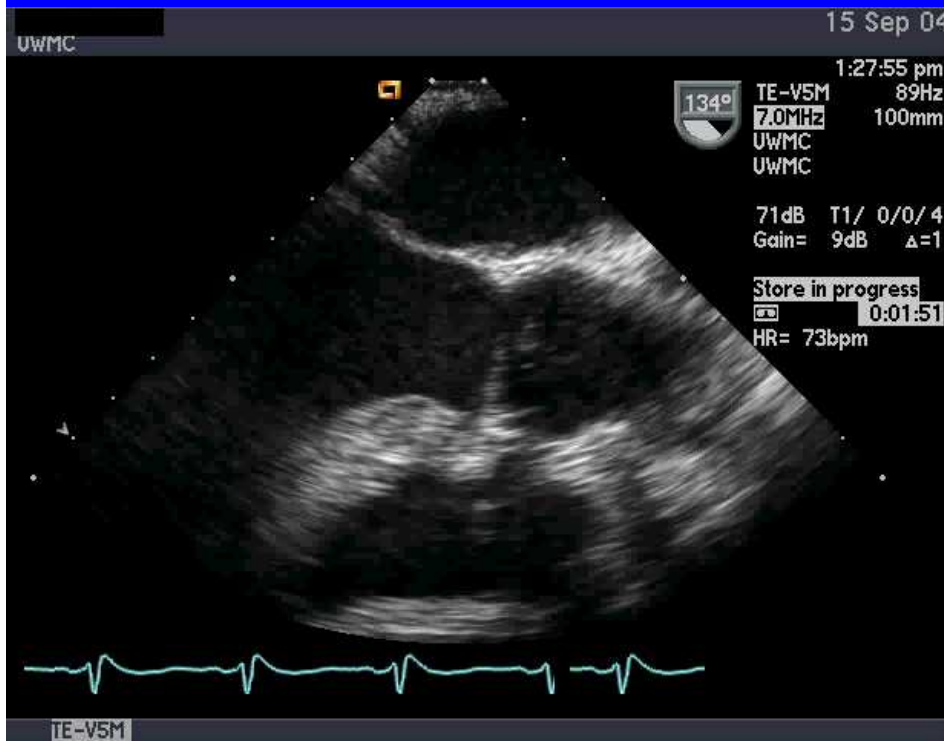
# Diagnosis of Prosthetic Valve Endocarditis

## 52 physician with prosthetic AVR

- Tissue AVR for severe AR 4 yrs ago
- Chronic nonproductive cough for 1 year
- Mediastinal lymphadenopathy (reactive)
- Splenic infarct 10 mo. ago (started on warfarin)
- Low grade fever starting 8 mo. ago (self medicated with oral antibiotics)
- Increasing fatigue and exertional dyspnea
- Blood cultures negative

# Diagnosis of Prosthetic Valve Endocarditis

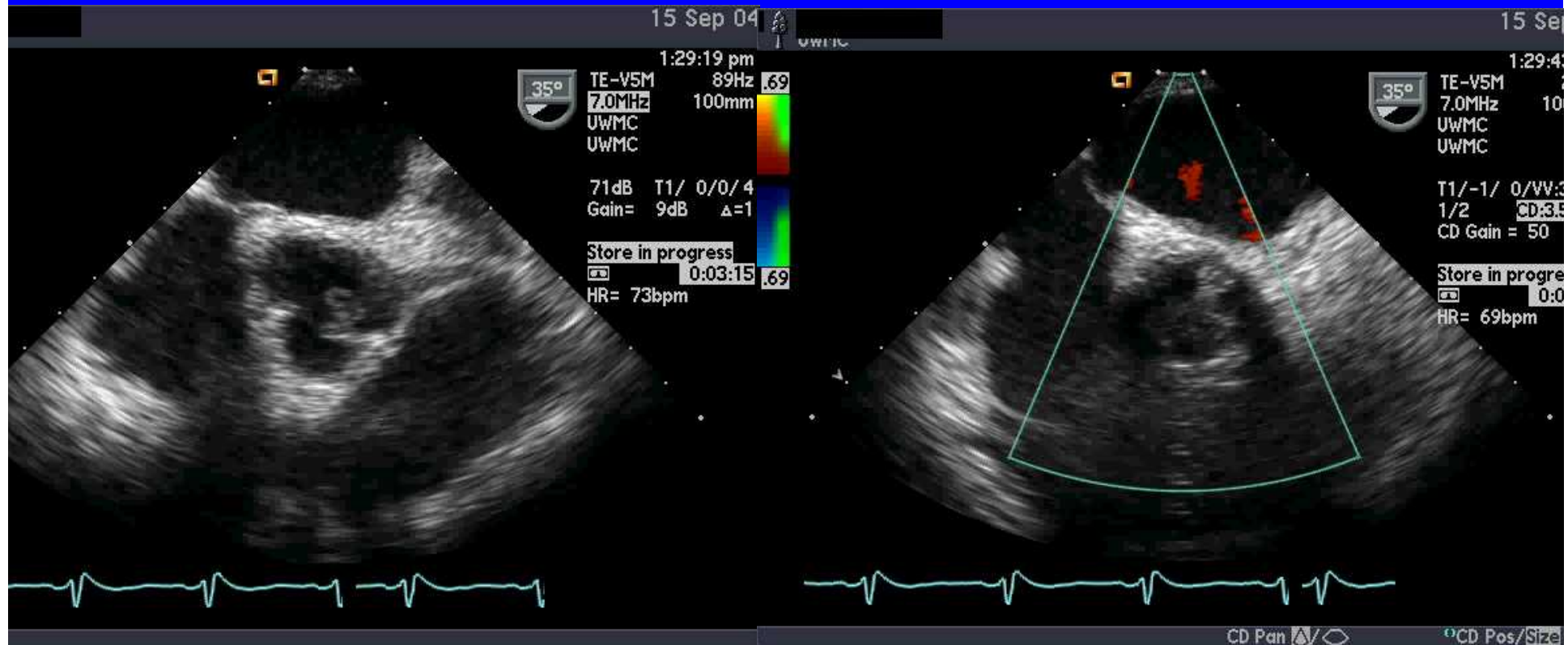
## 52 physician with prosthetic AVR



Also had a history of closed VSD and PDA

# Diagnosis of Prosthetic Valve Endocarditis

## 52 physician with prosthetic AVR



**Tissue AVR, leaflet redundancy**  
**No vegetation or regurgitation**

# Diagnosis of Prosthetic Valve Endocarditis

## 52 physician with prosthetic AVR

- TIA symptoms 3 months ago despite warfarin  
Multiple lesions on head CT  
Concern for metastatic disease
- Non-ST elevation myocardial infarction 3 mo. ago
- New CHF with EF 28%
- Now presents with chest pain

# Diagnosis of Prosthetic Valve Endocarditis

## 52 physician with chest pain

### *Physical Exam:*

T 37.3 °C

BP 104/70 HR 98

Neck: No JVD, Carotids normal

Chest: Clear, RR 16, SaO<sub>2</sub> 98%

Cardiac: No murmur

Abdomen: Benign

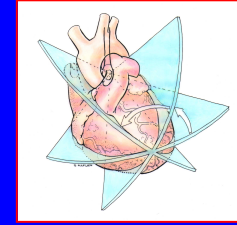
Ext: No cyanosis, clubbing, edema

Skin: No lesions

Neuro: Intact

# Diagnosis of Prosthetic Valve Endocarditis

## Duke Criteria



### ***Definite Endocarditis***

**2 major**

**1 major + 3 minor**

**5 minor**

### ***Probable Endocarditis***

**1 major + 1 minor**

**3 minor**

**Pt with prosthetic valve  
and history of fever and  
embolic events**

**Already has  
3 minor criteria  
for endocarditis ?**

# Diagnosis of Prosthetic Valve Endocarditis

## Clinical Features

<b>Fever</b>	<b>95%</b>
<b>New murmur or <math>\Delta</math> murmur</b>	<b>10- 25%</b>
<b>Pre-existing murmur</b>	<b>85- 95%</b>
<b>Osler's nodes</b>	<b>10-15%</b>
<b>Janeway lesions</b>	<b>3- 5%</b>
<b>Roth spots</b>	<b>2-10%</b>
<b>Anemia</b>	<b>70-90%</b>
<b>Circulating immune complexes</b>	<b>95%</b>
<b>Elevated CRP, RF</b>	<b>94-97%</b>
<b>Microscopic hematuria</b>	<b>30-60%</b>

# Diagnosis of Prosthetic Valve Endocarditis

## 52 physician with chest pain

### ***Labs:***

**WBC**            **16.3 (reactive lymphs)**

**Hct**             **29**

**Troponin**    **5.5 (elevated)**

**Blood cultures: Negative**

**MRI head: Small lesions suggestive of CVAs**

**CXR: Cardiomegaly, no pulmonary findings**

# Diagnosis of Prosthetic Valve Endocarditis

## Bacteriology

### **Early (within 2 months)**

Staph aureus  
Staph epidermidis  
Gram negative bacilli

### **Late**

Strep viridans  
Staph aureus

**Culture negative in 5%**

### **Other**

HACEK group  
Fungi  
Coxiella (Q-fever)  
Brucella  
Bartonella  
Chlamydia

**Almost any organism  
can cause endocarditis**

# Diagnosis of Prosthetic Valve Endocarditis

## Bacteriologic diagnosis

### *Blood cultures*

- Minimum 3 over 24 hours (Dx from 1<sup>st</sup> 2 in 90%)
- Separate venipuncture sites
- Minimum of 10 mL per culture (in adults)
- Start Rx (if possible) after cultures over 24 hrs
- If Rx cannot be delayed, 3 cultures over 1 hr

# Diagnosis of Prosthetic Valve Endocarditis

## Bacteriologic diagnosis

### *Problems*

- Preceding antibiotic Rx
- Culture negative in 3-4% of cases (50% of fungal)
- Some organisms difficult to isolate
- Prolonged incubation
  - Extended incubation or 4-6 wks (e.g. for HACEK)
- Special media or microbiologic method
  - Antigen (Aspergillus, Legionella)
  - Serology (Q-fever/Coxiella, Bartonella, Chlamydia)

# Diagnosis of Prosthetic Valve Endocarditis

## 52 physician with chest pain

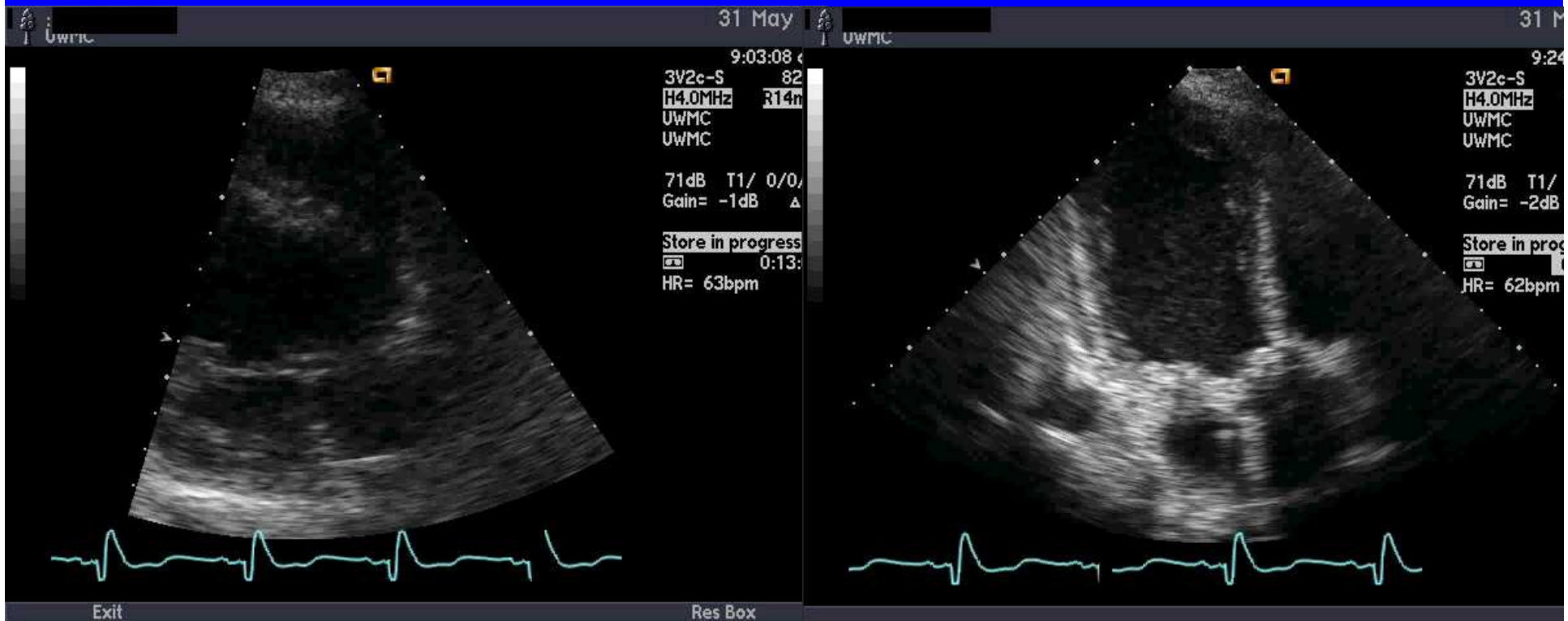### *Hospital Course:*

- CHF with EF 11%, Rx with dobutamine
- Coronary angiography r
- Recurrent fevers
- Wide complex tachycard
- Progressive acidosis
- Exploratory laparotomy (negative for bowel ischemia)

**Negative blood cultures**  
17 sets over 2 wks  
Bacterial, fungal, AFB  
Aerobic and anerobic  
Extended incubation

# Diagnosis of Prosthetic Valve Endocarditis

## Transthoracic Echo

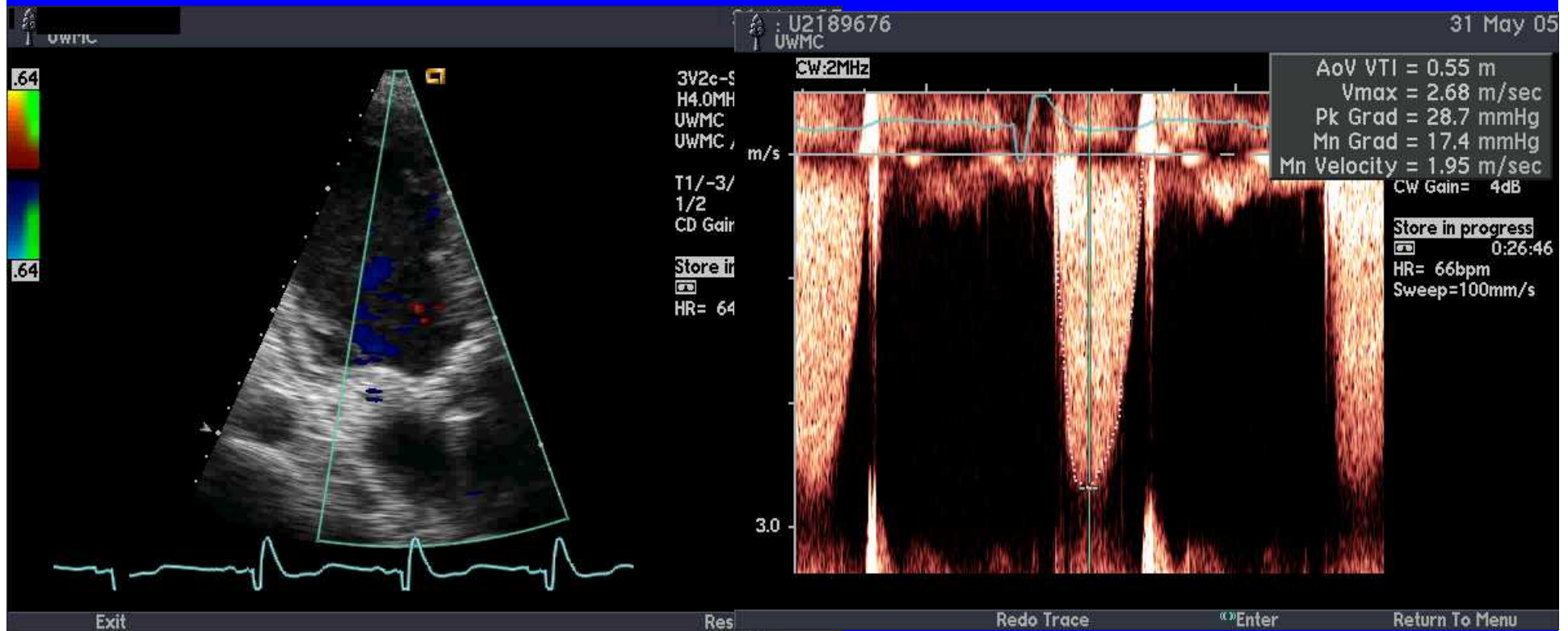


Poor parasternal images

?Thick leaflets from apex

# Diagnosis of Prosthetic Valve Endocarditis

## Transthoracic Echo

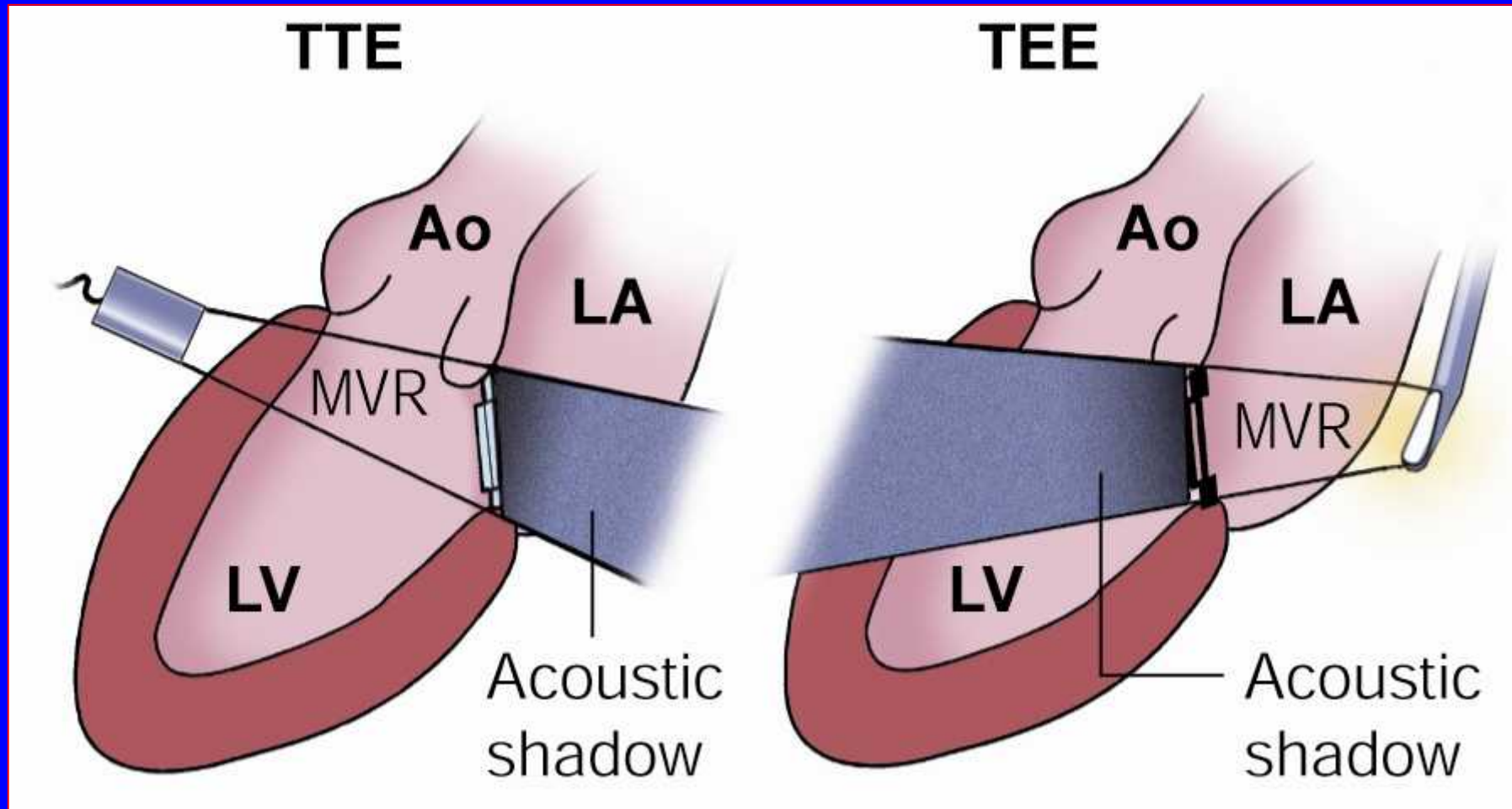


**No AR on color Doppler**

**Aortic jet 2.7 m/s on CWD**

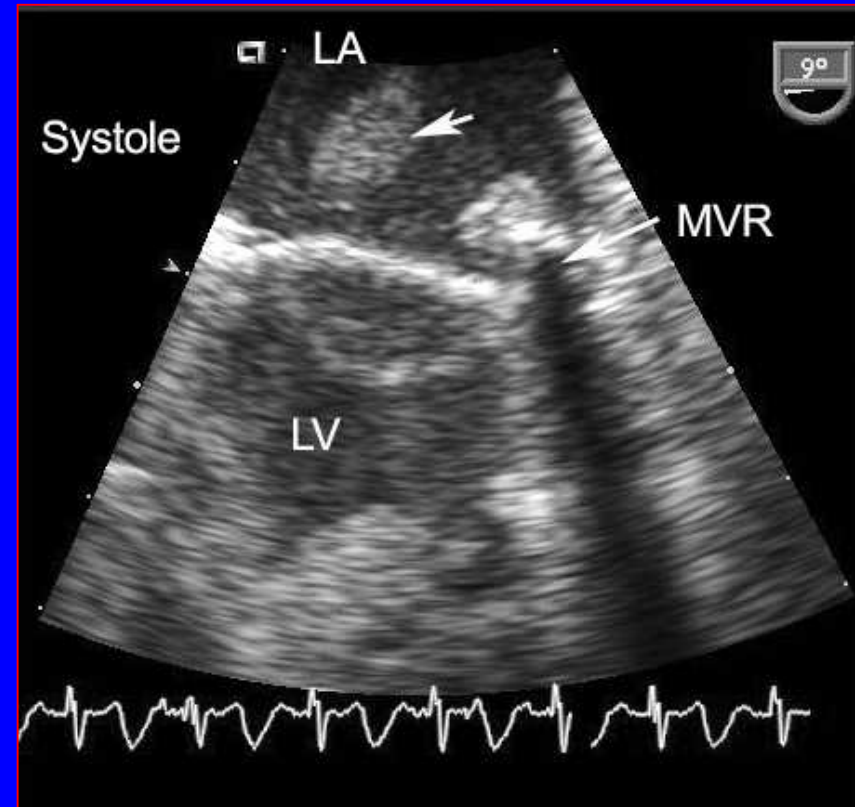
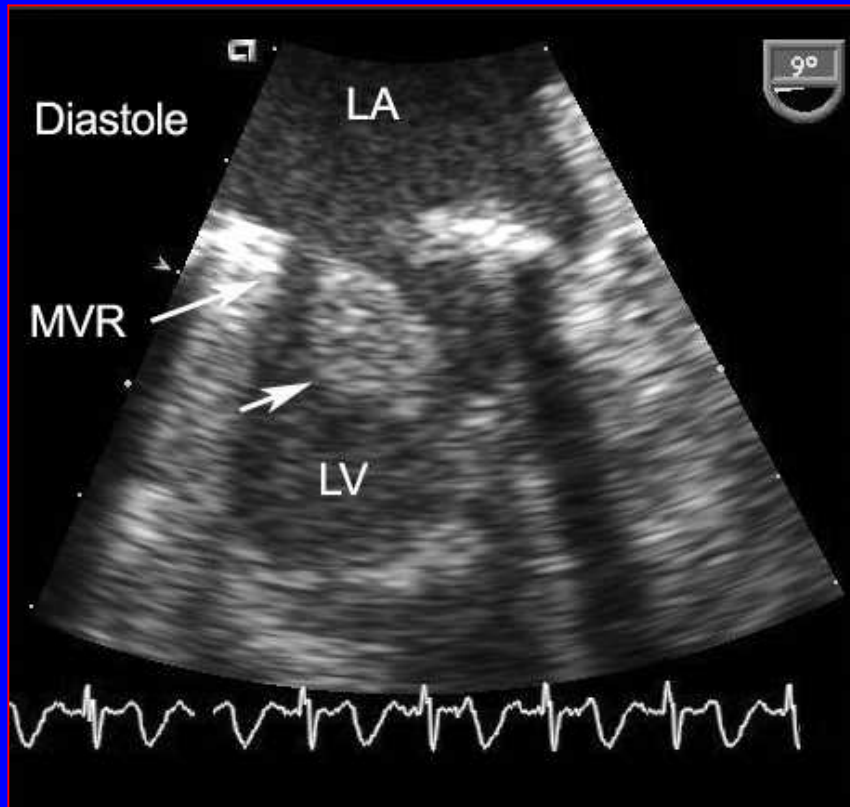
# Diagnosis of Prosthetic Valve Endocarditis

## Echocardiography



# Diagnosis of Prosthetic Valve Endocarditis

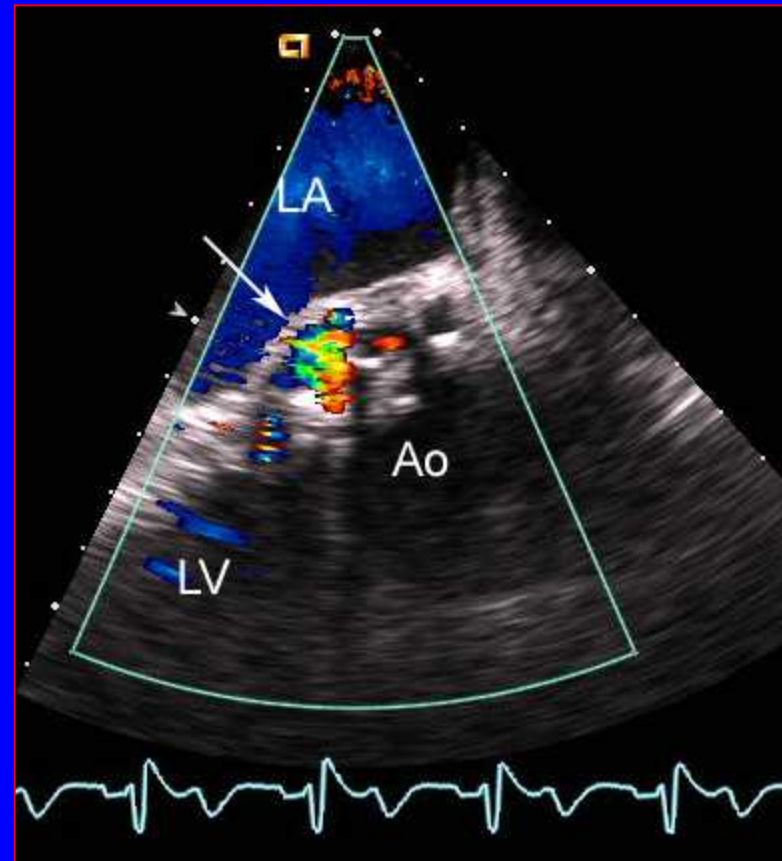
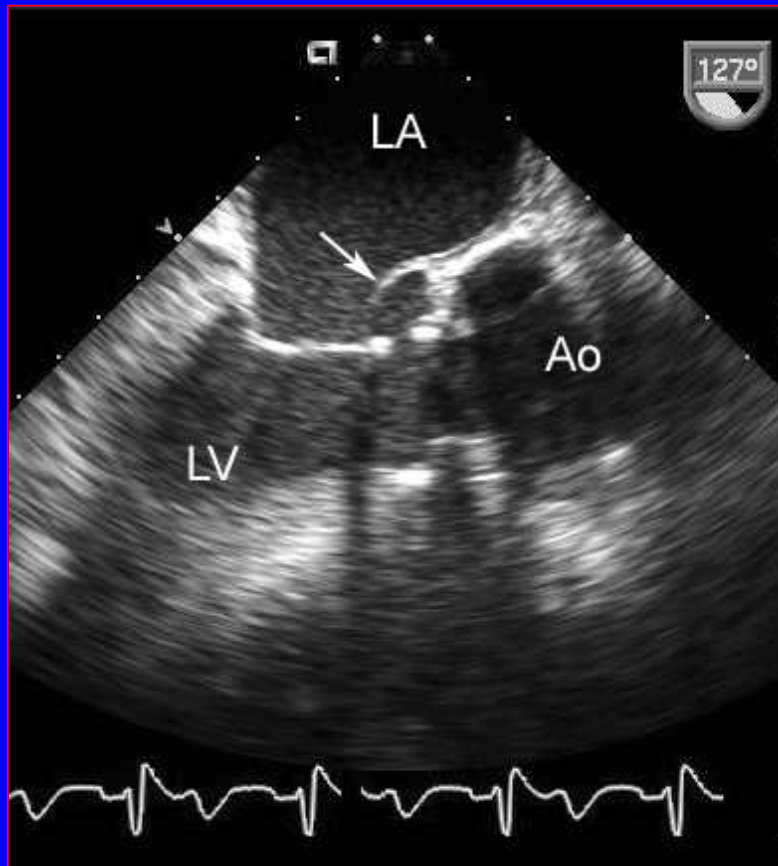
## TEE detection of Vegetations



**56F with Staph bacteremia and hypotension  
5 years after mechanical bileaflet MVR**

# Diagnosis of Prosthetic Valve Endocarditis

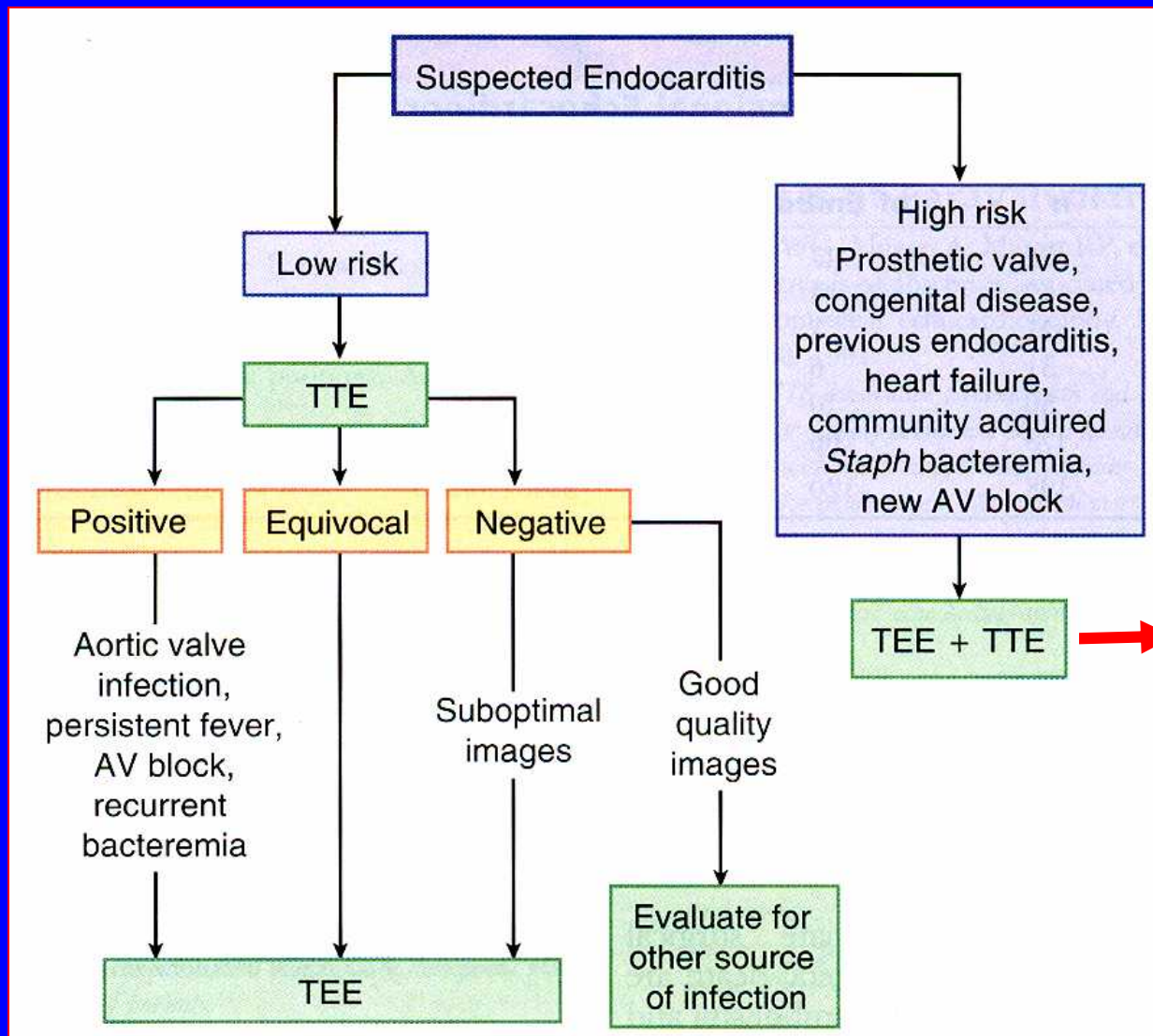
## TEE detection of abscess



**Persistent fevers after tissue AVR  
with aneurysm of aortic mitral intervalvular fibrosa**

# Diagnosis of Prosthetic Valve Endocarditis

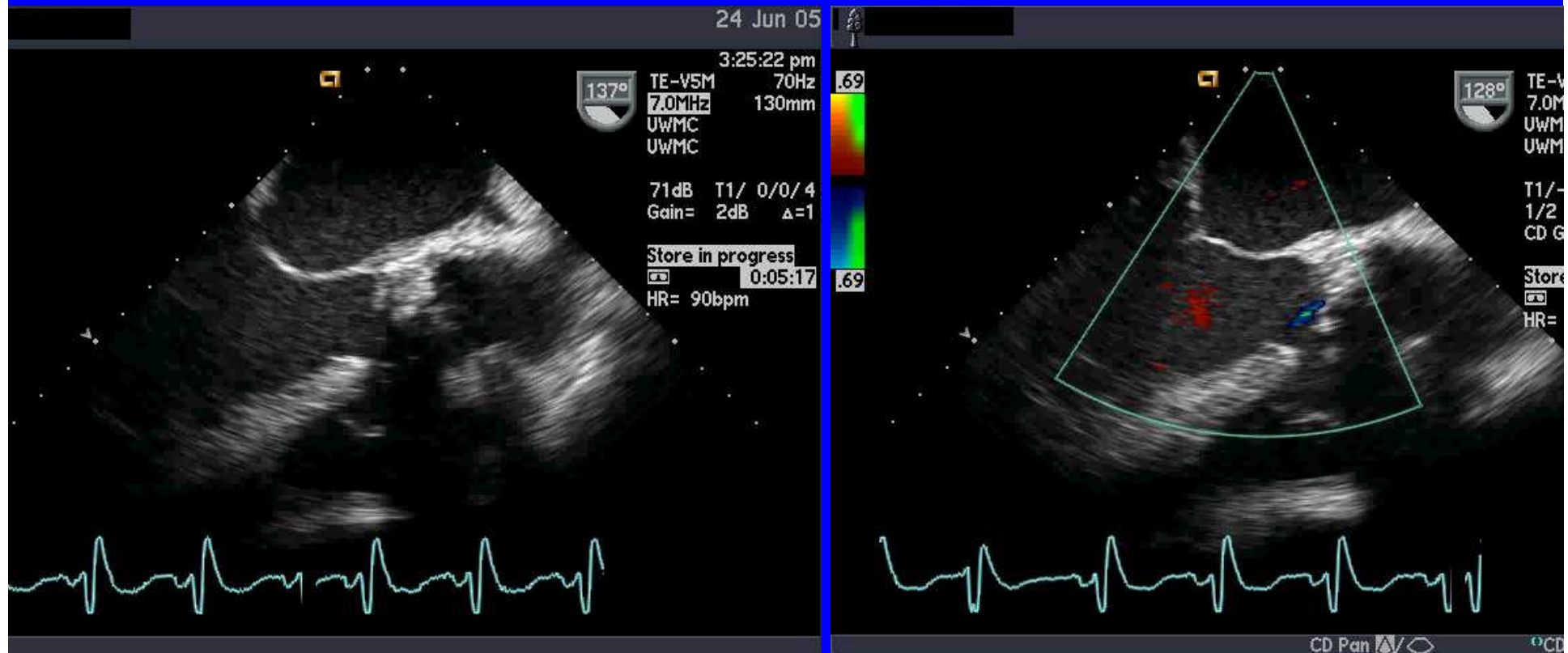
## Role of TEE – needed in ALL patients



**Also need TTE,  
esp. with AVR**

# Diagnosis of Prosthetic Valve Endocarditis

## 2<sup>nd</sup> TEE in 52M with AVR



**Marked leaflet thickening, still little AR**

# Diagnosis of Prosthetic Valve Endocarditis

## Echocardiography

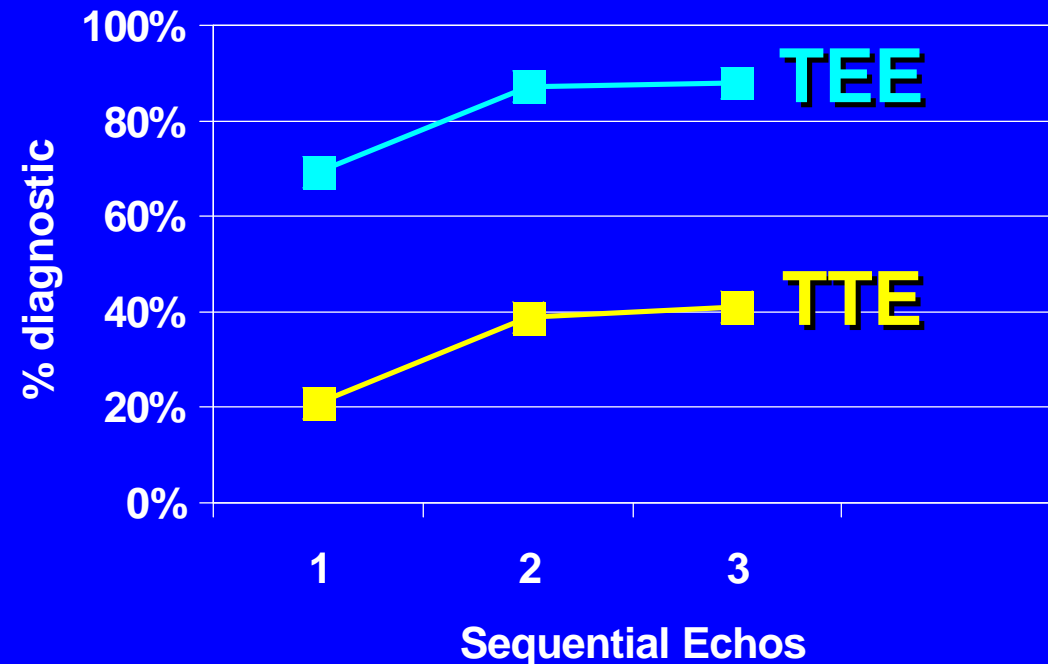
266 cases  
127 definite endocarditis

### *Repeated exams*

2.4 TTE (int. 7.4 days)  
1.2 TEE (int. 12.4 days)

### *High risk group*

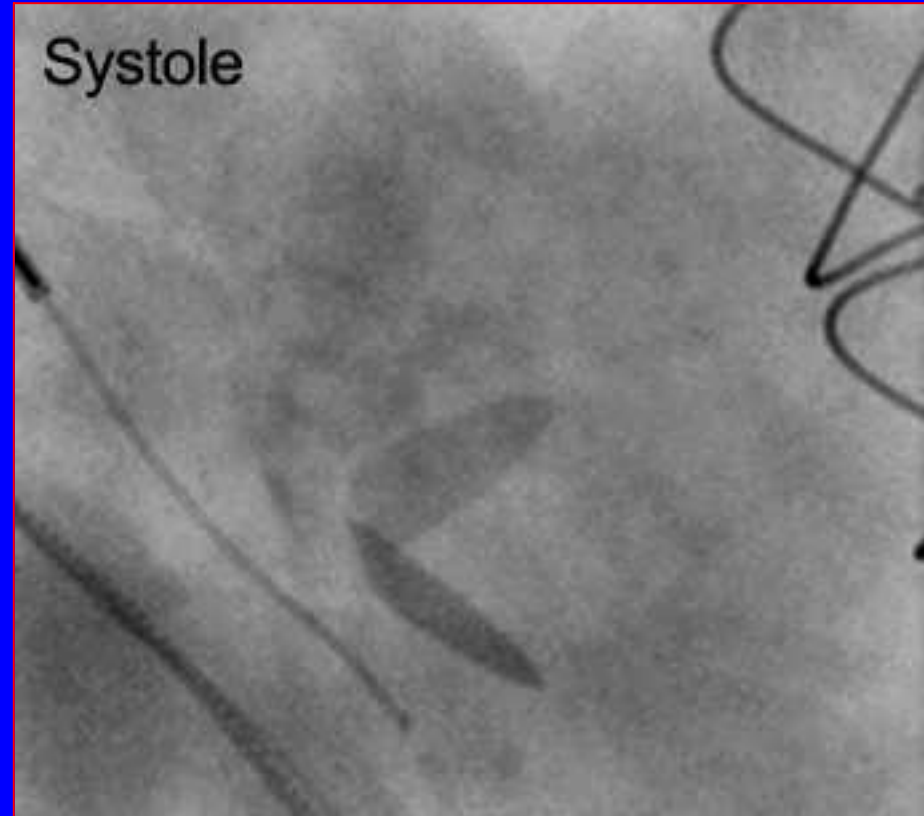
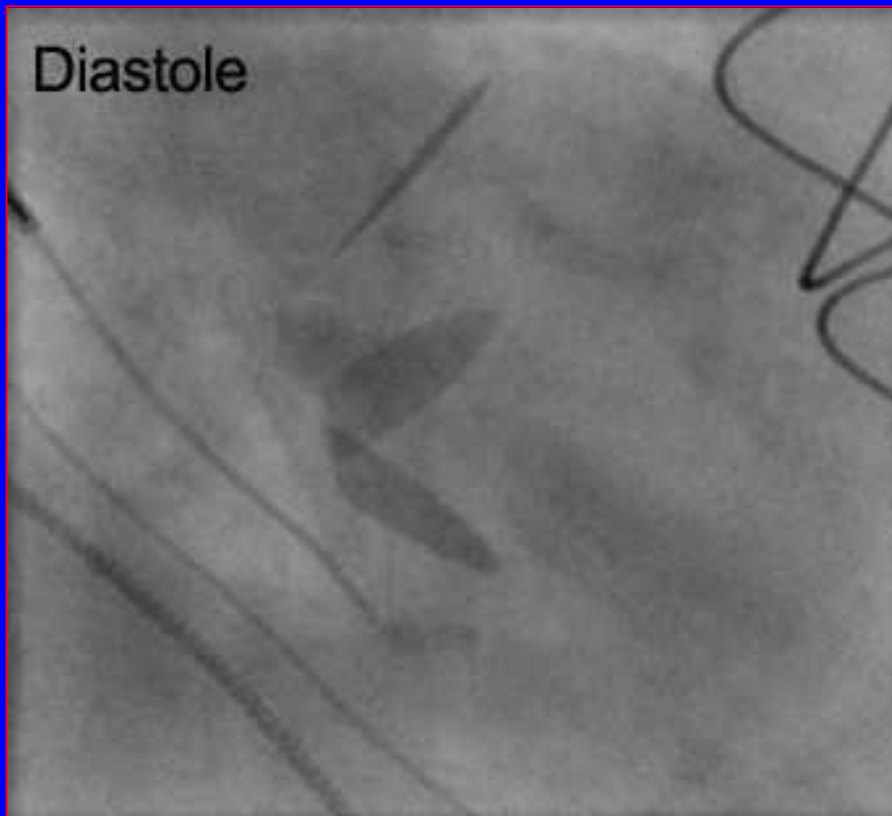
Prosthetic valves 55%  
Culture negative 26%



Vieira et al, Heart 2004; 90: 1020

# Diagnosis of Prosthetic Valve Endocarditis

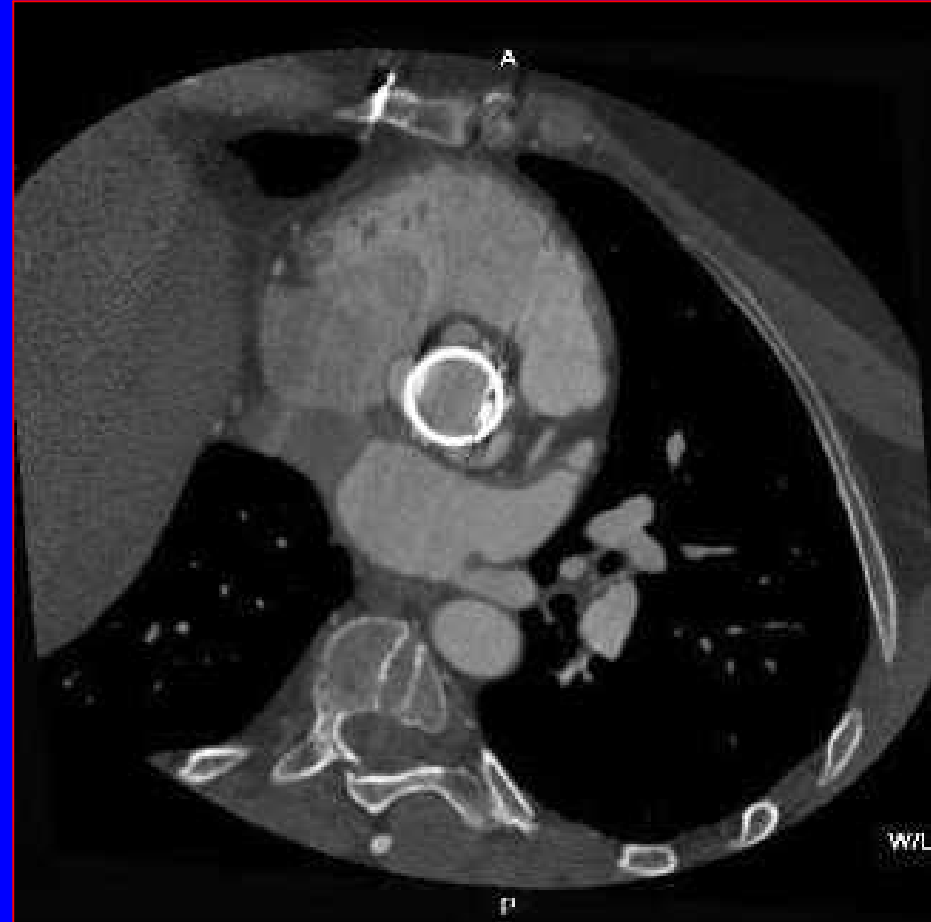
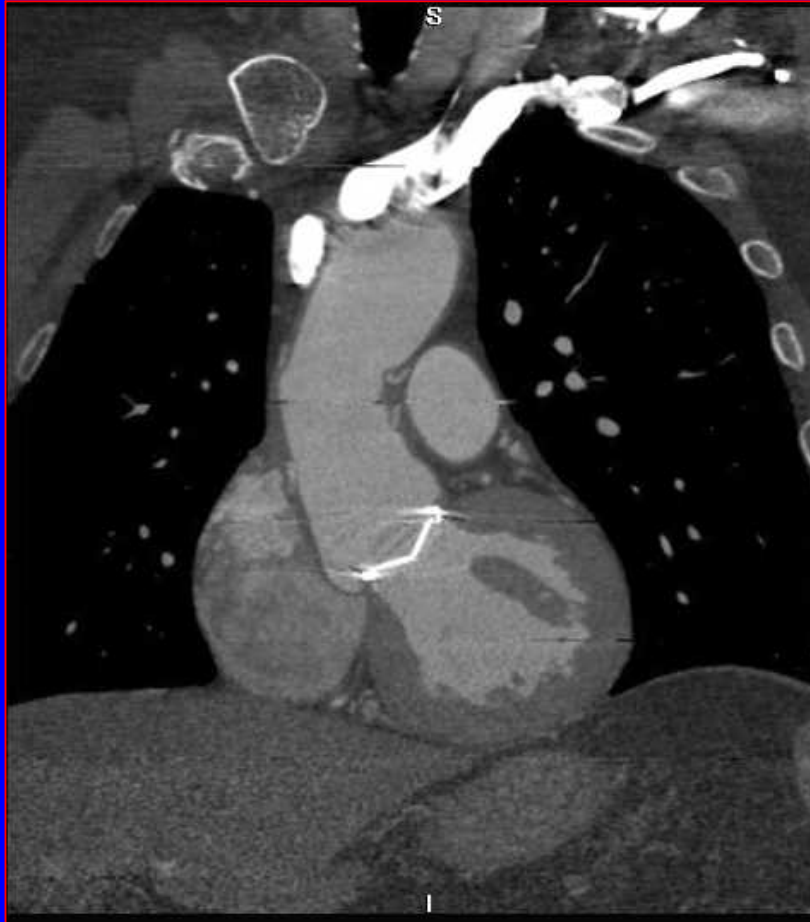
## Fluoroscopy – rarely helpful



**Shows leaflet motion, not vegetations**

# Diagnosis of Prosthetic Valve Endocarditis

## CT Imaging

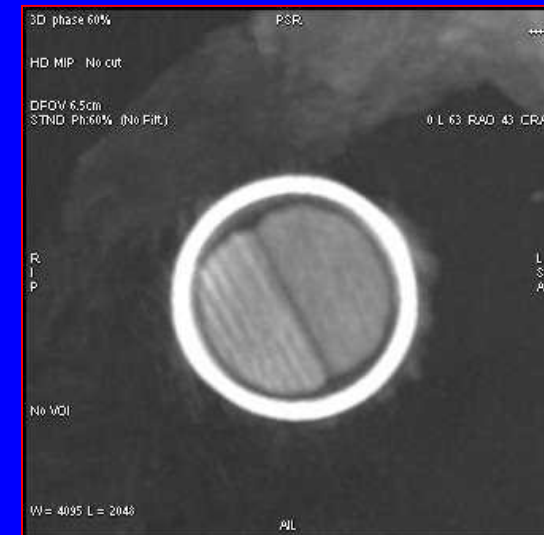
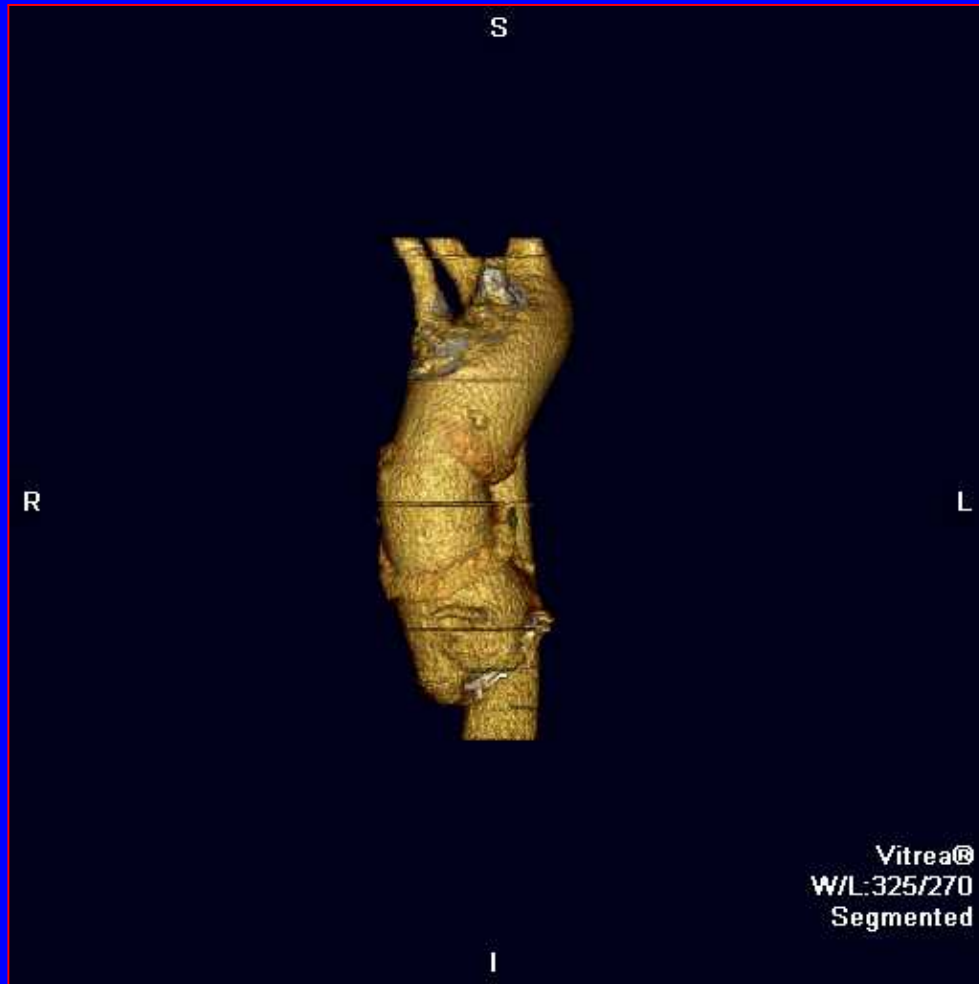
Detailed images, wide-angle views

Accuracy for endocarditis not established

# Diagnosis of Prosthetic Valve Endocarditis

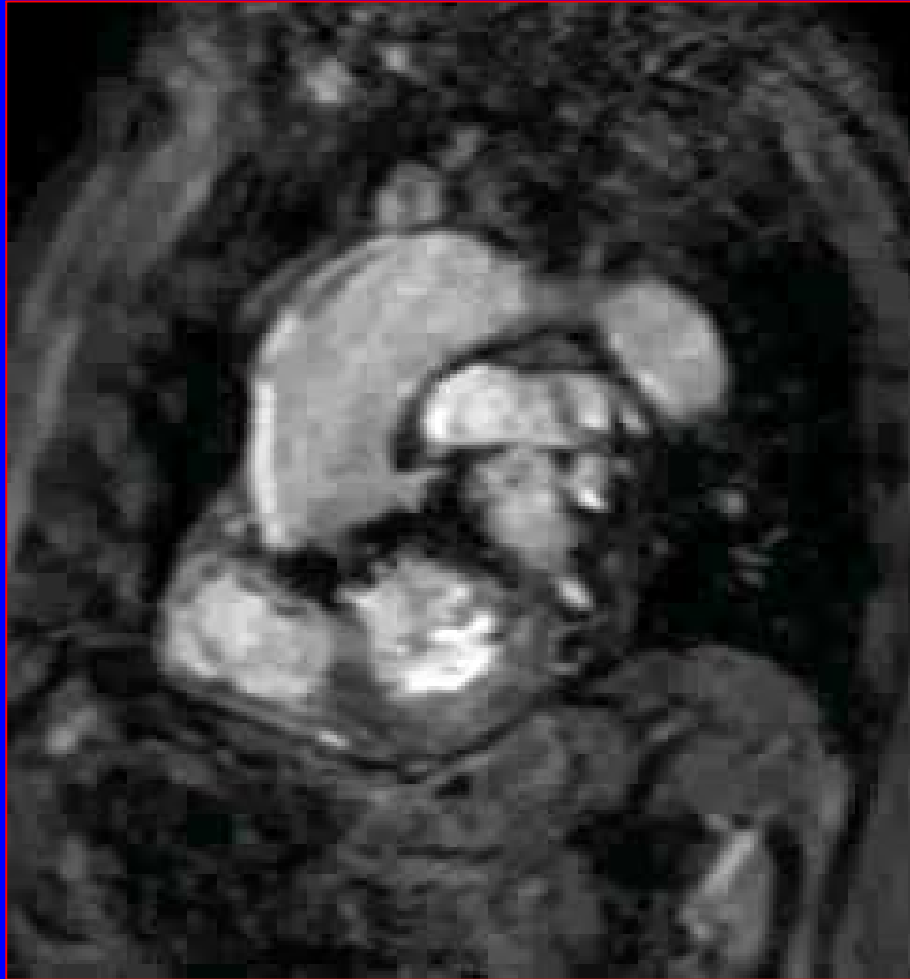## CT Imaging: 3D Imaging of Valves



Courtesy of Lee Mitsumori, MD

# Diagnosis of Prosthetic Valve Endocarditis

## MR Imaging: Flow visualization



Courtesy of Lee Mitsumori, MD

# Diagnosis of Prosthetic Valve Endocarditis

## *Aortic valve replacement*

### Operative findings:

Active endocarditis of tissue aortic valve

Replaced with 25 mm Medtronic Mosaic valve

### Pathology:

Chronic active endocarditis

Gram positive cocci (no growth on culture)

PCR positive for *Bartonella henselae* DNA  
(16s rDNA, ribC and ITS primer sets)

### Treatment:

4 wks IV antibiotics post-op  
(azithromycin + ceftriaxone)

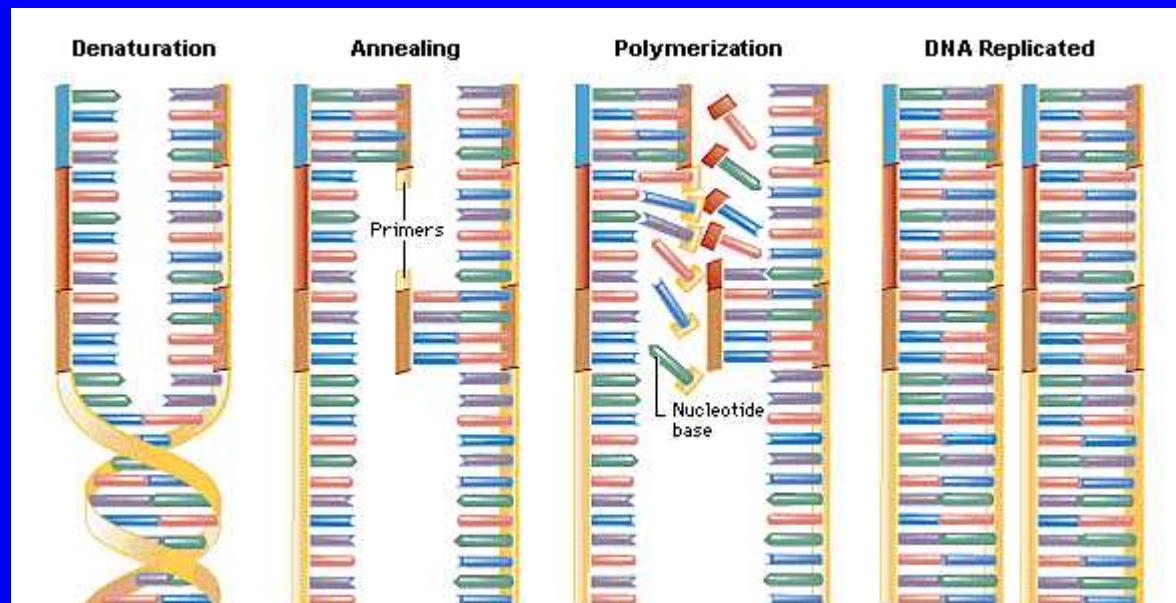
# Diagnosis of Prosthetic Valve Endocarditis

## Molecular identification of bacteria in tissue

### Polymerase Chain Reaction

Broad range PCR  
targets common shared bacterial 16S rRNA genes  
(via pan-bacterial primers)

Followed by  
direct sequencing  
to identify  
specific organism



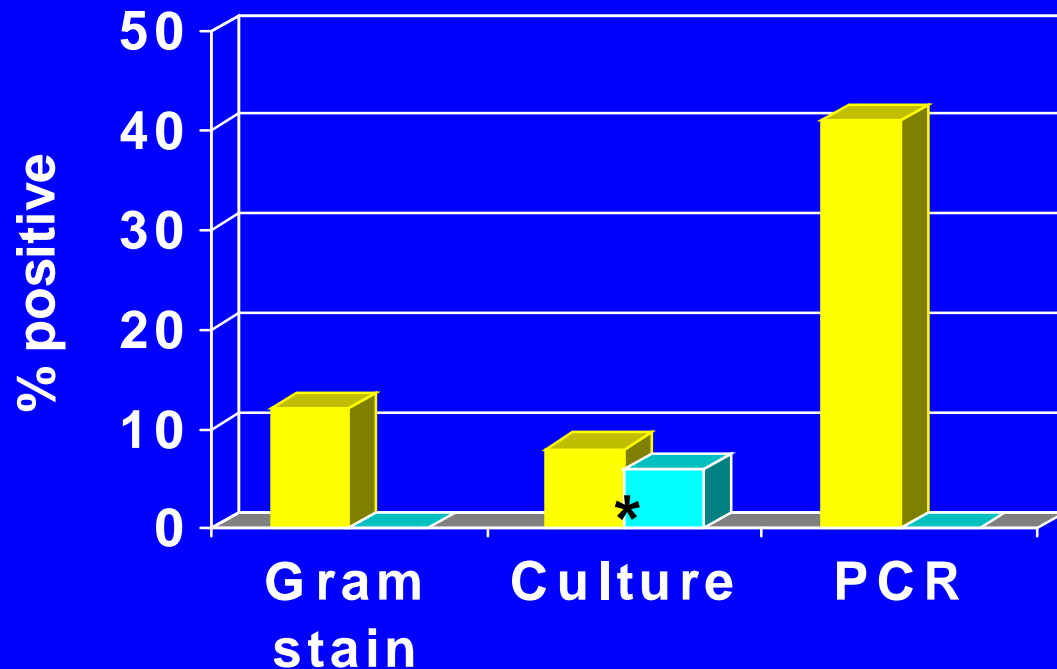
[Encarta.com](http://Encarta.com)

# Diagnosis of Prosthetic Valve Endocarditis

## PCR of valve tissue

N = 52 excised heart valves with suspected endocarditis (compared to 16 normal valves)

■ Suspected IE  
■ Controls



### Organisms

*Staph*

*Strep sp*

*Enterococcus*

*Propionibacterium acnes*

*Nocardia paucivorans*

*Bartonella quintana*

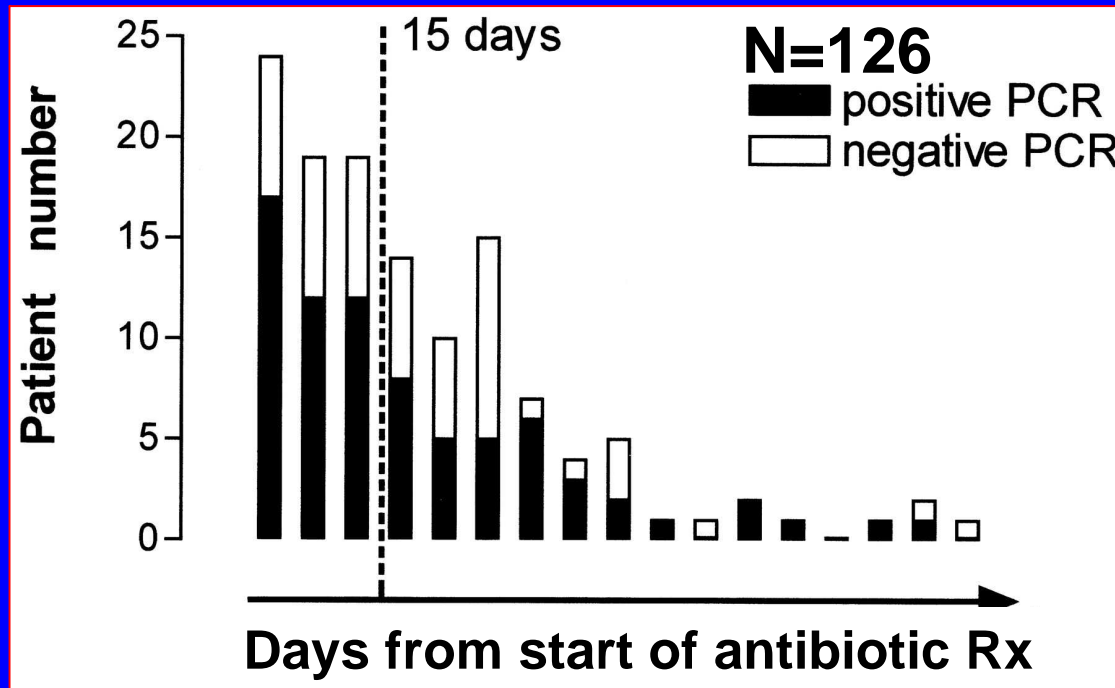
\* possible contamination by molds

Breitkopf C et al, Circulation 2005

# Diagnosis of Prosthetic Valve Endocarditis PCR in pts with treated endocarditis

+PCR in 76/126 (60%) on antibiotics

+PCR in 11/30 (37%) with completed antibiotic Rx



**Positive PCR can persist yrs after Rx**

Staph pneum. 7 yrs

S. bovis 2 yrs

Enterococcus 2 yrs

Bartonella 1 yr

S. sanguinis 2 yrs

Roverly C et al, J Clin Micro 2005

# Diagnosis of Prosthetic Valve Endocarditis

## PCR for diagnosis of endocarditis

*New strategies are needed to improve sensitivity and specificity :*

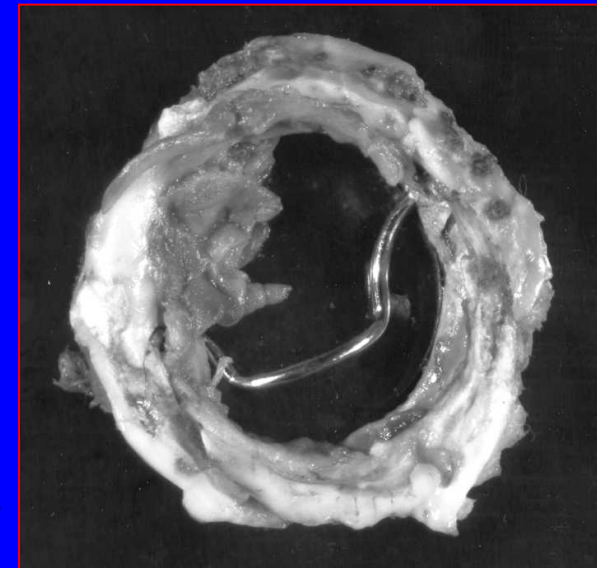
- **Sample acquisition – cleaner techniques**
- **DNA extraction – reduction of background bacterial DNA**
- **PCR reaction – use of long-range DNA polymerases**
- **Type of sample – application to blood**

**Rice PA and Madico GE, Circulation 2005 (editorial)**

# Diagnosis of Prosthetic Valve Endocarditis

## Conclusions

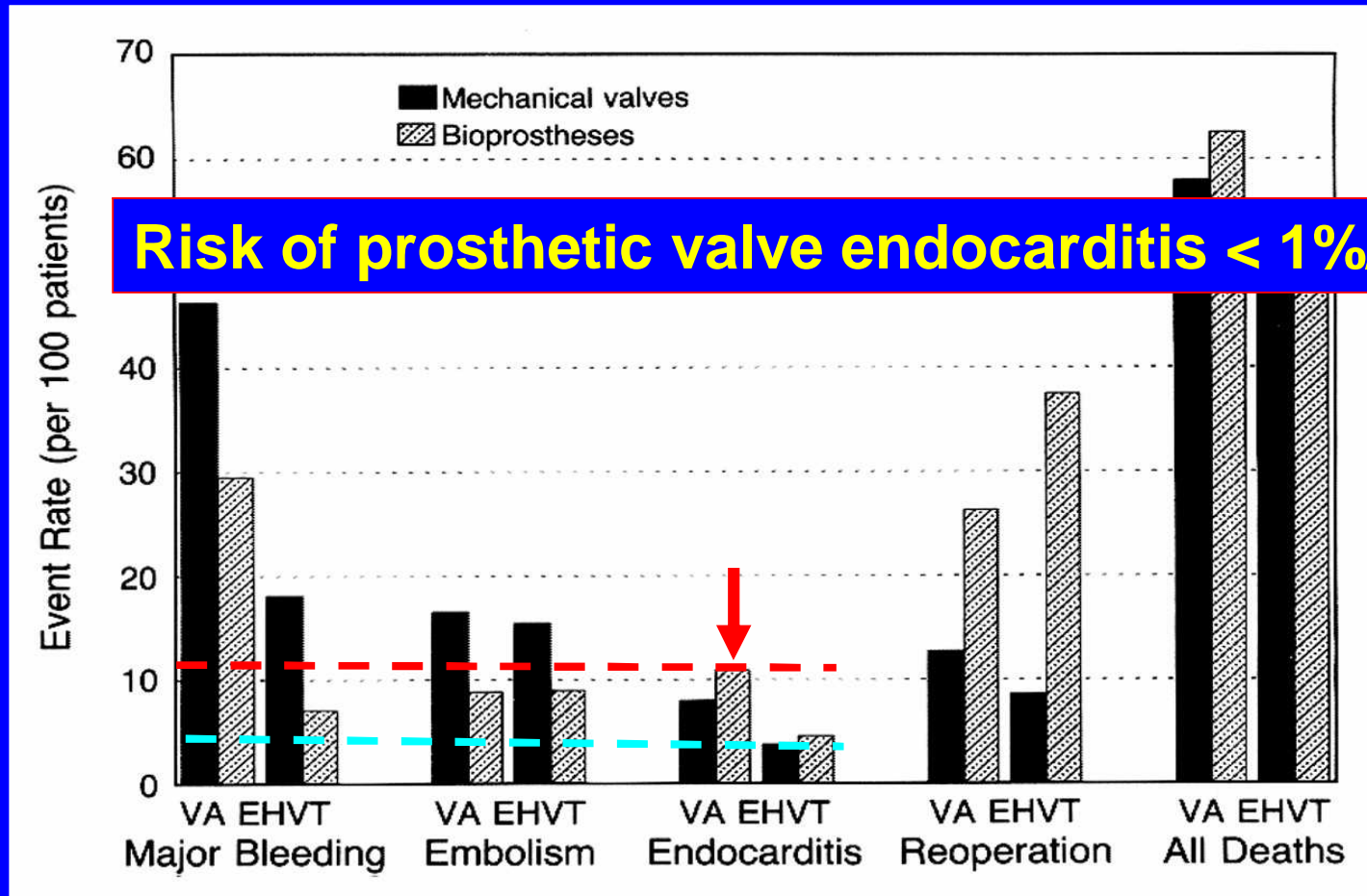
- High index of suspicion
- Patient education
- Start with Duke criteria
- Hold blood cultures for 4-6 wks
- TEE early in disease course
- Re-evaluate if symptoms persist
- New molecular techniques have promise





# Diagnosis of Prosthetic Valve Endocarditis

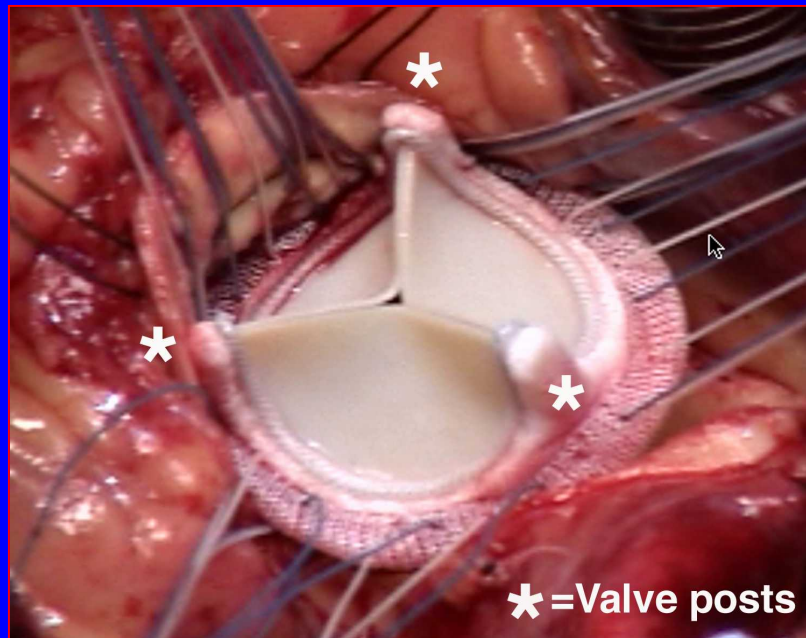
## Risk of Infection



Hammermeister KE et al, NEJM 1993 (12 yr event rates)

# Are We Managing Prosthetic Valve Endocarditis Correctly ?

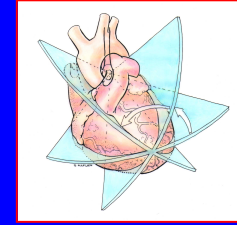
## The Best Approach to Diagnosis



**Catherine M. Otto, MD**  
**Professor of Medicine**  
**University of Washington**

# Diagnosis of Prosthetic Valve Endocarditis

## Duke Major Criteria



### ***Positive blood cultures***

Typical microorganisms from 2 separate BCs  
Persistently positive BCs

### ***Evidence of endocardial involvement***

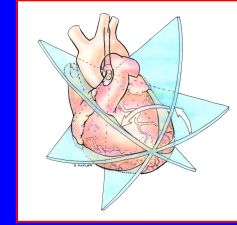
Positive echo for endocarditis

- Vegetation
- Abscess
- Prosthetic valve dehiscence

**New valvular regurgitation**

# Diagnosis of Prosthetic Valve Endocarditis

## Duke Minor Criteria



- ***Predisposing Condition***
- ***Fever > 38° C***
- ***Vascular phenomenon***  
(arterial emboli, pulmonary infarct, mycotic aneurysm, etc)
- ***Immunologic phenomenon***  
(glomerulonephritis, Osler's nodes, etc)
- ***Other microbiologic evidence***

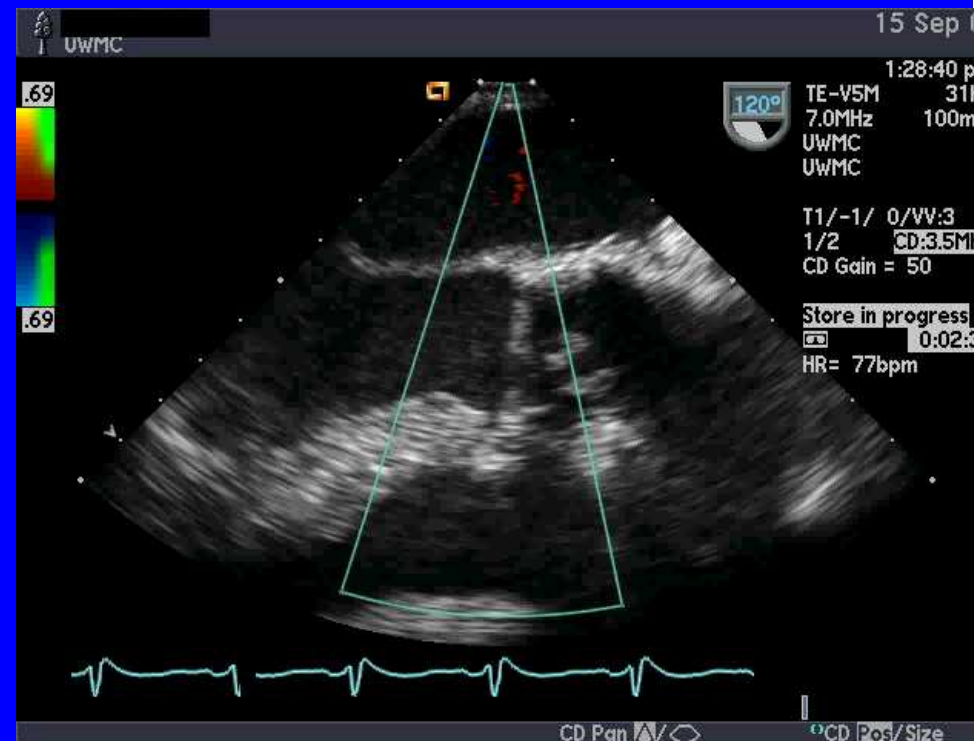
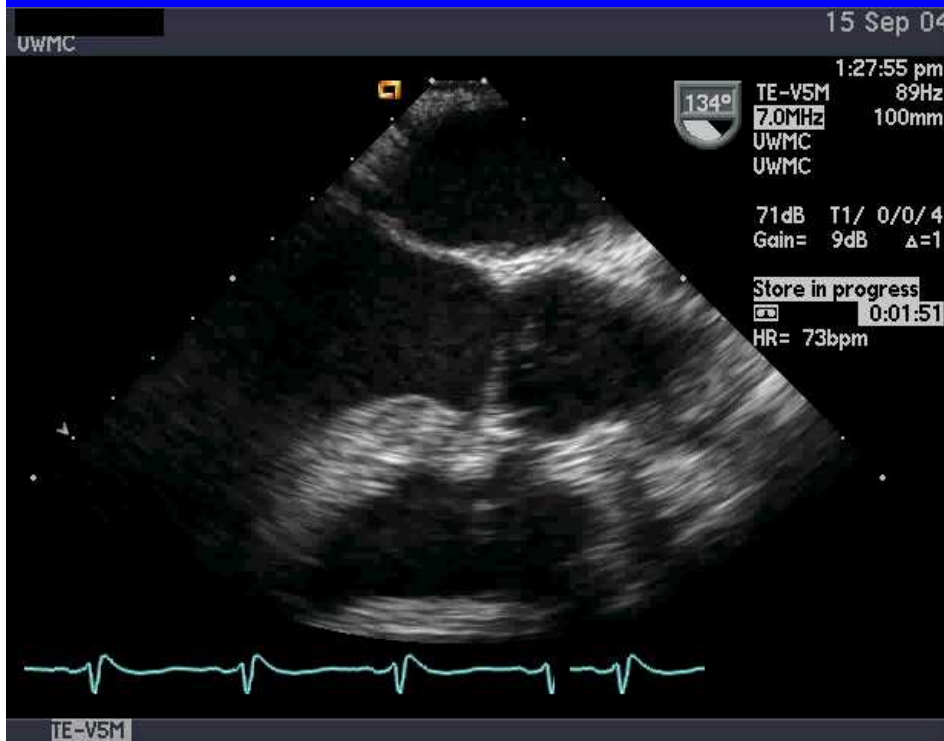
# Diagnosis of Prosthetic Valve Endocarditis

## 52 physician with prosthetic AVR

- Tissue AVR for severe AR 4 yrs ago
- Chronic nonproductive cough for 1 year
- Mediastinal lymphadenopathy (reactive)
- Splenic infarct 10 mo. ago (started on warfarin)
- Low grade fever starting 8 mo. ago (self medicated with oral antibiotics)
- Increasing fatigue and exertional dyspnea
- Blood cultures negative

# Diagnosis of Prosthetic Valve Endocarditis

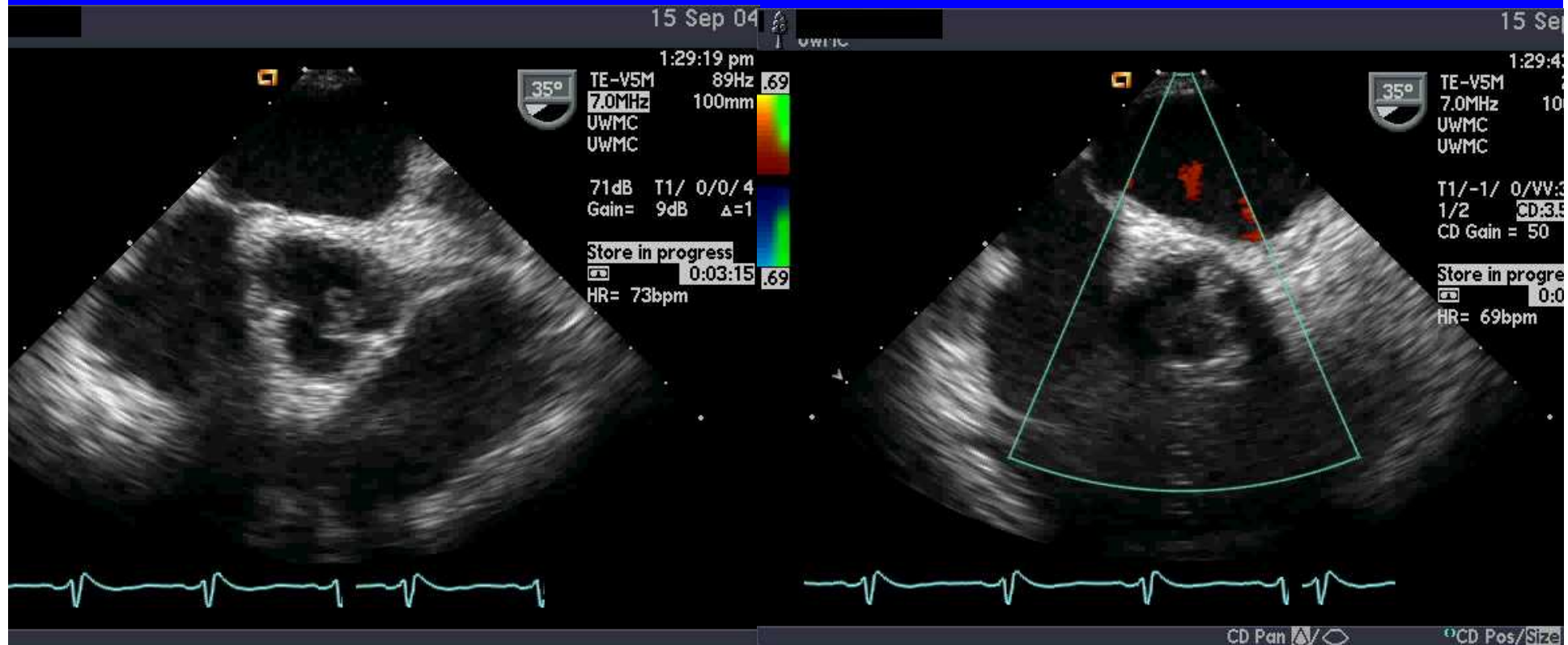
## 52 physician with prosthetic AVR



Also had a history of closed VSD and PDA

# Diagnosis of Prosthetic Valve Endocarditis

## 52 physician with prosthetic AVR



**Tissue AVR, leaflet redundancy**  
**No vegetation or regurgitation**

# Diagnosis of Prosthetic Valve Endocarditis

## 52 physician with prosthetic AVR

- TIA symptoms 3 months ago despite warfarin  
Multiple lesions on head CT  
Concern for metastatic disease
- Non-ST elevation myocardial infarction 3 mo. ago
- New CHF with EF 28%
- Now presents with chest pain

# Diagnosis of Prosthetic Valve Endocarditis

## 52 physician with chest pain

### *Physical Exam:*

T 37.3 °C

BP 104/70 HR 98

Neck: No JVD, Carotids normal

Chest: Clear, RR 16, SaO<sub>2</sub> 98%

Cardiac: No murmur

Abdomen: Benign

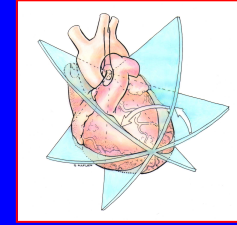
Ext: No cyanosis, clubbing, edema

Skin: No lesions

Neuro: Intact

# Diagnosis of Prosthetic Valve Endocarditis

## Duke Criteria



### ***Definite Endocarditis***

**2 major**

**1 major + 3 minor**

**5 minor**

### ***Probable Endocarditis***

**1 major + 1 minor**

**3 minor**

**Pt with prosthetic valve  
and history of fever and  
embolic events**

**Already has  
3 minor criteria  
for endocarditis ?**

# Diagnosis of Prosthetic Valve Endocarditis

## Clinical Features

<b>Fever</b>	<b>95%</b>
<b>New murmur or <math>\Delta</math> murmur</b>	<b>10- 25%</b>
<b>Pre-existing murmur</b>	<b>85- 95%</b>
<b>Osler's nodes</b>	<b>10-15%</b>
<b>Janeway lesions</b>	<b>3- 5%</b>
<b>Roth spots</b>	<b>2-10%</b>
<b>Anemia</b>	<b>70-90%</b>
<b>Circulating immune complexes</b>	<b>95%</b>
<b>Elevated CRP, RF</b>	<b>94-97%</b>
<b>Microscopic hematuria</b>	<b>30-60%</b>

# Diagnosis of Prosthetic Valve Endocarditis

## 52 physician with chest pain

### ***Labs:***

**WBC**            **16.3 (reactive lymphs)**

**Hct**             **29**

**Troponin**    **5.5 (elevated)**

**Blood cultures: Negative**

**MRI head: Small lesions suggestive of CVAs**

**CXR: Cardiomegaly, no pulmonary findings**

# Diagnosis of Prosthetic Valve Endocarditis

## Bacteriology

### **Early (within 2 months)**

Staph aureus  
Staph epidermidis  
Gram negative bacilli

### **Late**

Strep viridans  
Staph aureus

**Culture negative in 5%**

### **Other**

HACEK group  
Fungi  
Coxiella (Q-fever)  
Brucella  
Bartonella  
Chlamydia

**Almost any organism  
can cause endocarditis**

# Diagnosis of Prosthetic Valve Endocarditis

## Bacteriologic diagnosis

### *Blood cultures*

- Minimum 3 over 24 hours (Dx from 1<sup>st</sup> 2 in 90%)
- Separate venipuncture sites
- Minimum of 10 mL per culture (in adults)
- Start Rx (if possible) after cultures over 24 hrs
- If Rx cannot be delayed, 3 cultures over 1 hr

# Diagnosis of Prosthetic Valve Endocarditis

## Bacteriologic diagnosis

### *Problems*

- Preceding antibiotic Rx
- Culture negative in 3-4% of cases (50% of fungal)
- Some organisms difficult to isolate
- Prolonged incubation
  - Extended incubation or 4-6 wks (e.g. for HACEK)
- Special media or microbiologic method
  - Antigen (Aspergillus, Legionella)
  - Serology (Q-fever/Coxiella, Bartonella, Chlamydia)

# Diagnosis of Prosthetic Valve Endocarditis

## 52 physician with chest pain

### *Hospital Course:*

- CHF with EF 11%, Rx with dobutamine
- Coronary angiography r
- Recurrent fevers
- Wide complex tachycard
- Progressive acidosis
- Exploratory laparotomy (negative for bowel ischemia)

**Negative blood cultures**  
17 sets over 2 wks  
Bacterial, fungal, AFB  
Aerobic and anerobic  
Extended incubation

# Diagnosis of Prosthetic Valve Endocarditis

## Transthoracic Echo

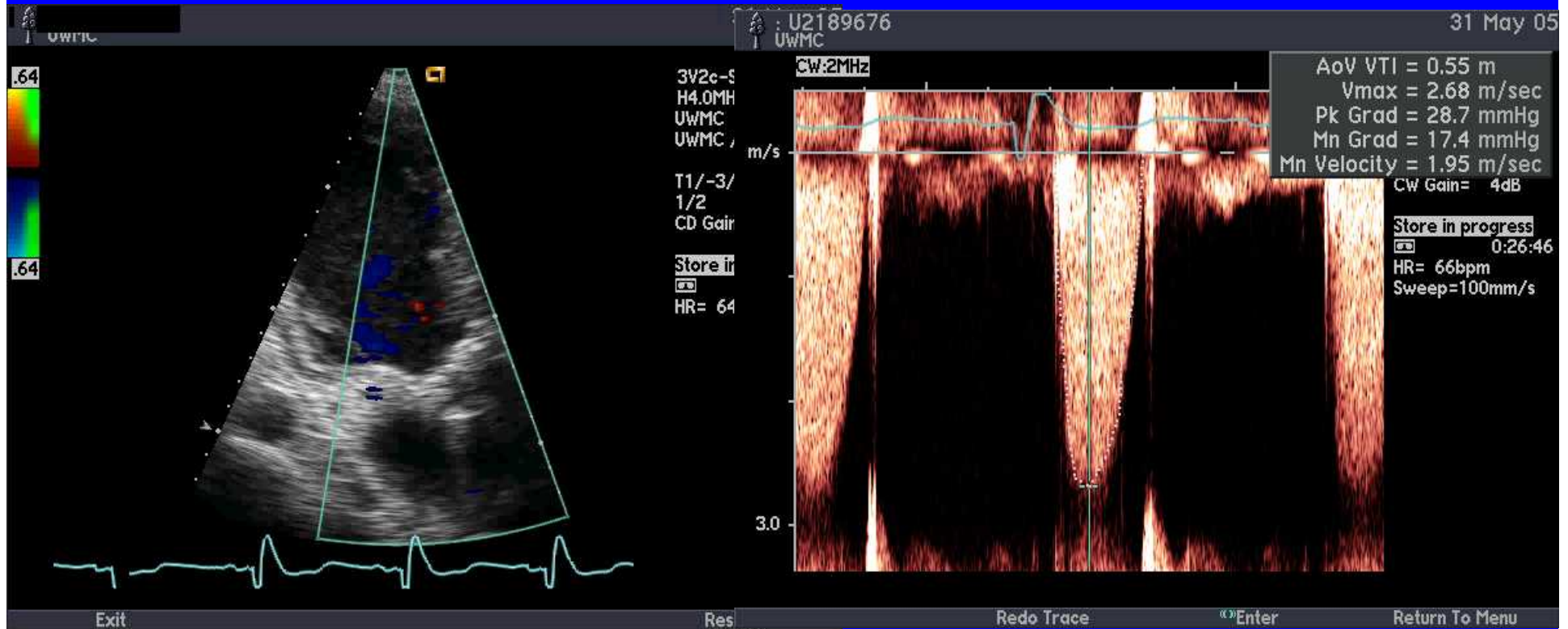


Poor parasternal images

?Thick leaflets from apex

# Diagnosis of Prosthetic Valve Endocarditis

## Transthoracic Echo

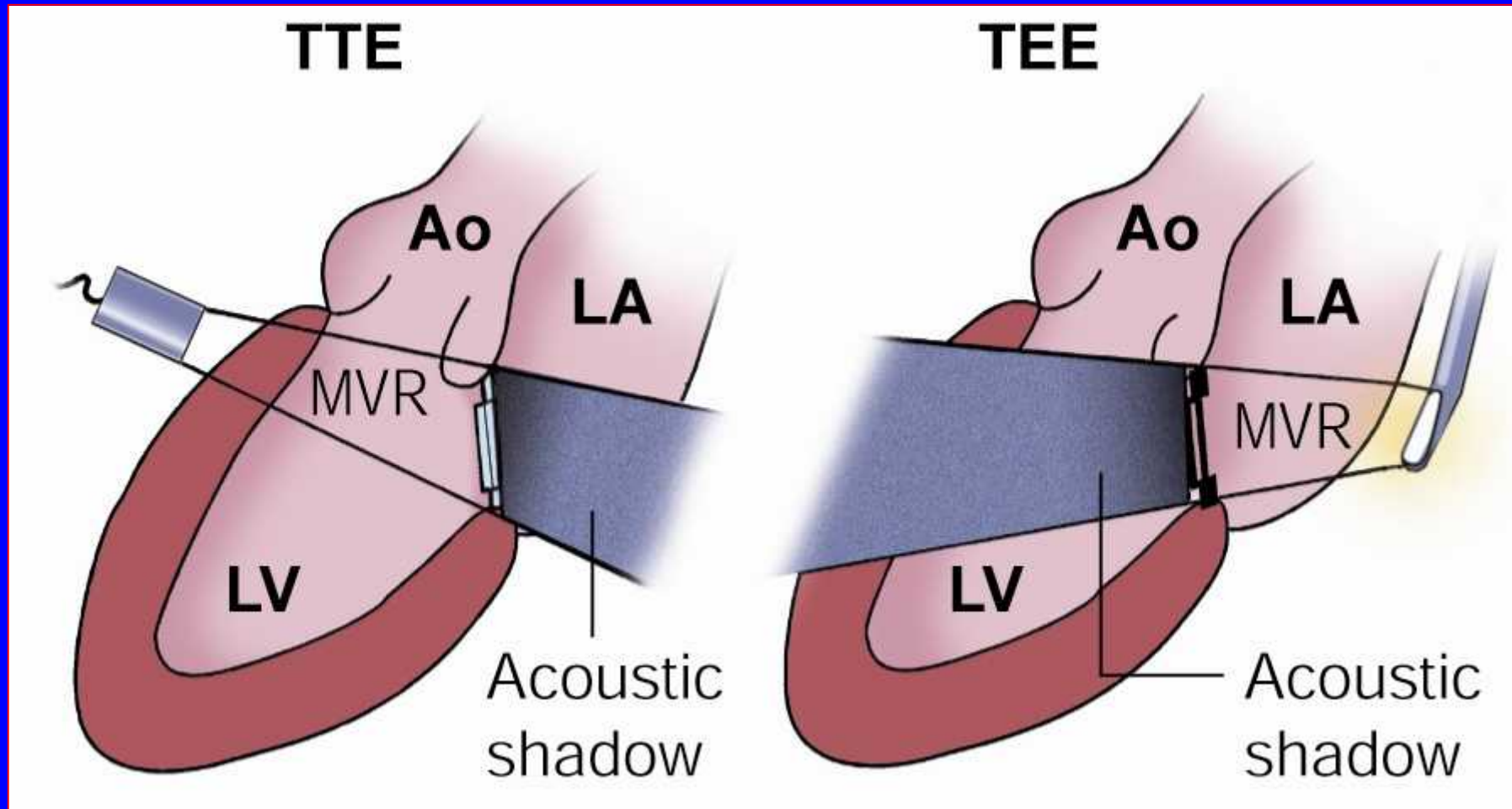


**No AR on color Doppler**

**Aortic jet 2.7 m/s on CWD**

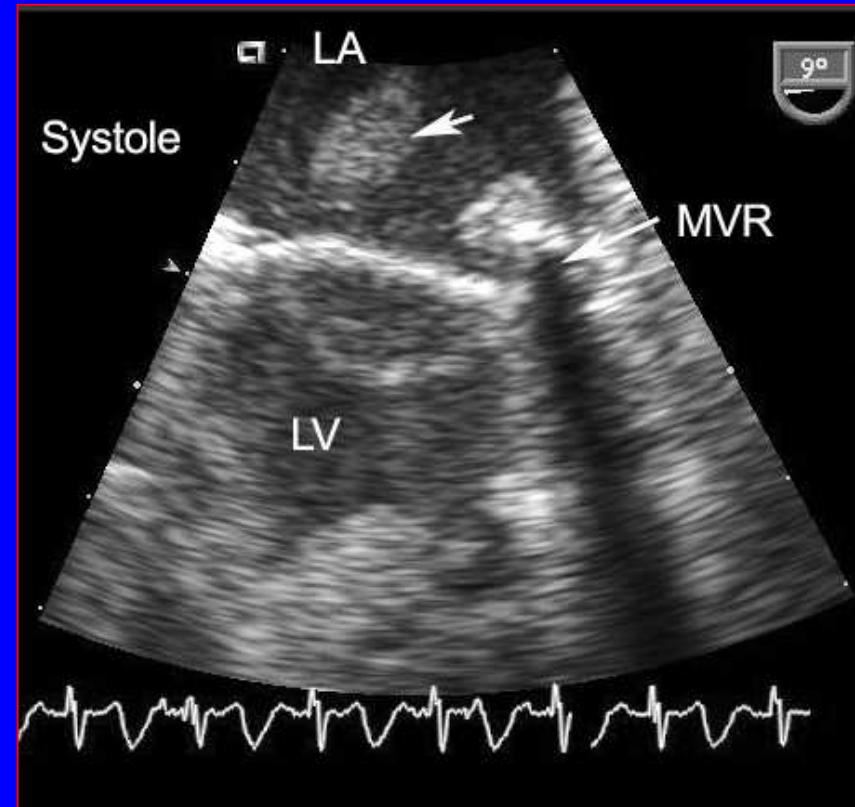
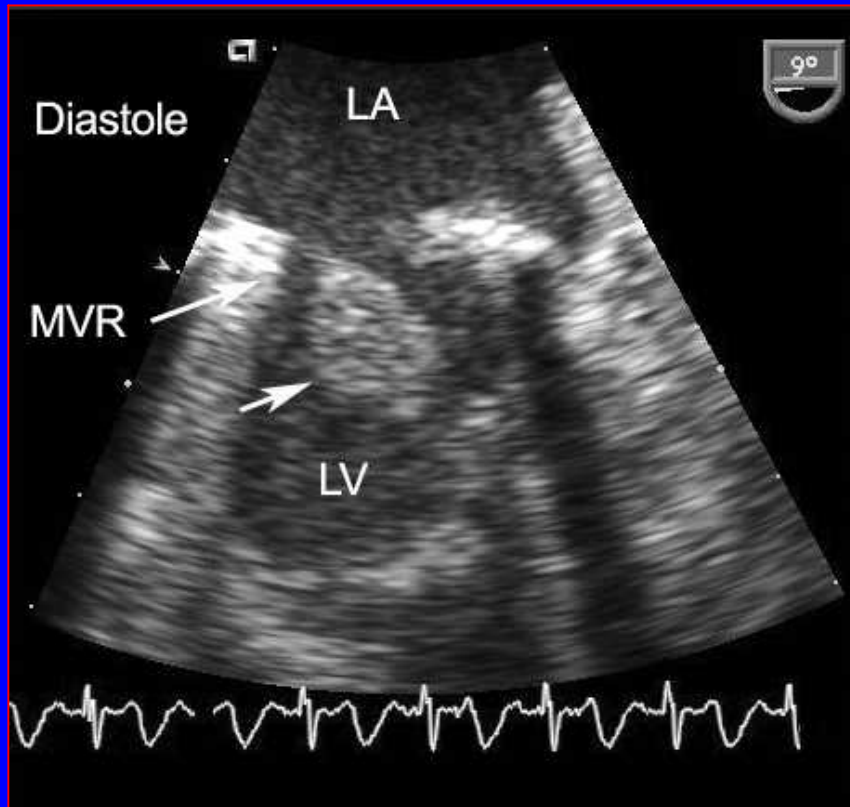
# Diagnosis of Prosthetic Valve Endocarditis

## Echocardiography



# Diagnosis of Prosthetic Valve Endocarditis

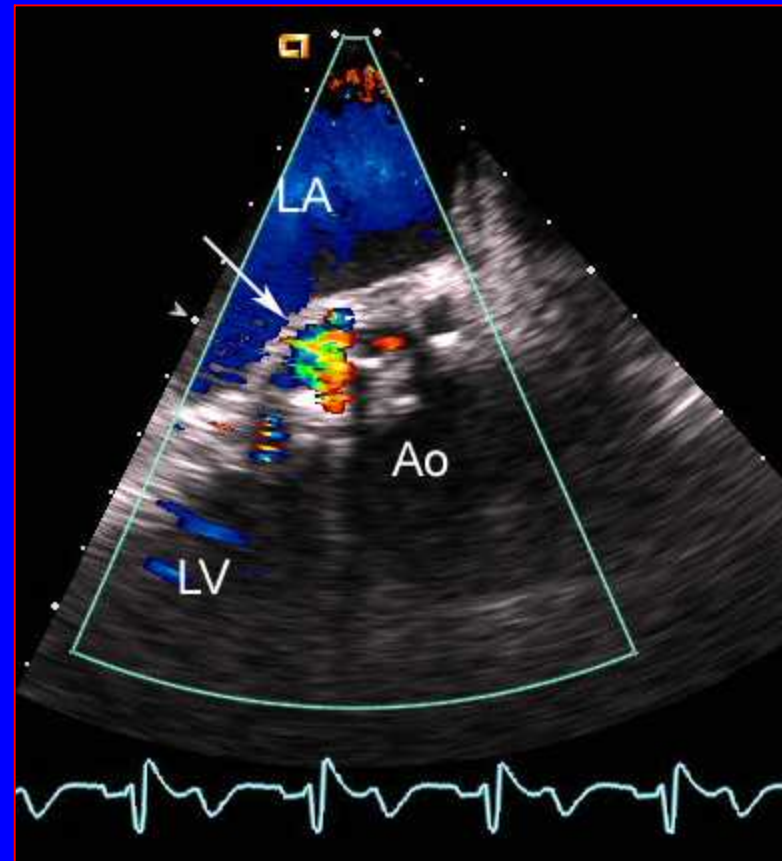
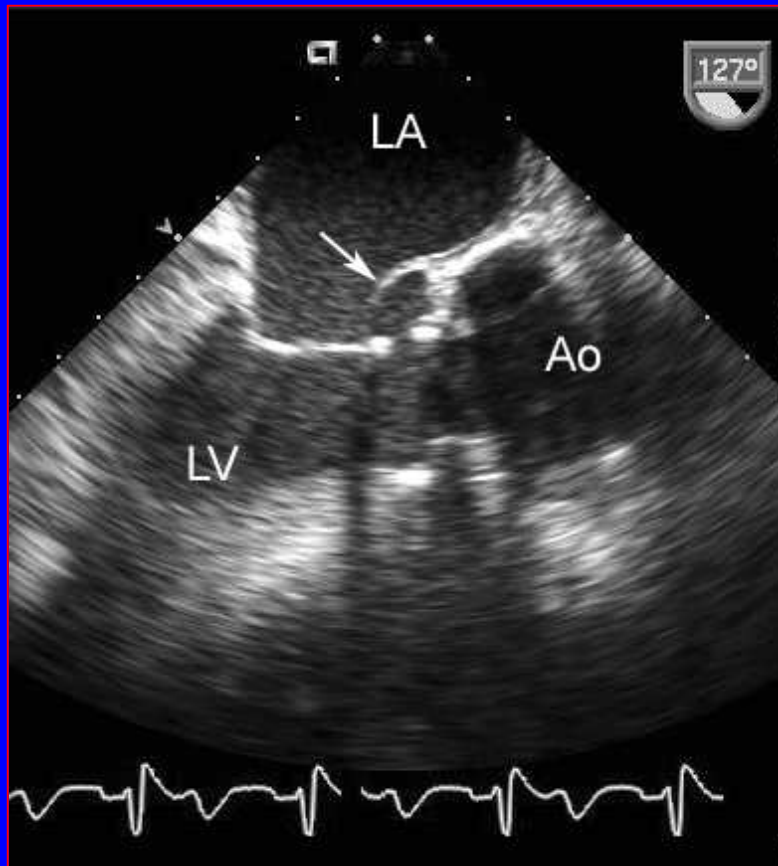
## TEE detection of Vegetations



**56F with Staph bacteremia and hypotension  
5 years after mechanical bileaflet MVR**

# Diagnosis of Prosthetic Valve Endocarditis

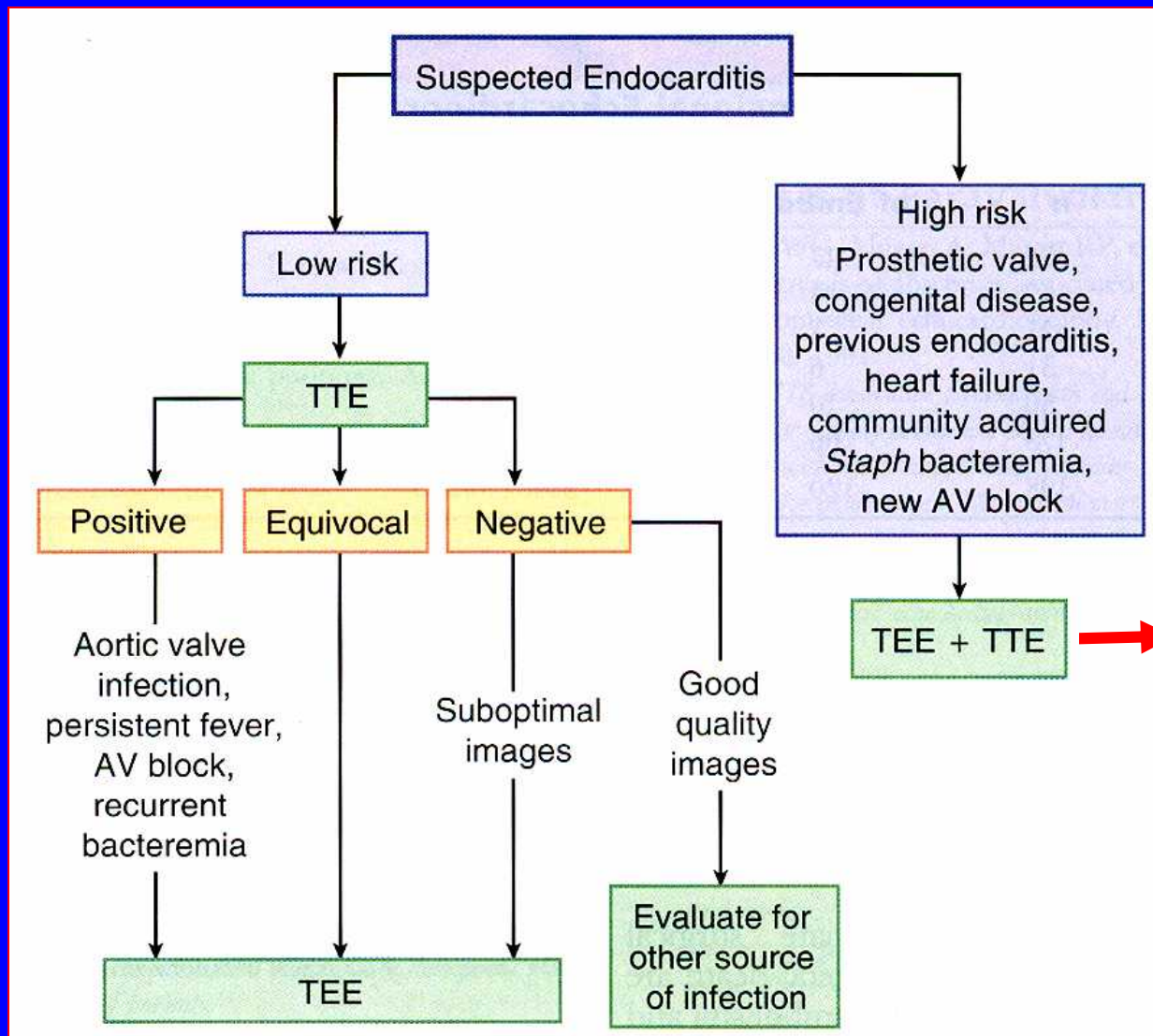
## TEE detection of abscess



**Persistent fevers after tissue AVR  
with aneurysm of aortic mitral intervalvular fibrosa**

# Diagnosis of Prosthetic Valve Endocarditis

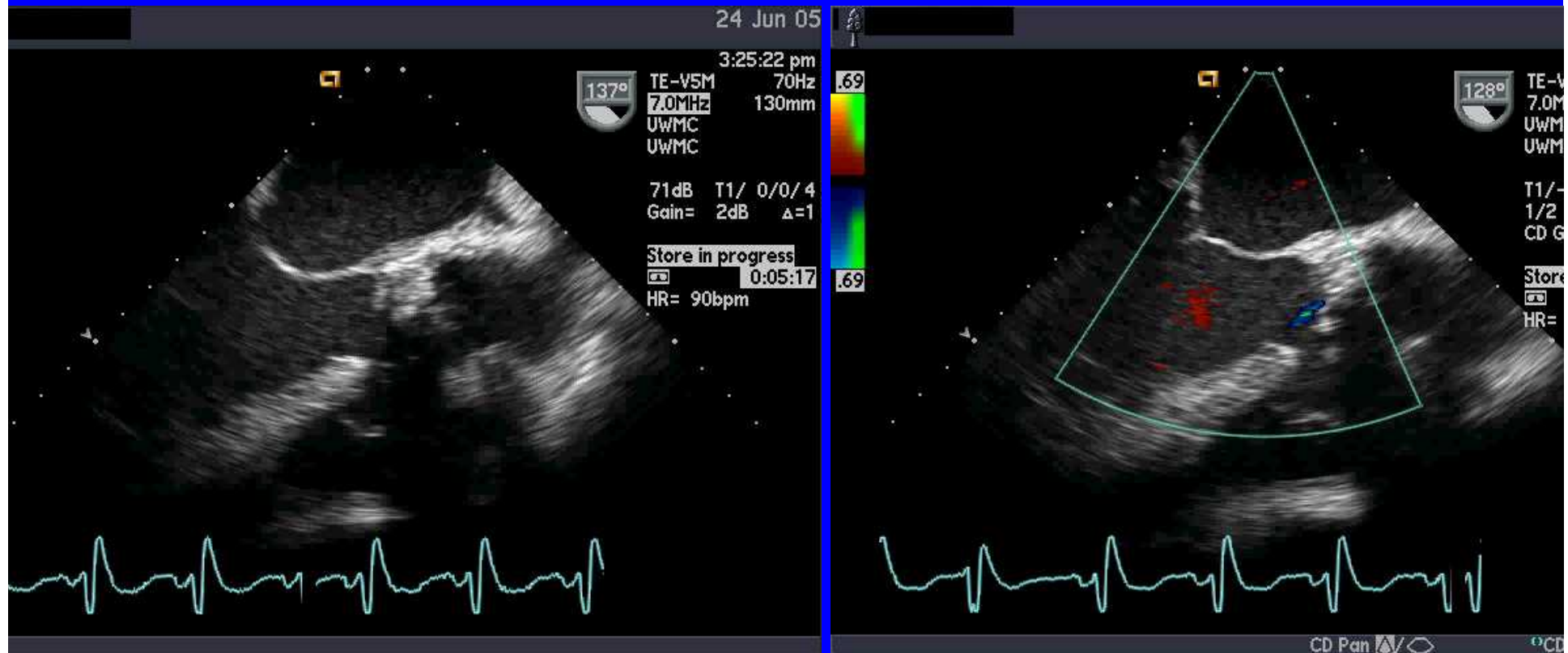
## Role of TEE – needed in ALL patients



**Also need TTE,  
esp. with AVR**

# Diagnosis of Prosthetic Valve Endocarditis

## 2<sup>nd</sup> TEE in 52M with AVR



**Marked leaflet thickening, still little AR**

# Diagnosis of Prosthetic Valve Endocarditis

## Echocardiography

266 cases  
127 definite endocarditis

### *Repeated exams*

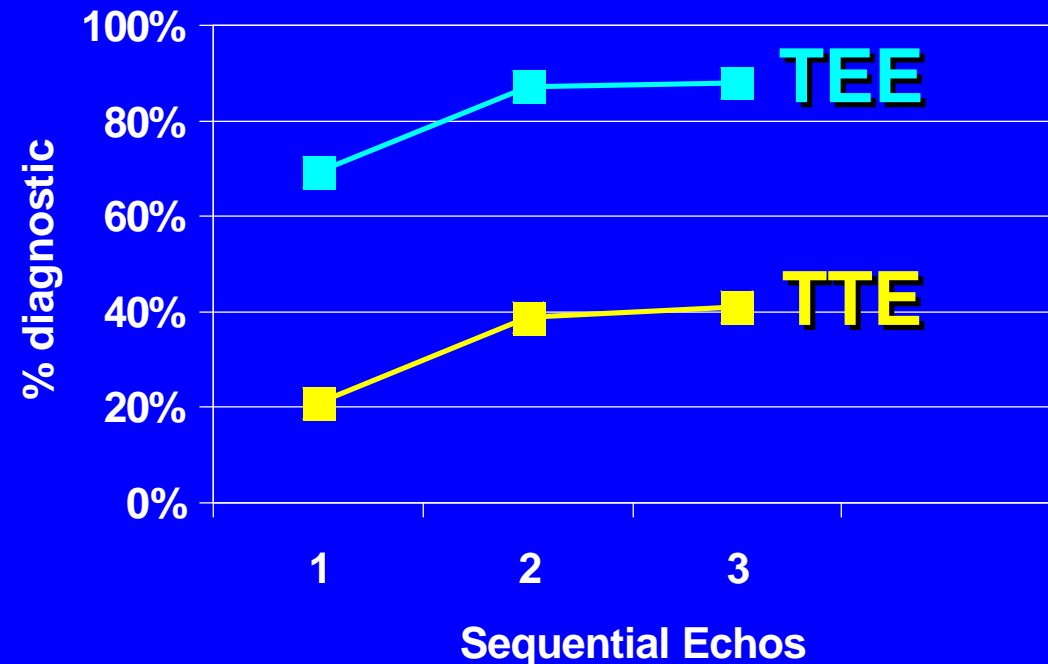
2.4 TTE (int. 7.4 days)

1.2 TEE (int. 12.4 days)

### *High risk group*

Prosthetic valves 55%

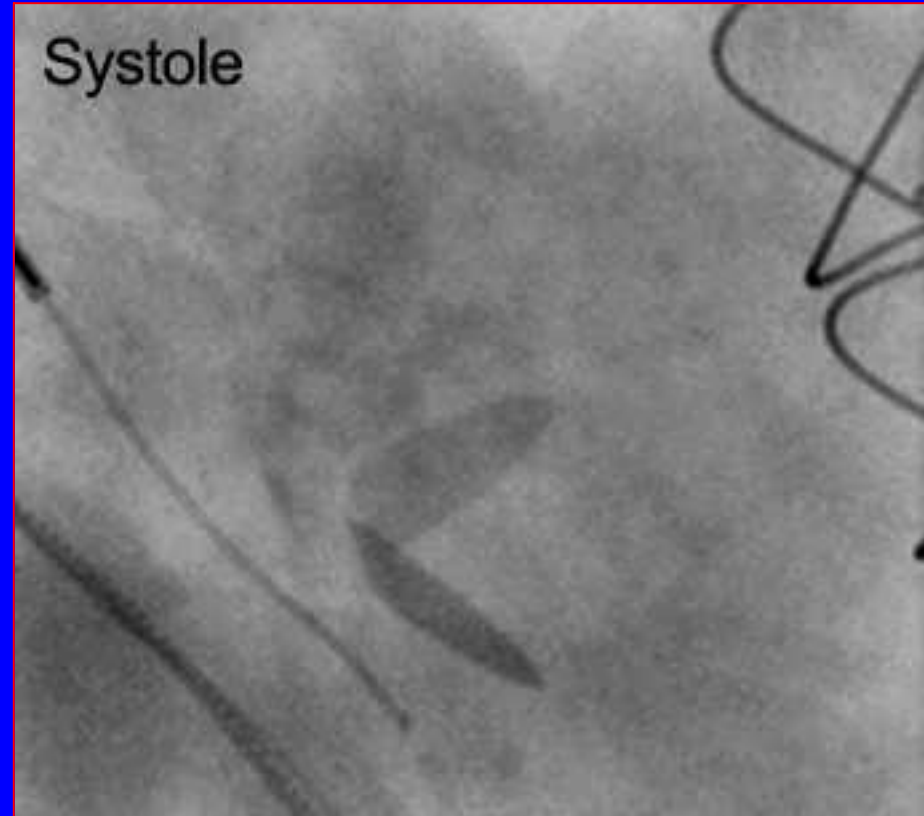
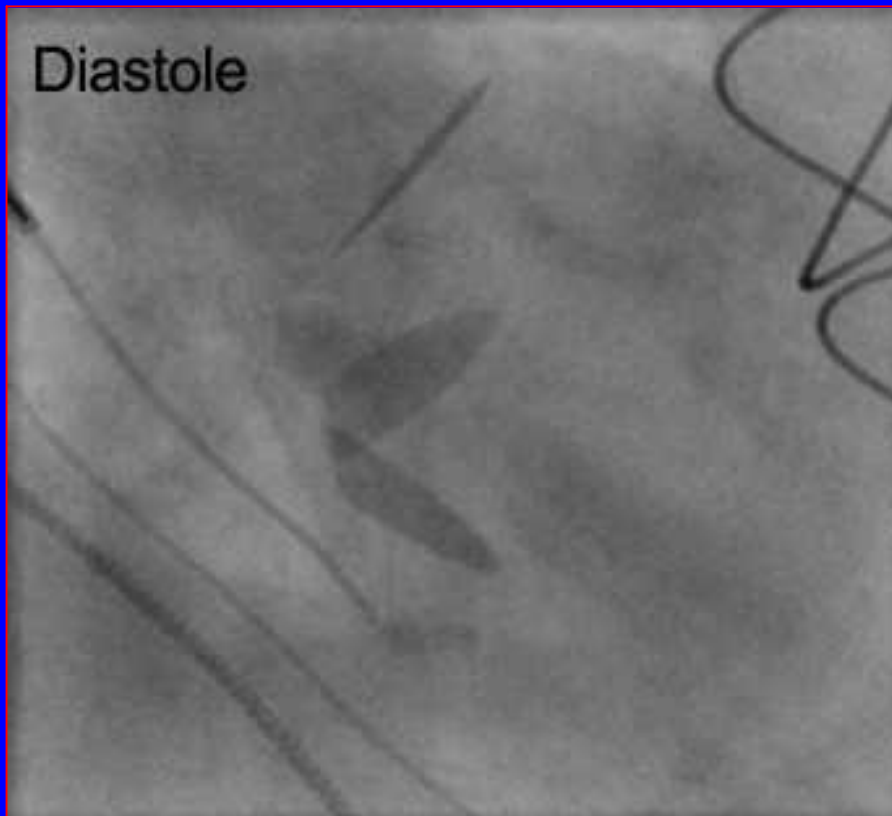
Culture negative 26%



Vieira et al, Heart 2004; 90: 1020

# Diagnosis of Prosthetic Valve Endocarditis

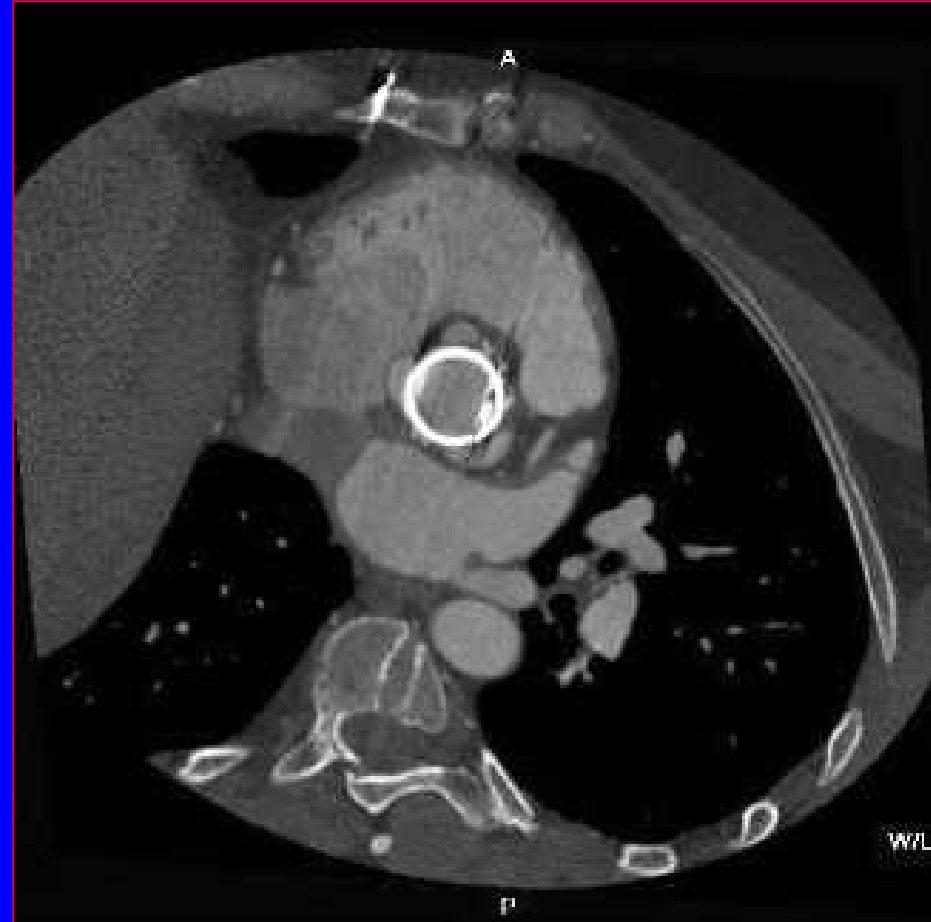
## Fluoroscopy – rarely helpful



**Shows leaflet motion, not vegetations**

# Diagnosis of Prosthetic Valve Endocarditis

## CT Imaging



Detailed images, wide-angle views

Accuracy for endocarditis not established

# Diagnosis of Prosthetic Valve Endocarditis

## CT Imaging: 3D Imaging of Valves



Courtesy of Lee Mitsumori, MD

# Diagnosis of Prosthetic Valve Endocarditis

## MR Imaging: Flow visualization



Courtesy of Lee Mitsumori, MD

# Diagnosis of Prosthetic Valve Endocarditis

## *Aortic valve replacement*

### Operative findings:

Active endocarditis of tissue aortic valve

Replaced with 25 mm Medtronic Mosaic valve

### Pathology:

Chronic active endocarditis

Gram positive cocci (no growth on culture)

PCR positive for *Bartonella henselae* DNA  
(16s rDNA, ribC and ITS primer sets)

### Treatment:

4 wks IV antibiotics post-op  
(azithromycin + ceftriaxone)

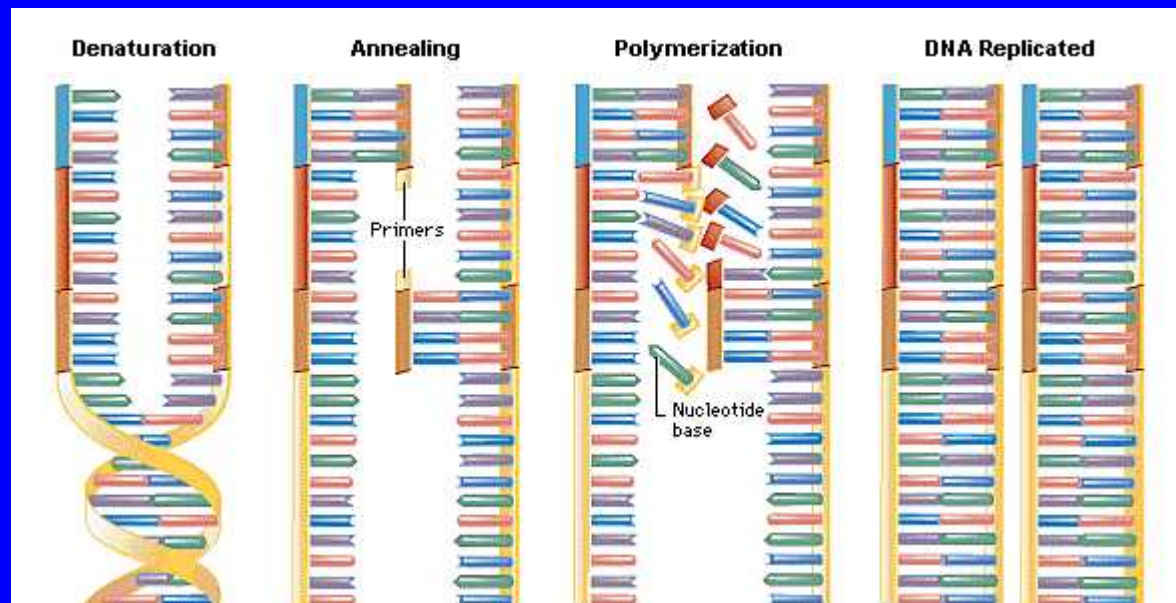
# Diagnosis of Prosthetic Valve Endocarditis

## Molecular identification of bacteria in tissue

### Polymerase Chain Reaction

Broad range PCR  
targets common shared bacterial 16S rRNA genes  
(via pan-bacterial primers)

Followed by  
direct sequencing  
to identify  
specific organism

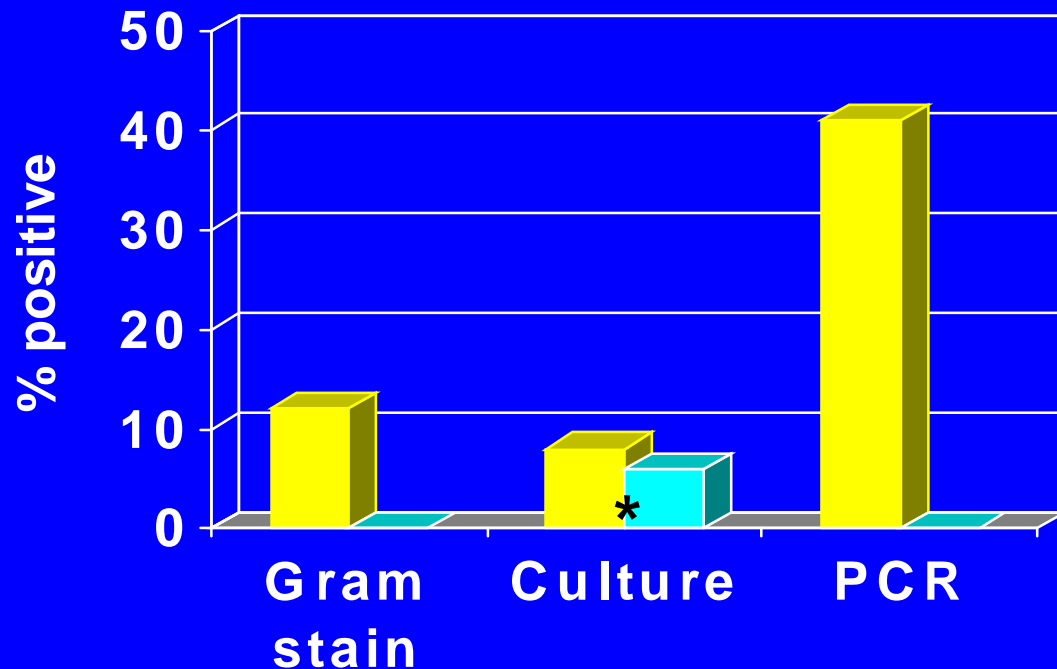
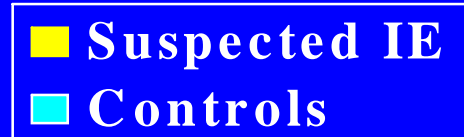

[Encarta.com](http://Encarta.com)

# Diagnosis of Prosthetic Valve Endocarditis

## PCR of valve tissue

N = 52 excised heart valves with suspected endocarditis (compared to 16 normal valves)



### Organisms

*Staph*

*Strep sp*

*Enterococcus*

*Propionibacterium acnes*

*Nocardia paucivorans*

*Bartonella quintana*

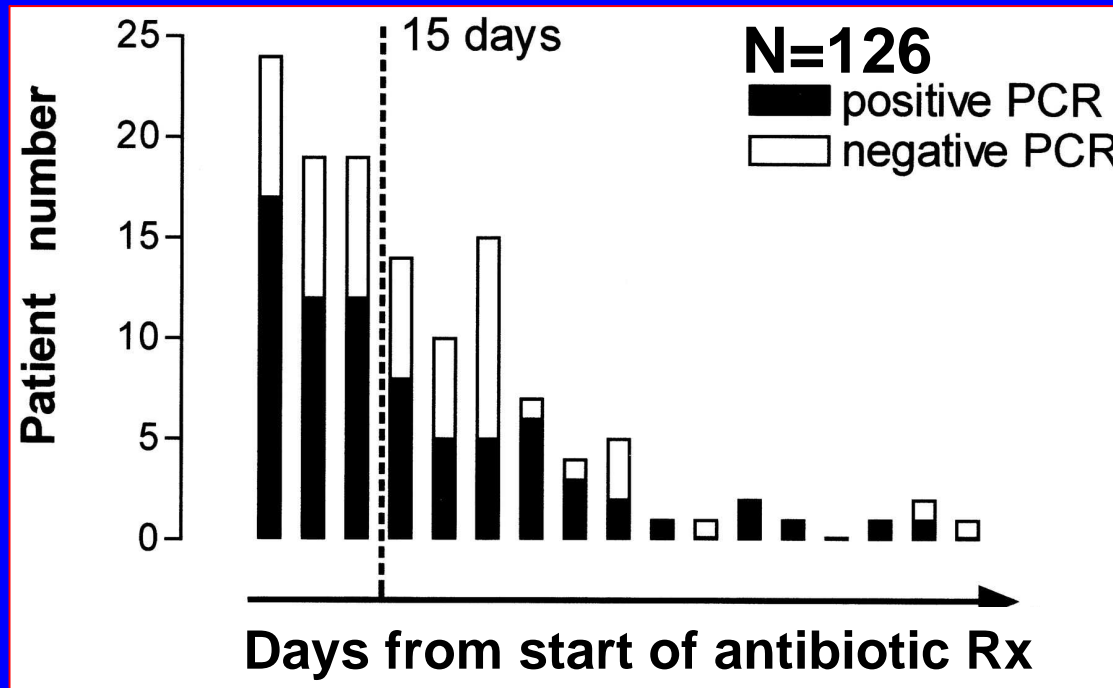
\* possible contamination by molds

Breitkopf C et al, Circulation 2005

# Diagnosis of Prosthetic Valve Endocarditis PCR in pts with treated endocarditis

+PCR in 76/126 (60%) on antibiotics

+PCR in 11/30 (37%) with completed antibiotic Rx



**Positive PCR can persist yrs after Rx**

Staph pneum. 7 yrs

S. bovis 2 yrs

Enterococcus 2 yrs

Bartonella 1 yr

S. sanguinis 2 yrs

Roverly C et al, J Clin Micro 2005

# Diagnosis of Prosthetic Valve Endocarditis

## PCR for diagnosis of endocarditis

*New strategies are needed to improve sensitivity and specificity :*

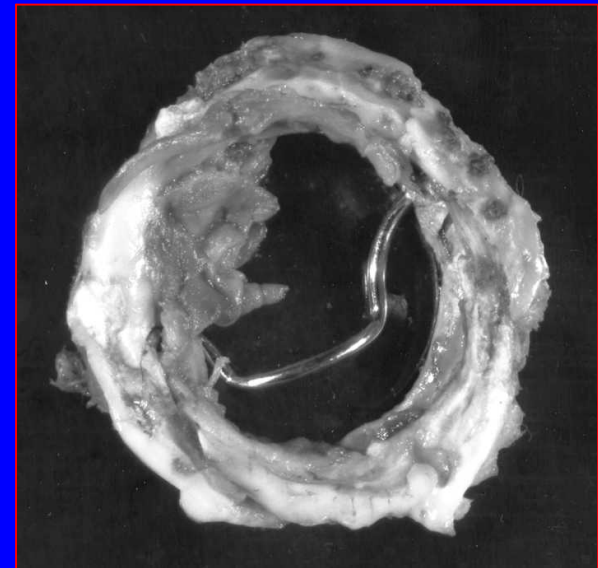
- **Sample acquisition – cleaner techniques**
- **DNA extraction – reduction of background bacterial DNA**
- **PCR reaction – use of long-range DNA polymerases**
- **Type of sample – application to blood**

**Rice PA and Madico GE, Circulation 2005 (editorial)**

# Diagnosis of Prosthetic Valve Endocarditis

## Conclusions

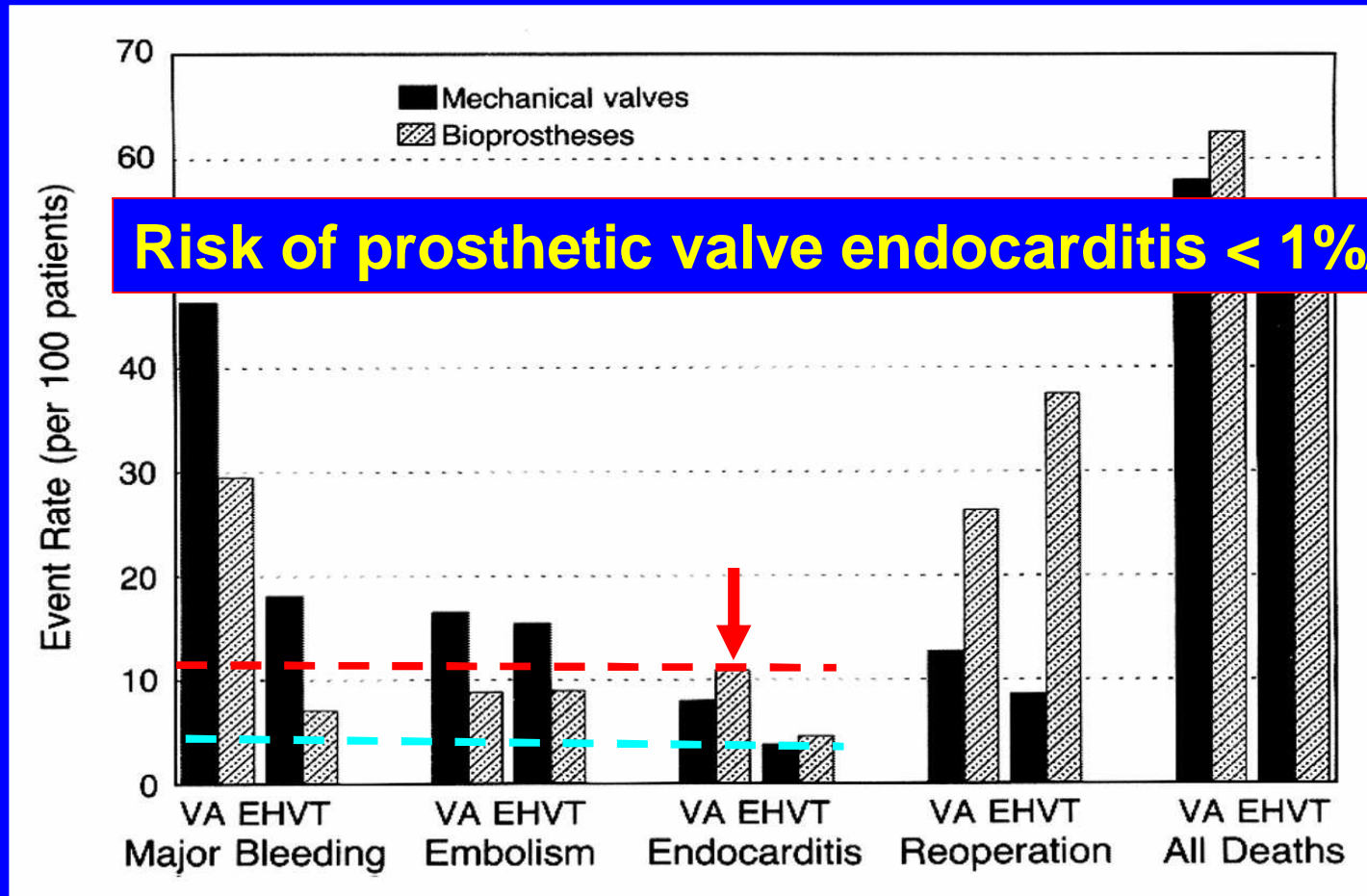
- High index of suspicion
- Patient education
- Start with Duke criteria
- Hold blood cultures for 4-6 wks
- TEE early in disease course
- Re-evaluate if symptoms persist
- New molecular techniques have promise





# Diagnosis of Prosthetic Valve Endocarditis

## Risk of Infection



Hammermeister KE et al, NEJM 1993 (12 yr event rates)