

**EHRA EDUCATIONAL SLIDES**

***Aortic cusp as origin of  
tachycardia***

**Sabine Ernst, MD**

---

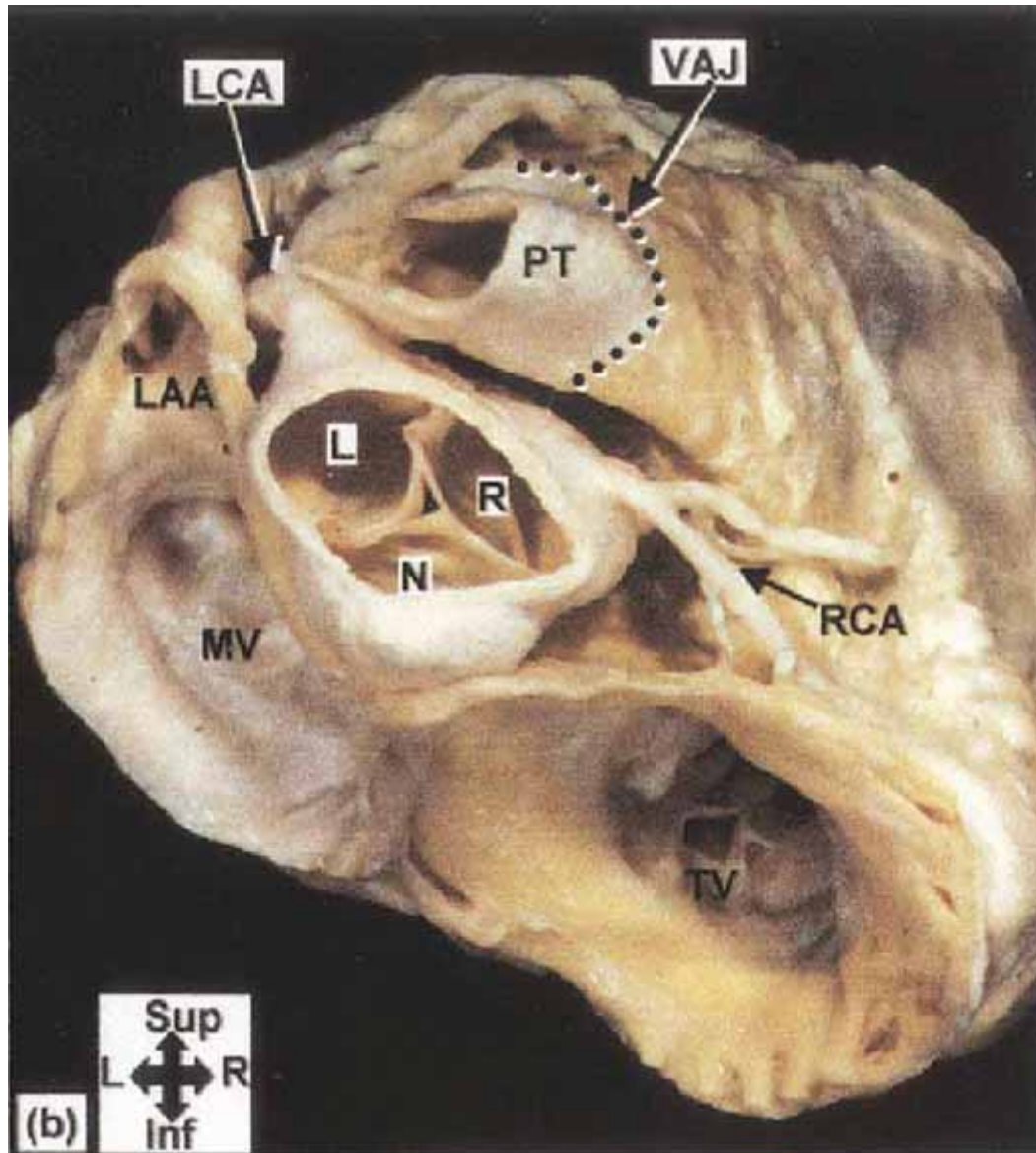
**EHRA educational slides**  
**S. Ernst**



# Aortic cusp as origin of tachycardia

## Aortic cusp

- Anatomical relationship
- Ventricular extrasystoles/tachycardia
  - DD from the surface ECG
  - Mapping considerations
  - Ablation considerations
- Supraventricular tachycardia

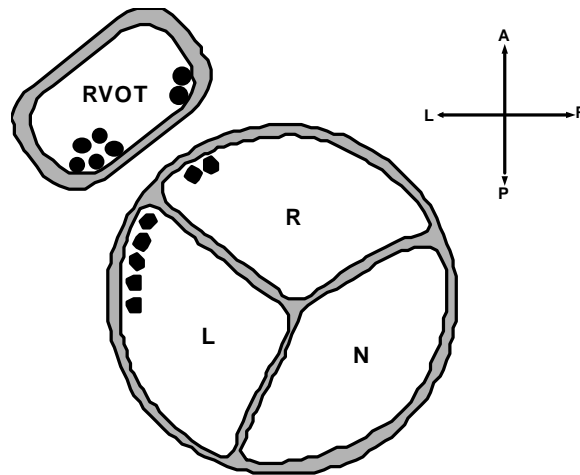
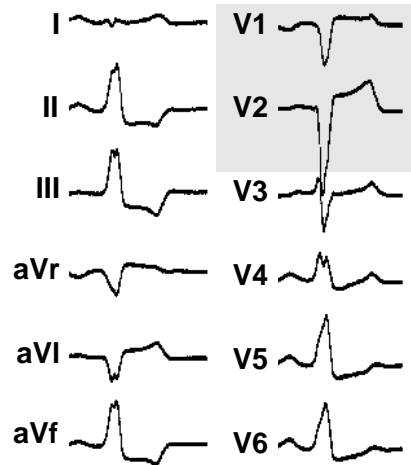


Ouyang et al , JACC 2002;39:500-508

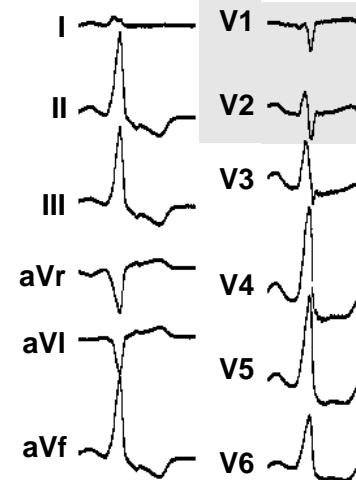
**EHRA educational slides**  
**S. Ernst**



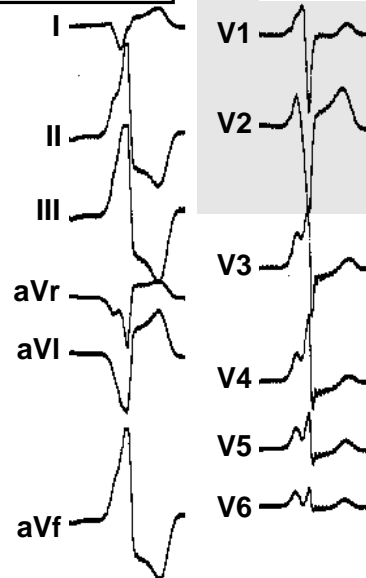
### RVOT ant



### AS rechts



### AS links



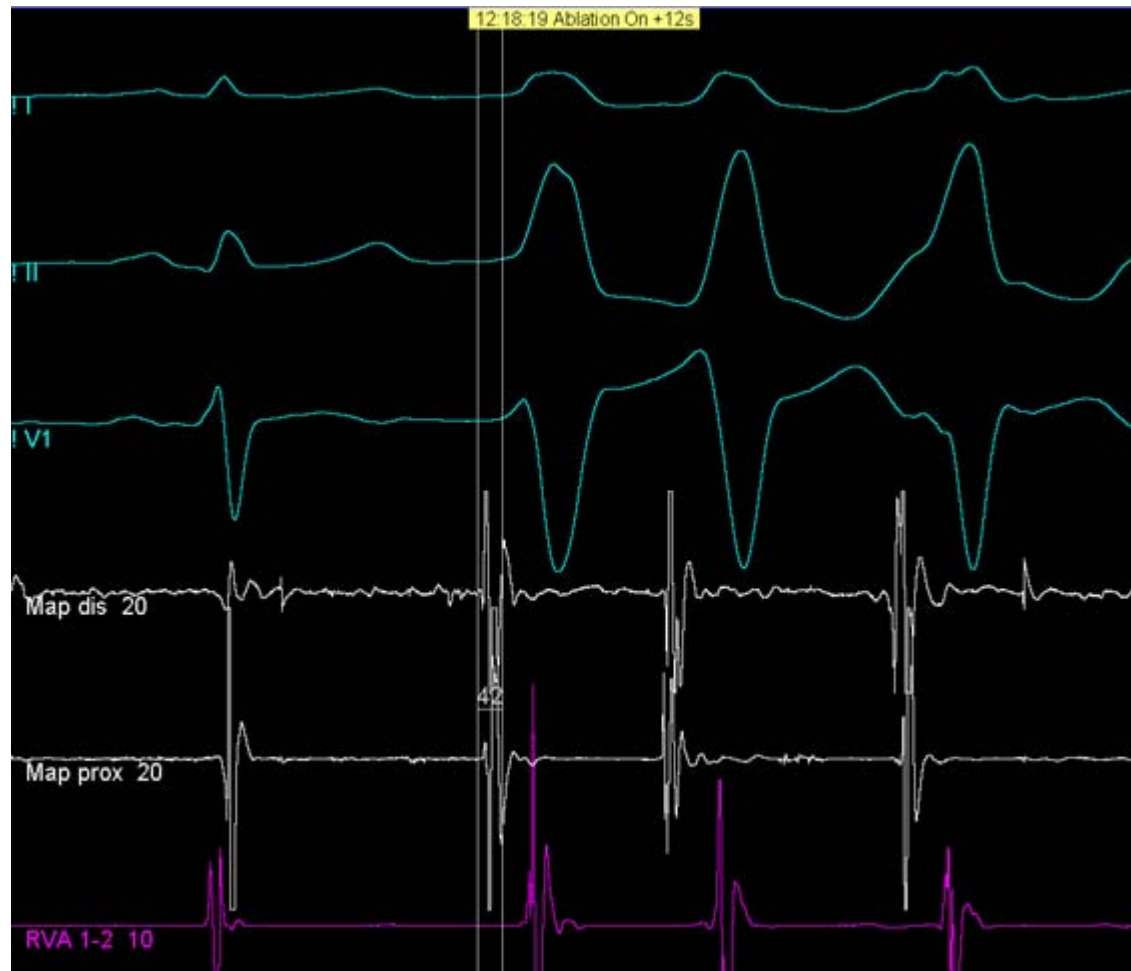# Aortic cusp as origin of tachycardia

## Mapping considerations

- If VES/VT present during EP study
  - Earliest bipolar signal preceding the onset of the VES/VT by >20 ms
  - QS morphology in unipolar MAP signal
- If VES/VT not present or rare during EP study
  - Provocation with isoproterenol
  - Pace-mapping from dist. MAP with 12/12 surface lead morphology

# Aortic cusp as origin of tachycardia

## Example of earliest bipolar signal



# Aortic cusp as origin of tachycardia

## Mapping considerations

### –SPECIAL CONSIDERATIONS

- Positioning of distal CS catheter when suspecting LV-OT/Aortic cusp

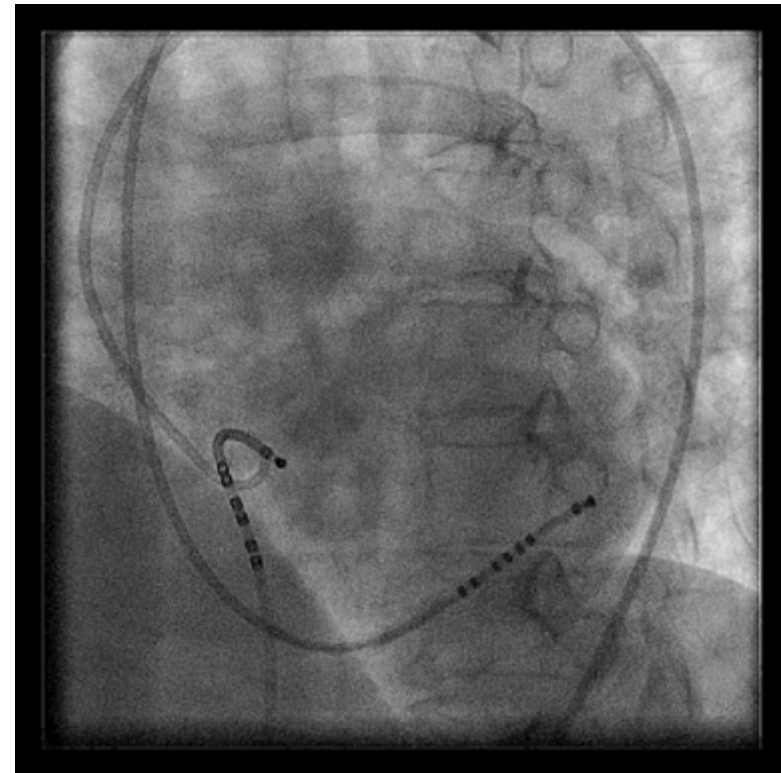
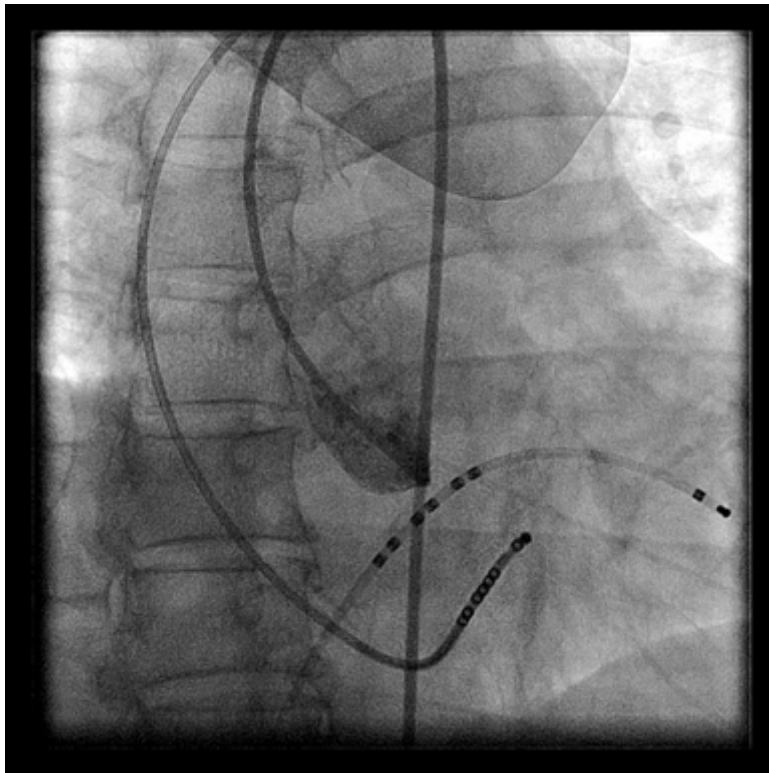
- Before RF delivery in aortic cusp:

Biplane coronary angiography of closest coronary branch or pigtail-guided angiography of the respective aortic cusp is recommended to avoid coronary damage by RF delivery

# Aortic cusp as origin of tachycardia

## Mapping considerations

–SPECIAL CONSIDERATIONS



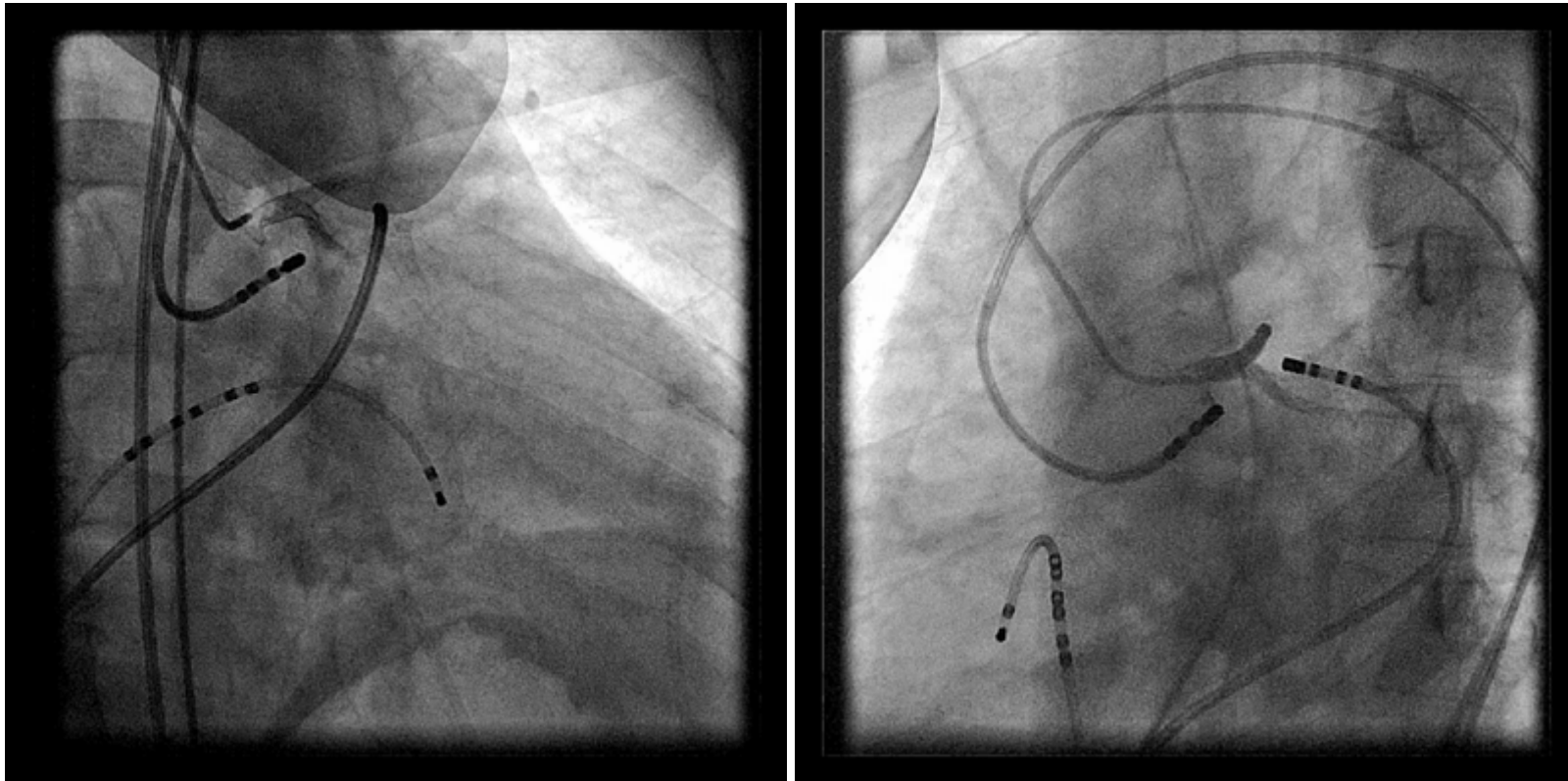
---

**EHRA educational slides**  
S. Ernst

# Aortic cusp as origin of tachycardia

## Mapping considerations

–SPECIAL CONSIDERATIONS

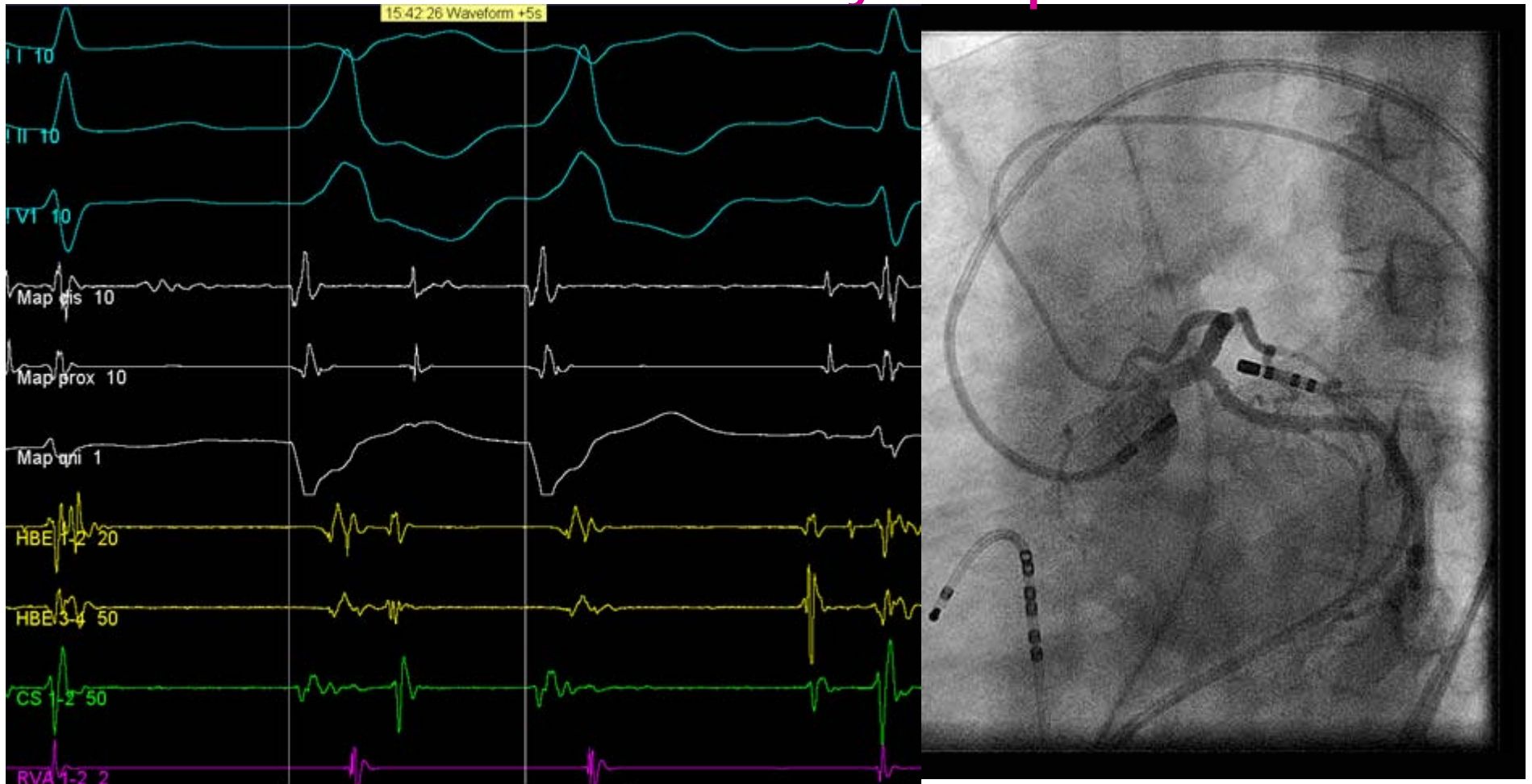


**EHRA educational slides**  
S. Ernst



# Aortic cusp as origin of tachycardia

## Left coronary cusp



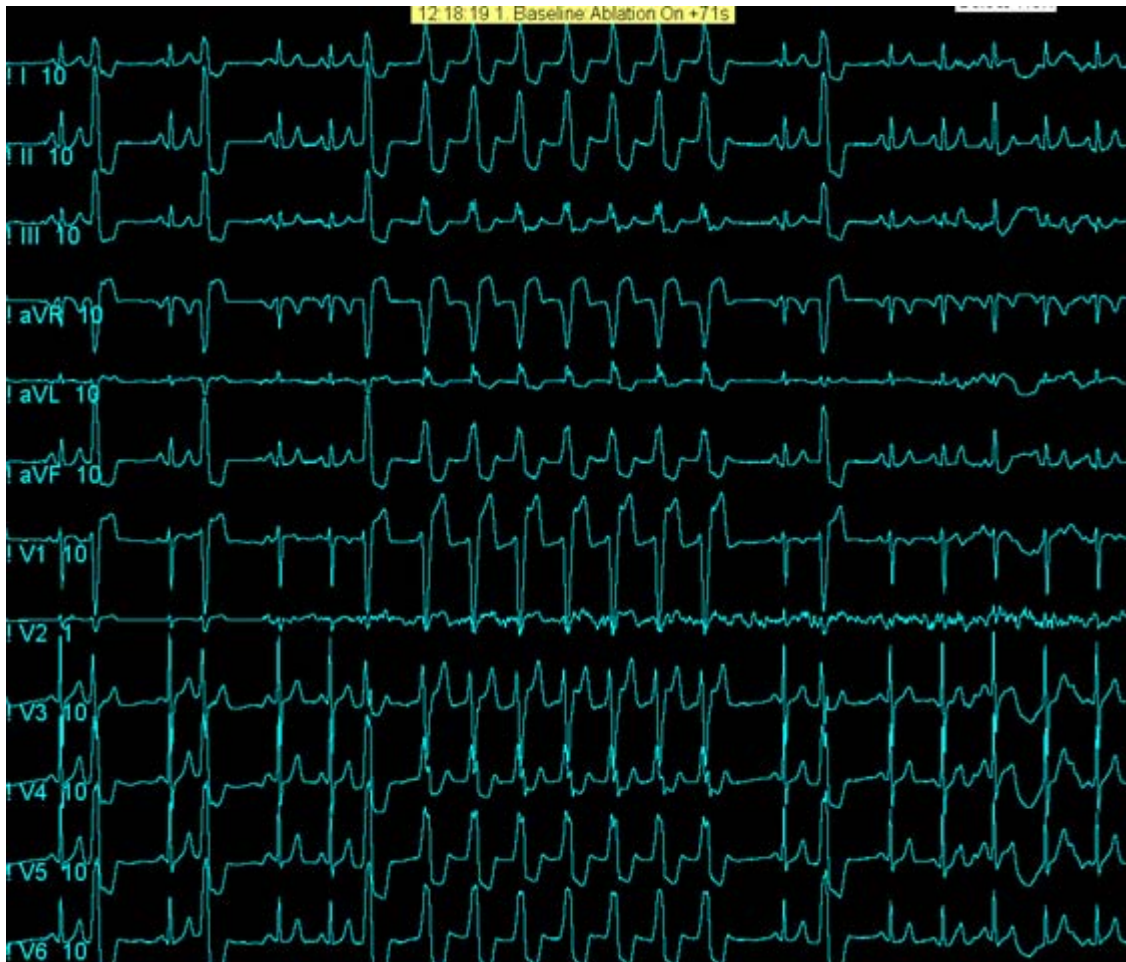# Aortic cusp as origin of tachycardia

## Ablation considerations

- 4 mm solid tip RF ablation is sufficient to cause a transmural lesion
- Typical generator setting: 30 Watts, 60° C
- “Warming up” during RF delivery at successful site

# Aortic cusp as origin of tachycardia

## Example of “warming up” during RF delivery



**EHRA educational slides**  
**S. Ernst**



# Aortic cusp as origin of tachycardia

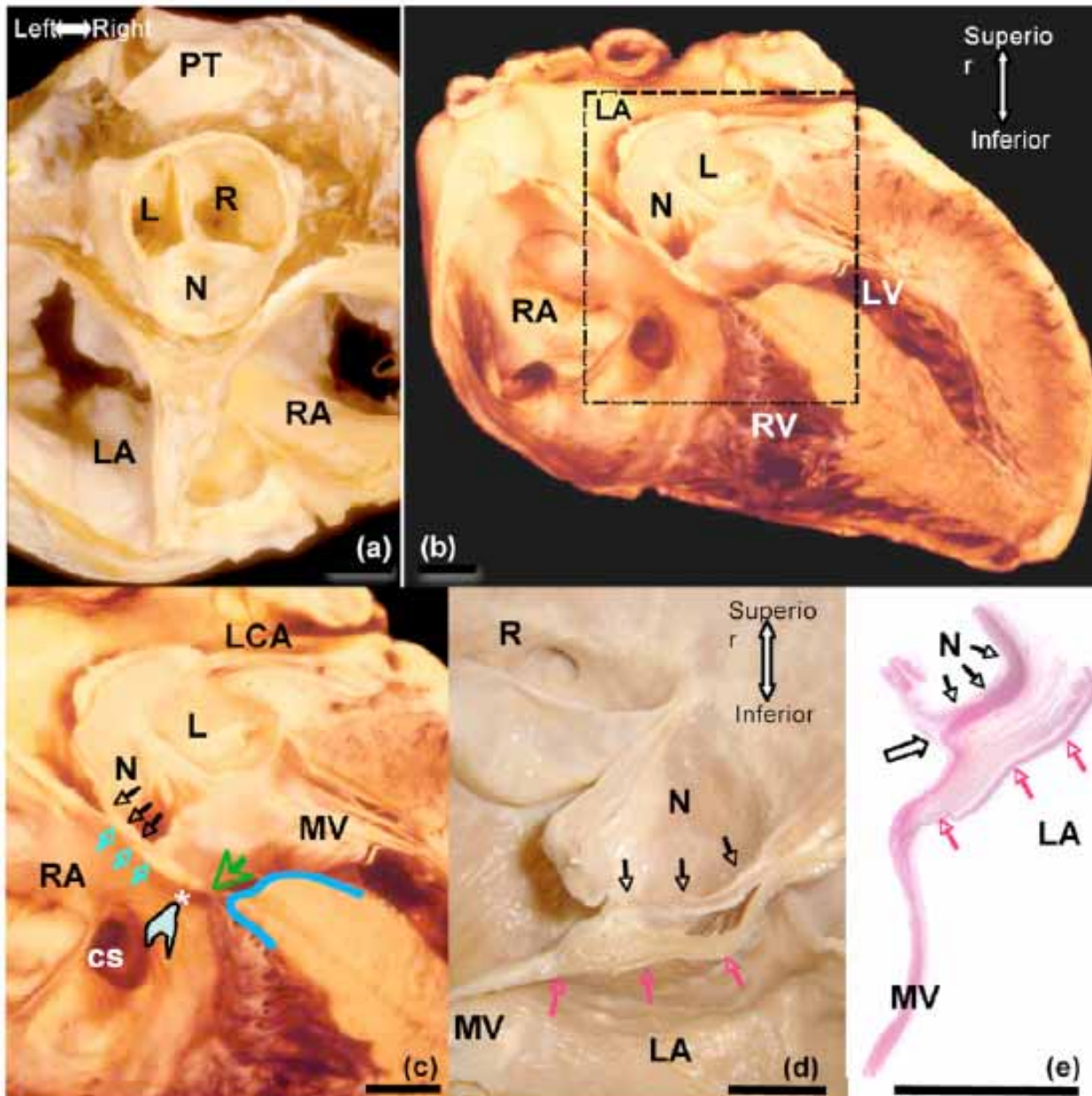
## Results and typical complications

- Percentage of successful ablations: > 95%
- Prognosis:  
very well in the absence of structural heart disease,  
no impact on prognosis

# Aortic cusp as origin of tachycardia

## Supraventricular tachycardia

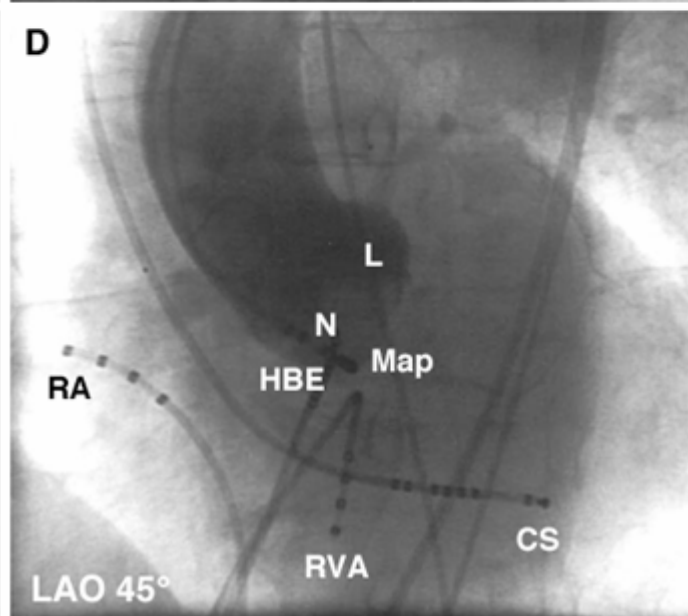
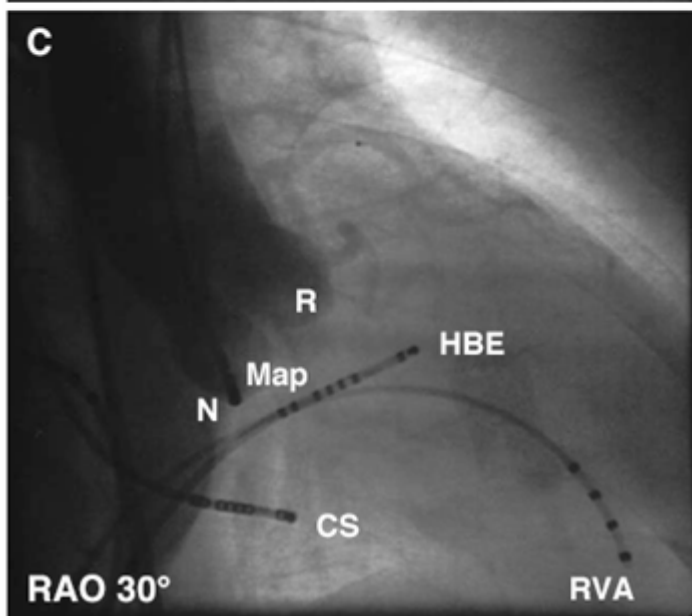
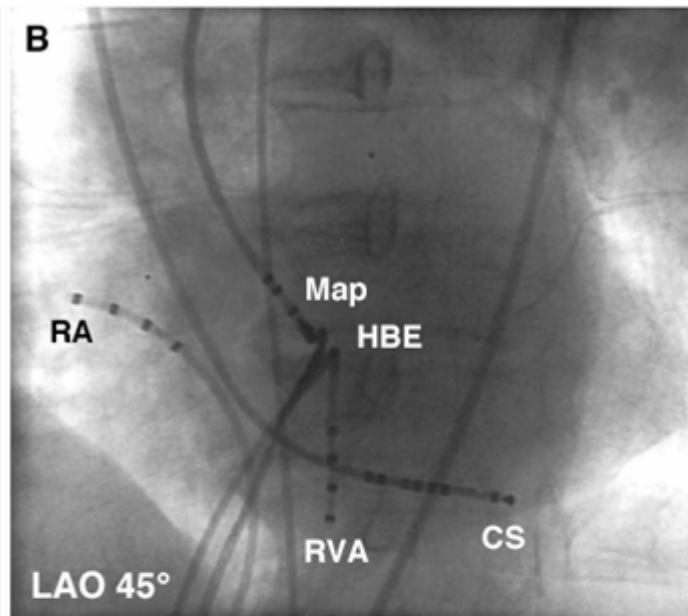
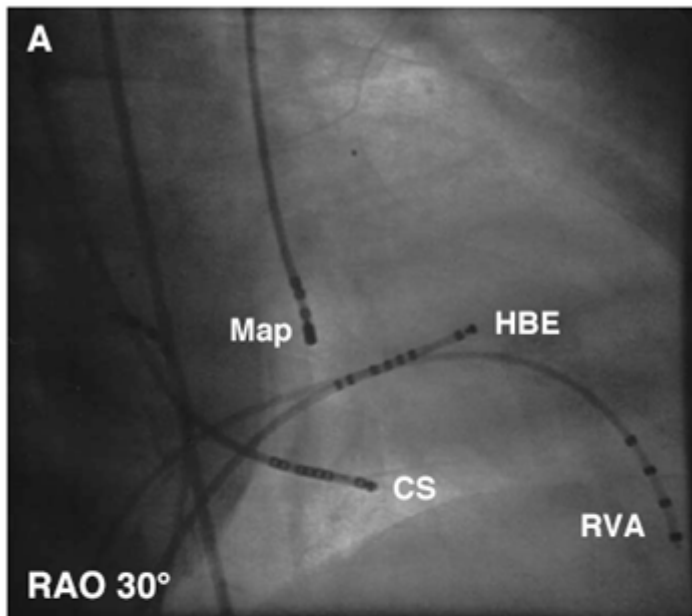
- Rare site for focal atrial tachycardia
- Conventional mapping demonstrates earliest atrial activation in the His recording electrodes

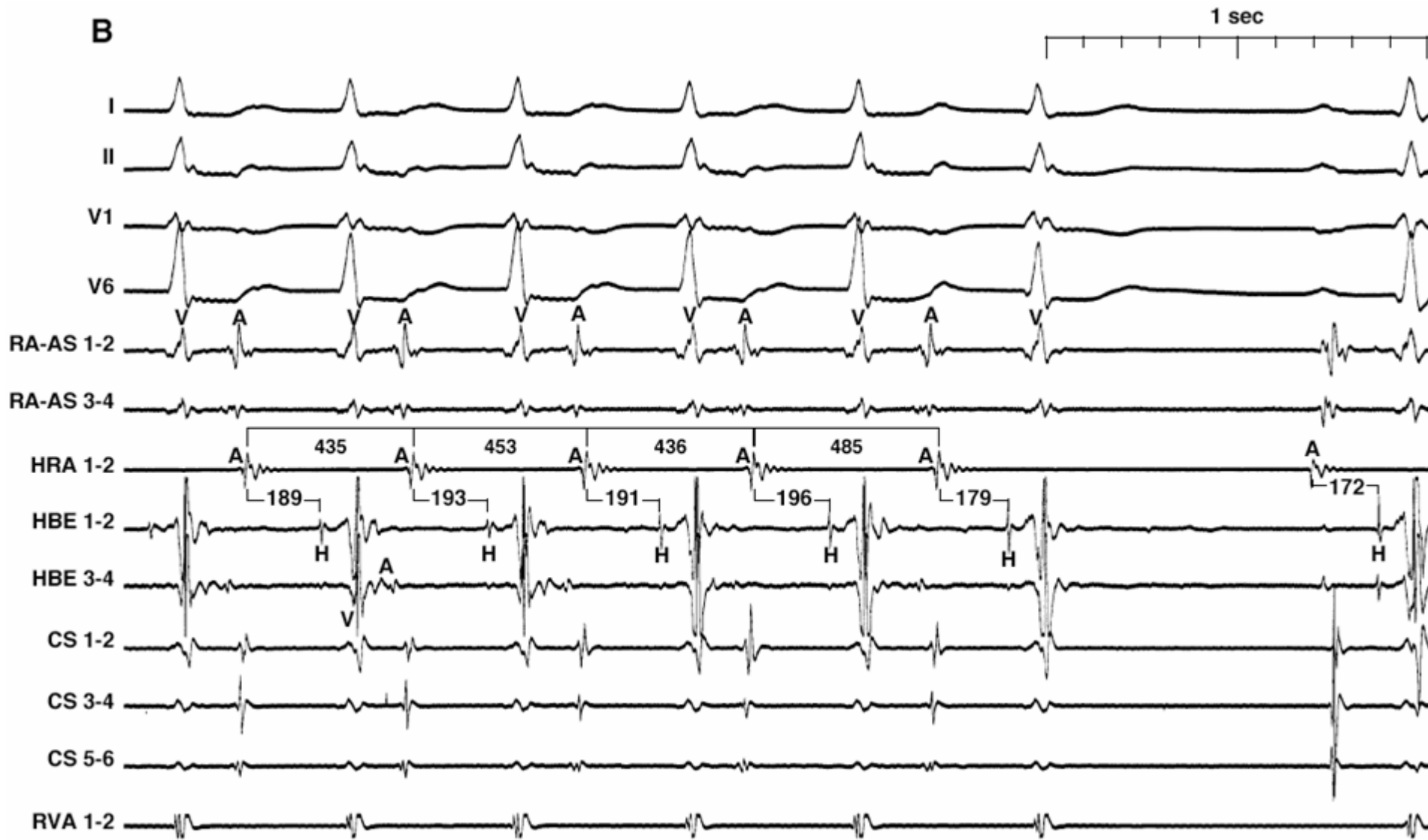


Ouyang et al. JACC 2006

**EHRA educational slides**  
**S. Ernst**







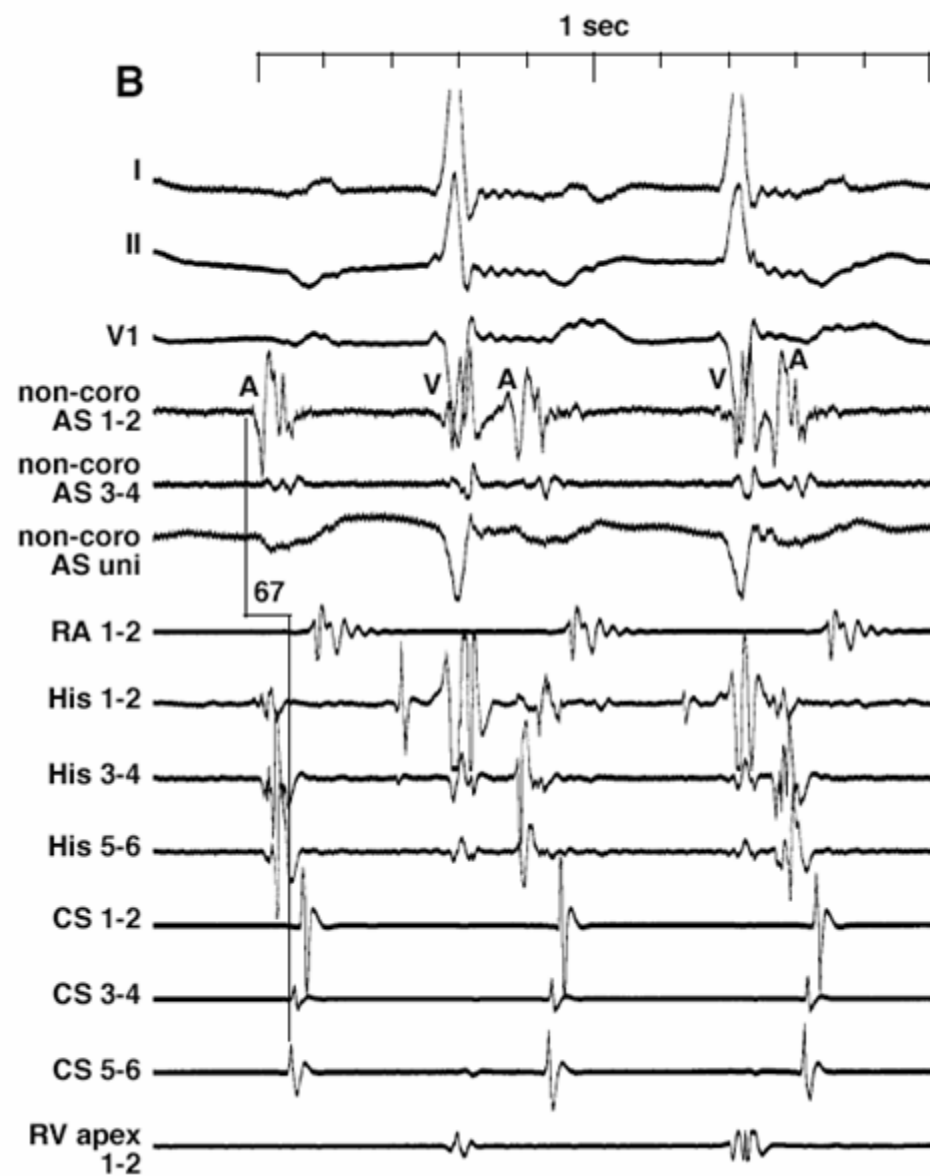
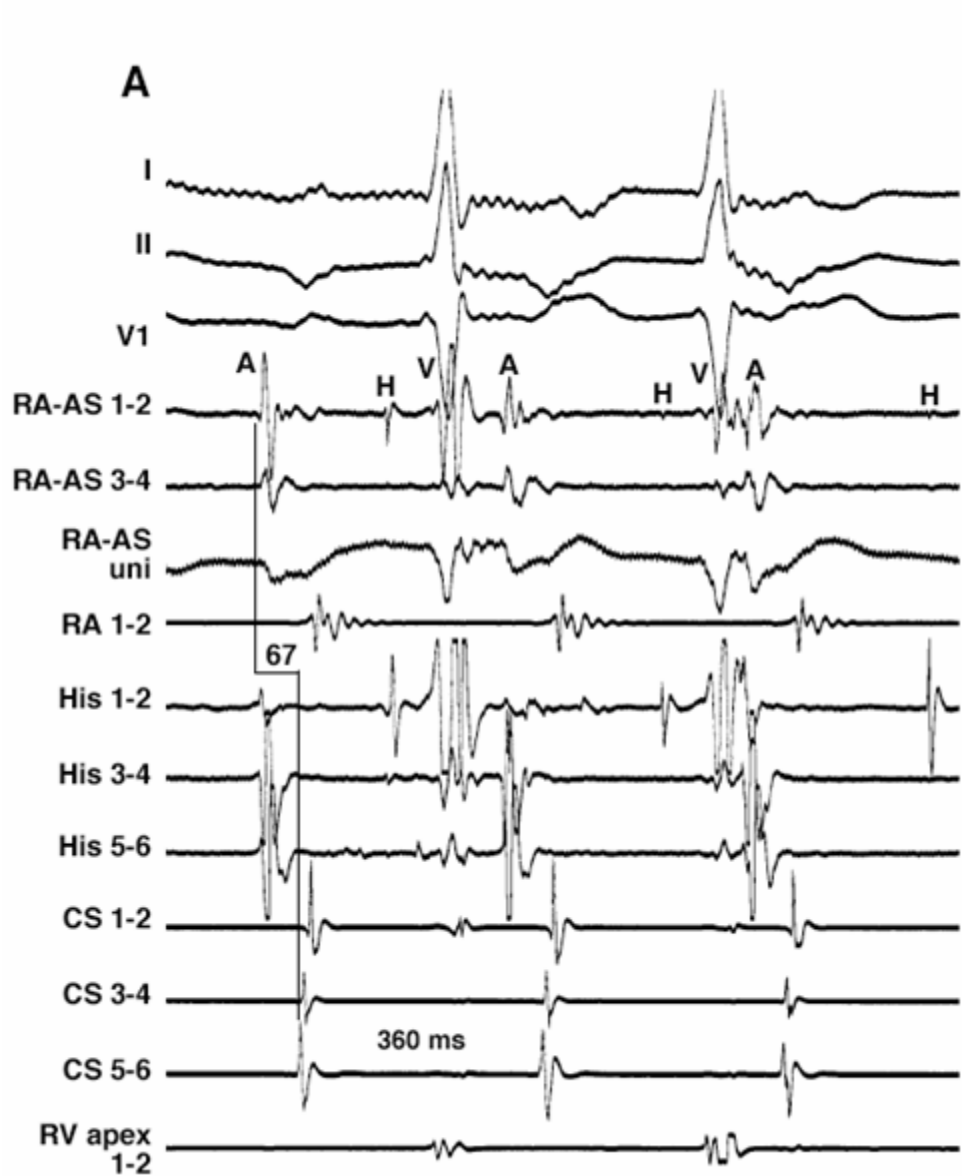
during i.v. administration of adenosine 12mg

**EHRA educational slides**

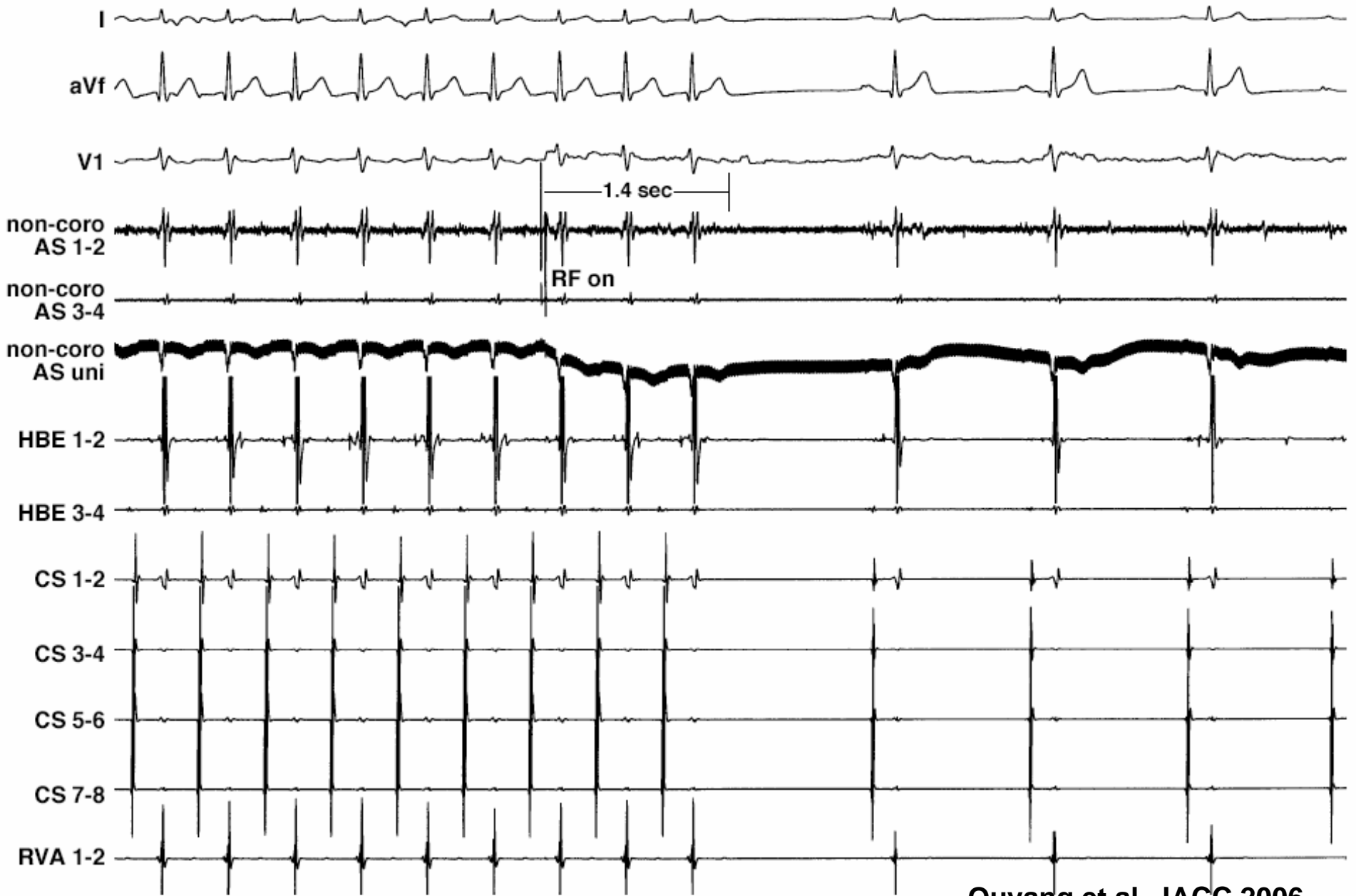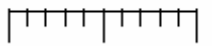
**S. Ernst**

Ouyang et al. JACC 2006





1 sec



AT termination after 1.4 seconds

Ouyang et al. JACC 2006

# Aortic cusp as origin of tachycardia

## Summary

- Excellent ablation results for both OT-VT/VES and SVT catheter ablation as a first-line therapy in symptomatic patients
- Consideration of neighboring structures (epicardial locations)
- Low complication rates when performed with careful assessment of coronary anatomy