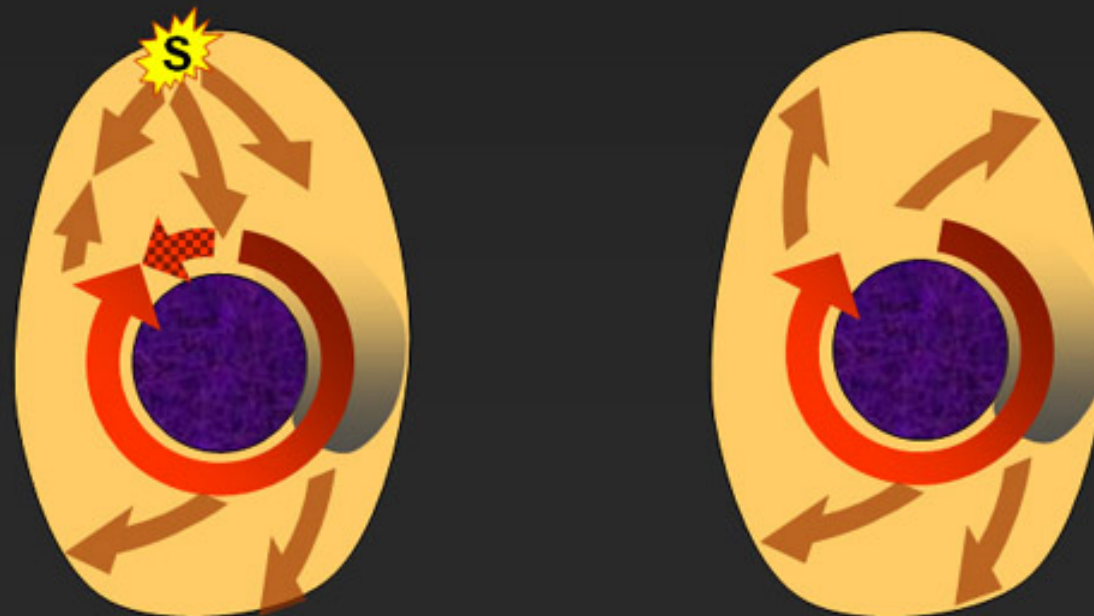
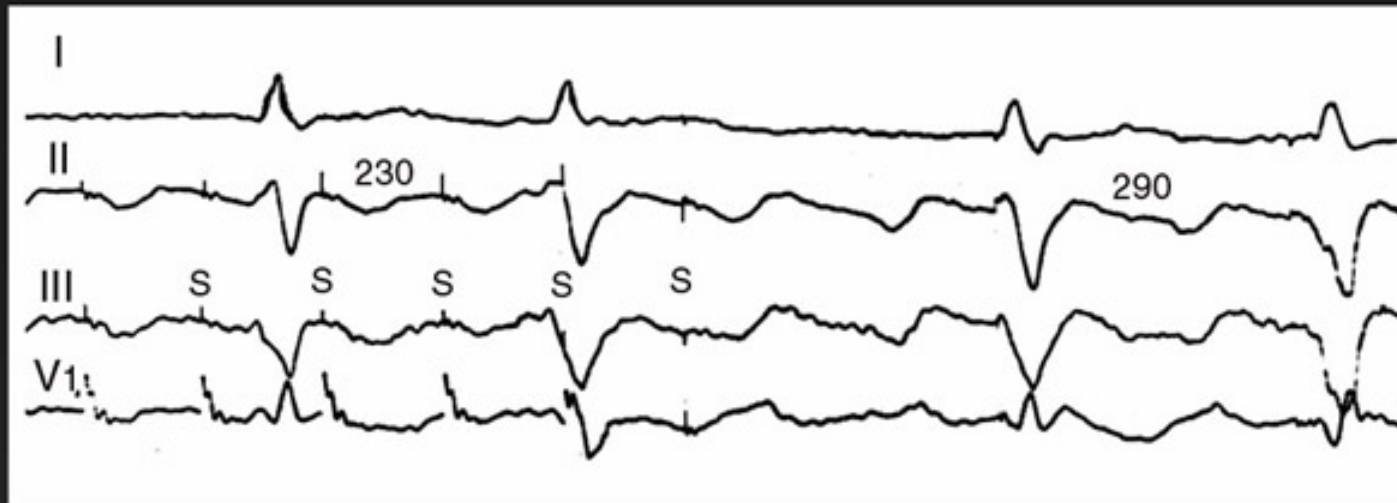
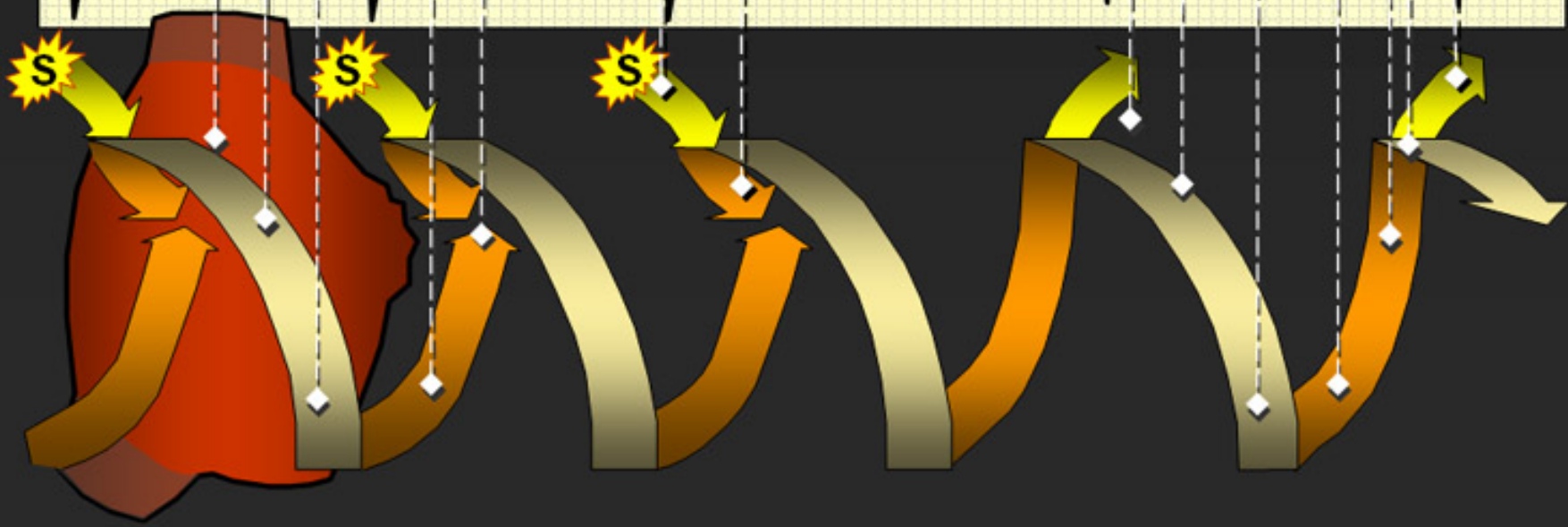
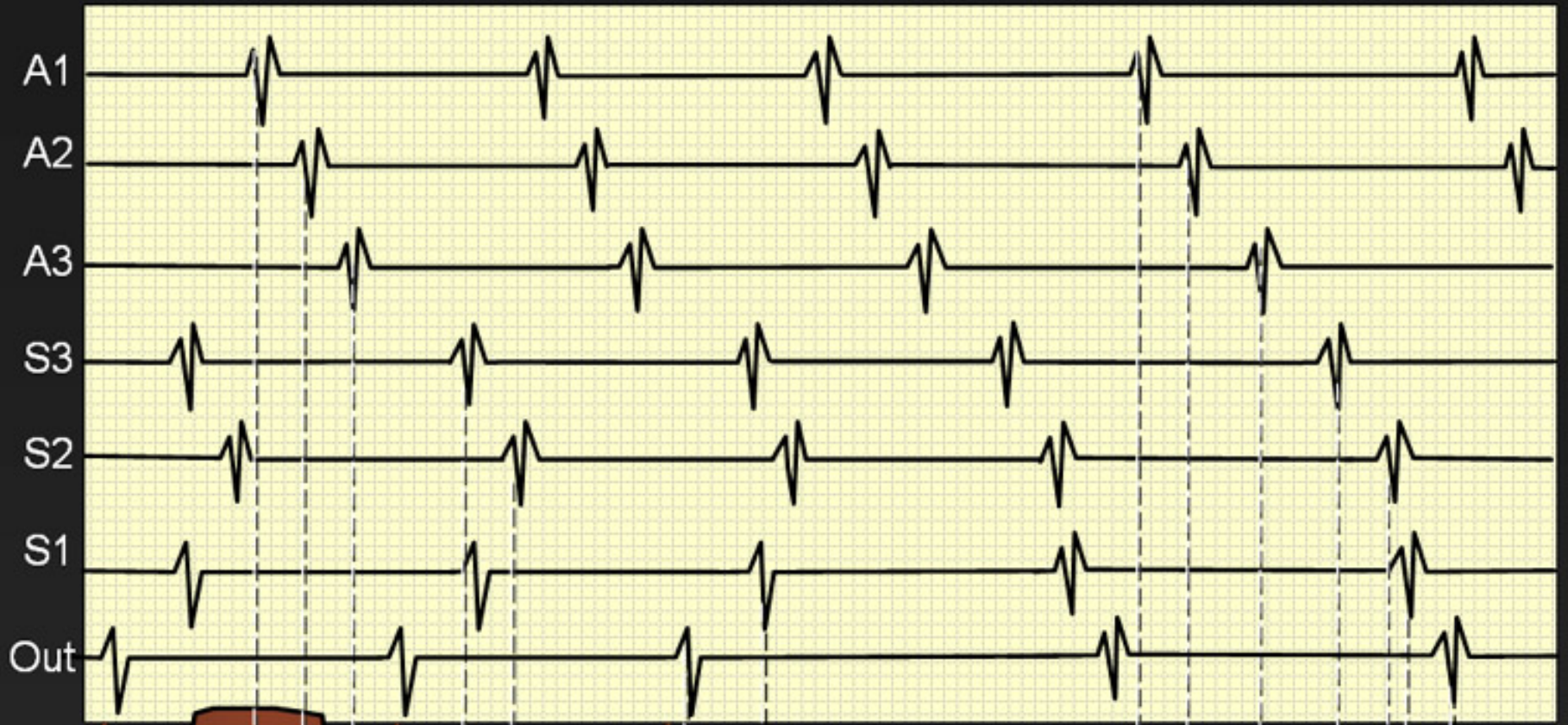


Entrainment as a Diagnostic Tool

Francisco G. Cosio, MD
FESC, FACC, FHRS
Chief Cardiology Service
Hospital Universitario de Getafe
Madrid, Spain

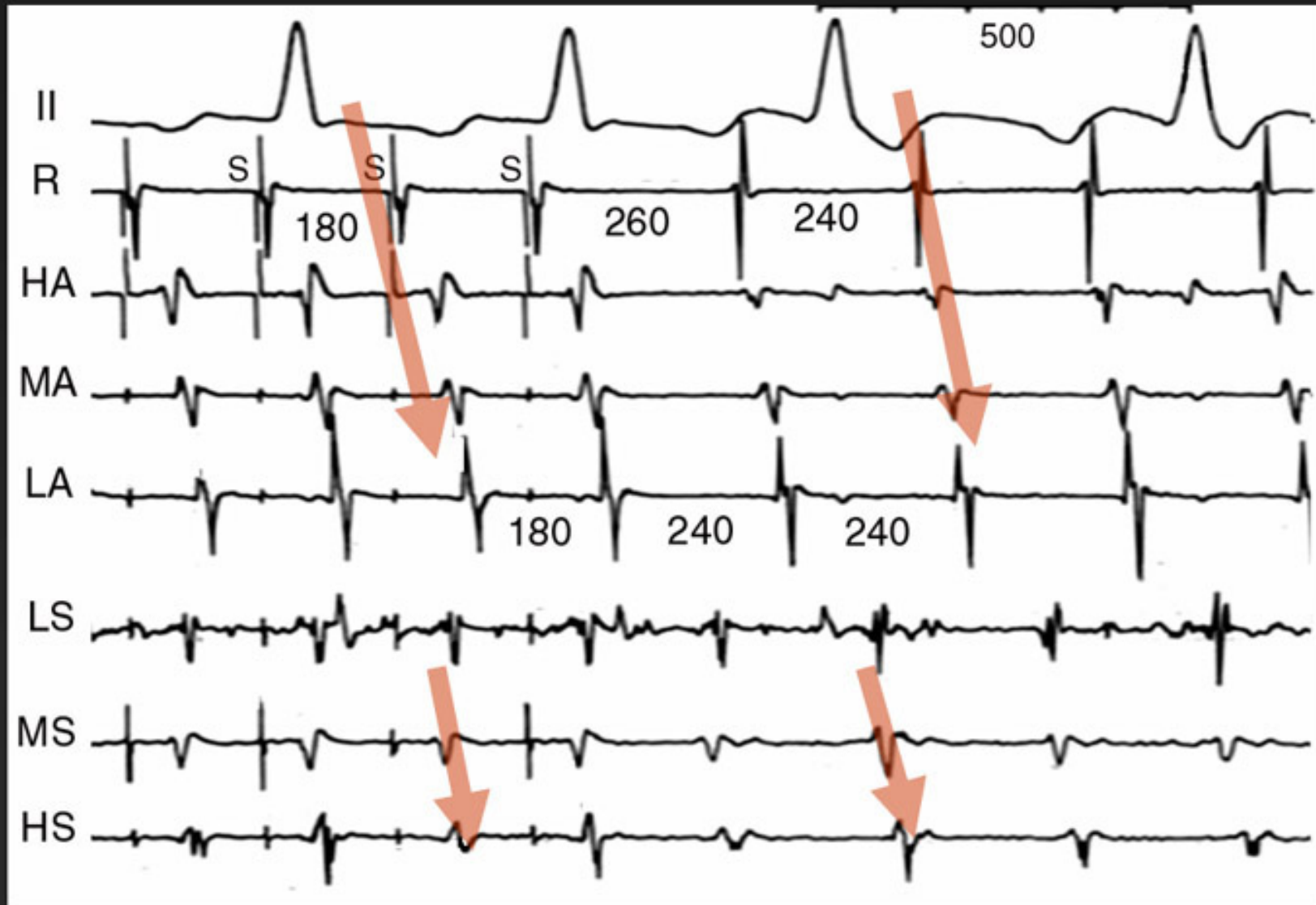
How come pacing high RA the "captured P wave" is negative in II?



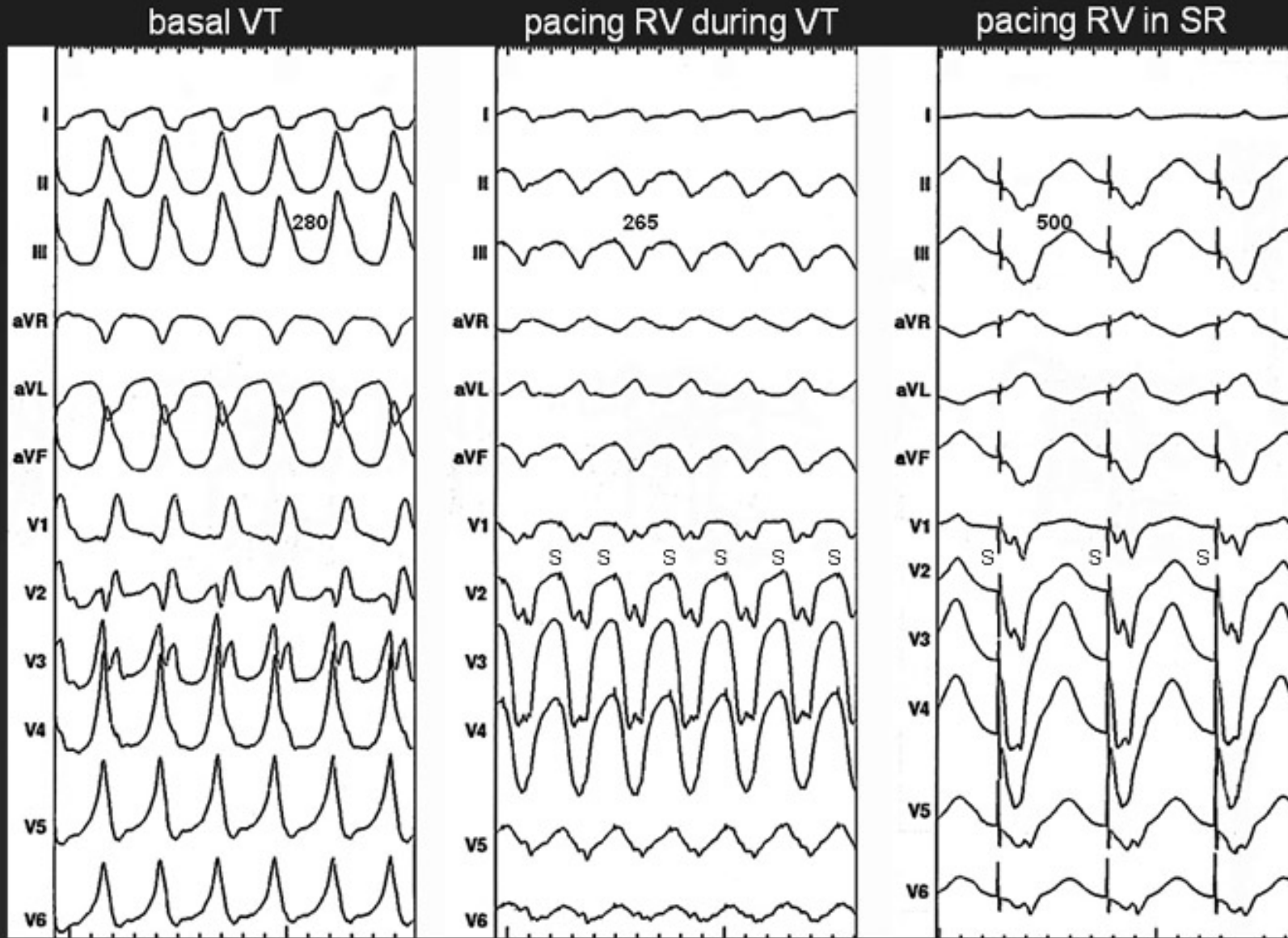


Francisco G Cosío MD

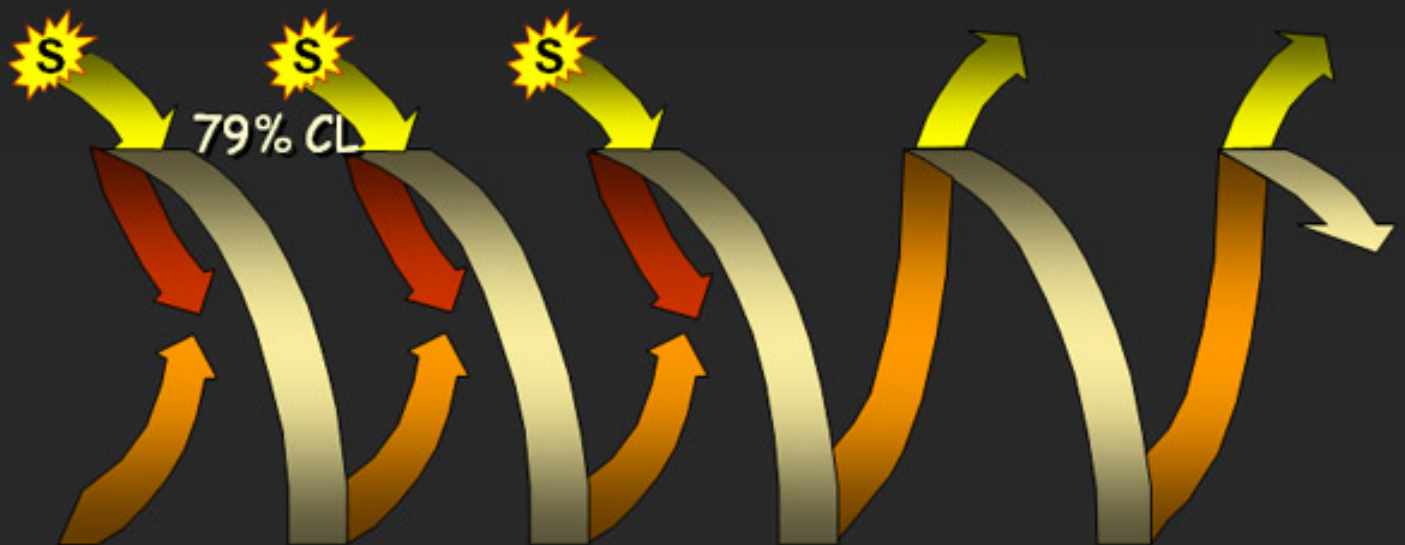

"Fusion" pattern due to overlap with little antidromic penetration



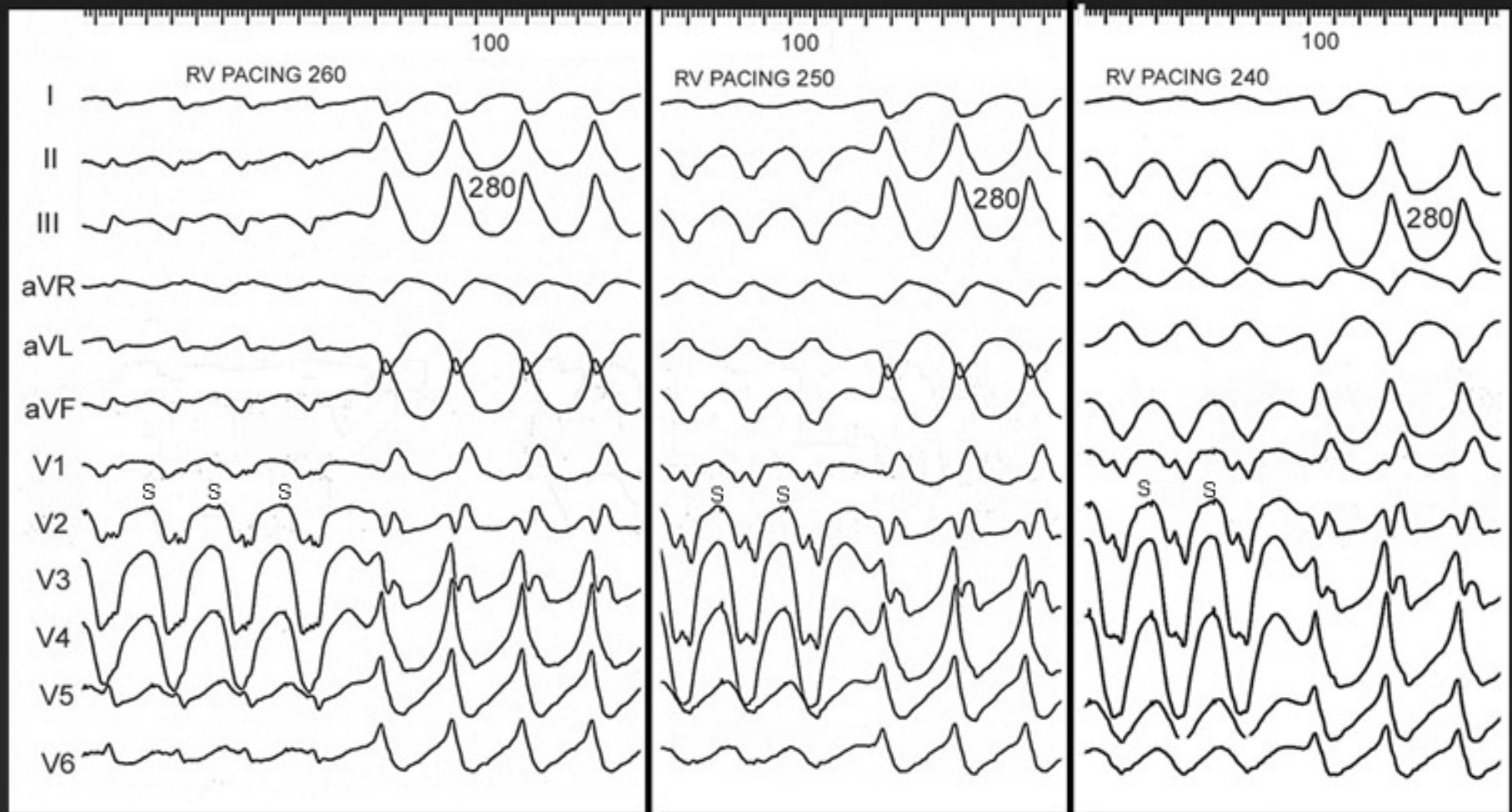
Entrainment with fusion (VT)



Entrainment with progressive fusion

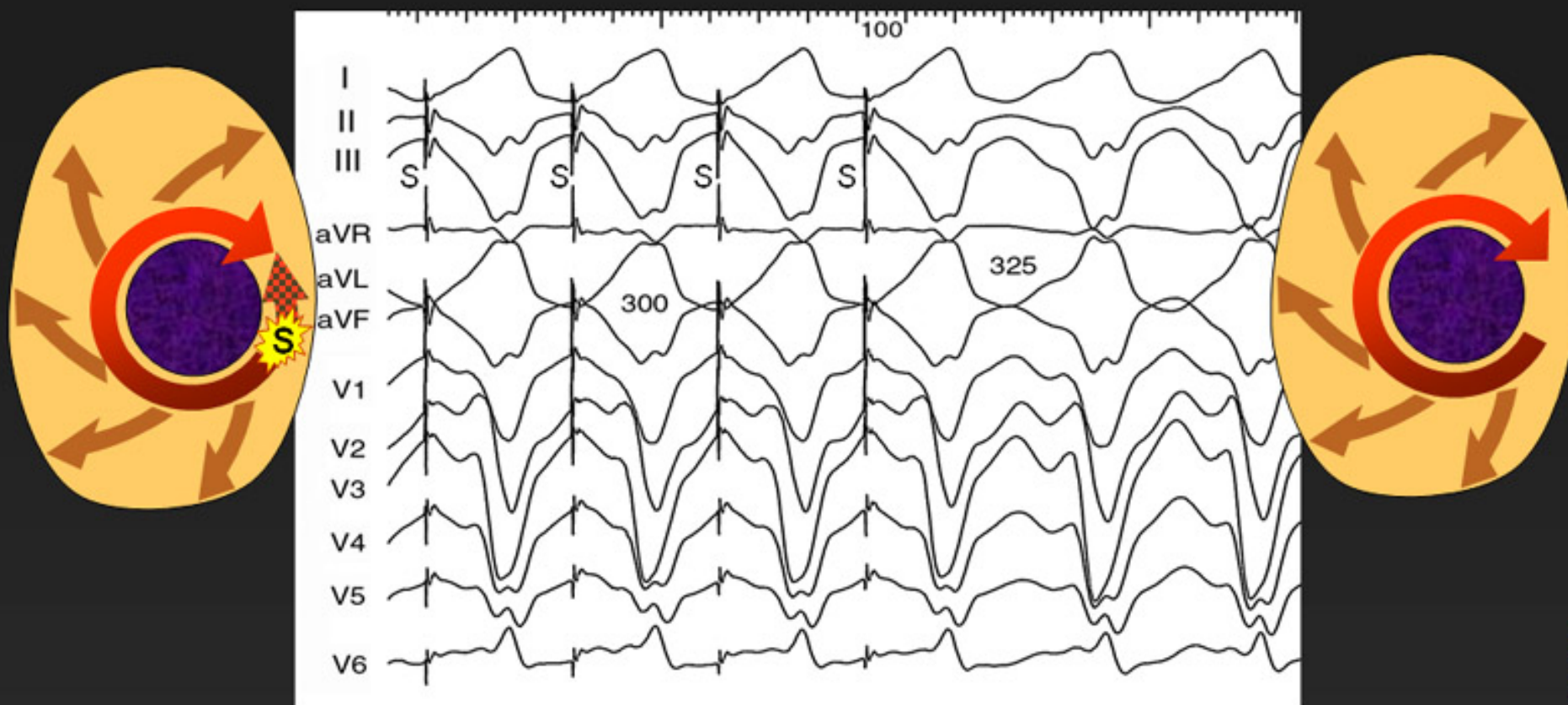


VT entrainment with progressive fusion

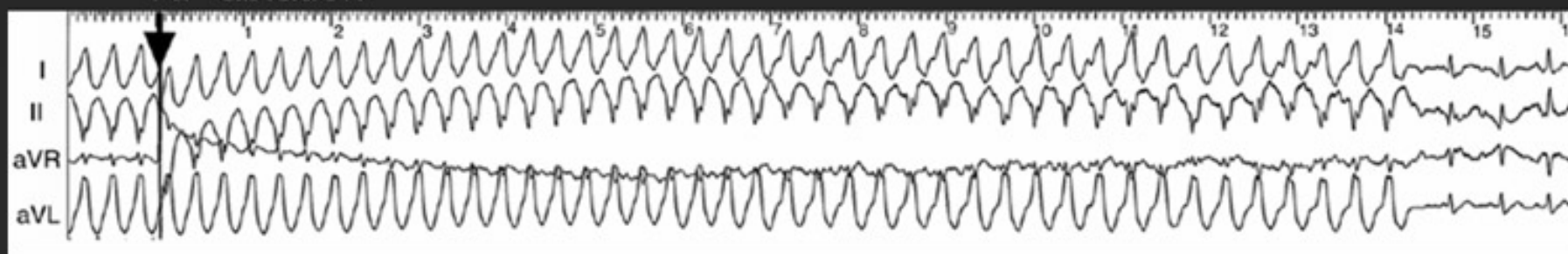


Concealed entrainment (VT)

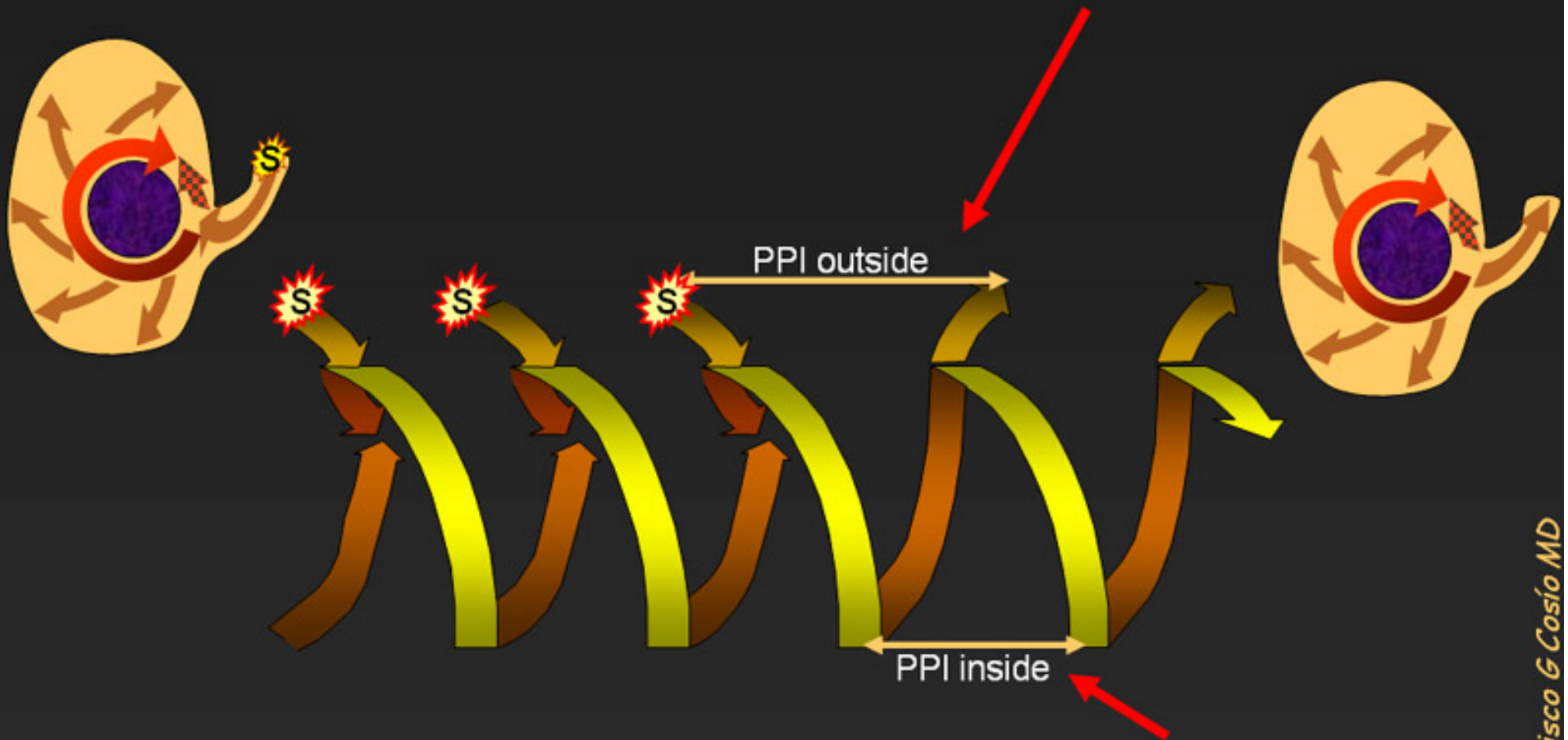
Pacing a narrow isthmus inside the circuit does not produce fusion



RF ablation

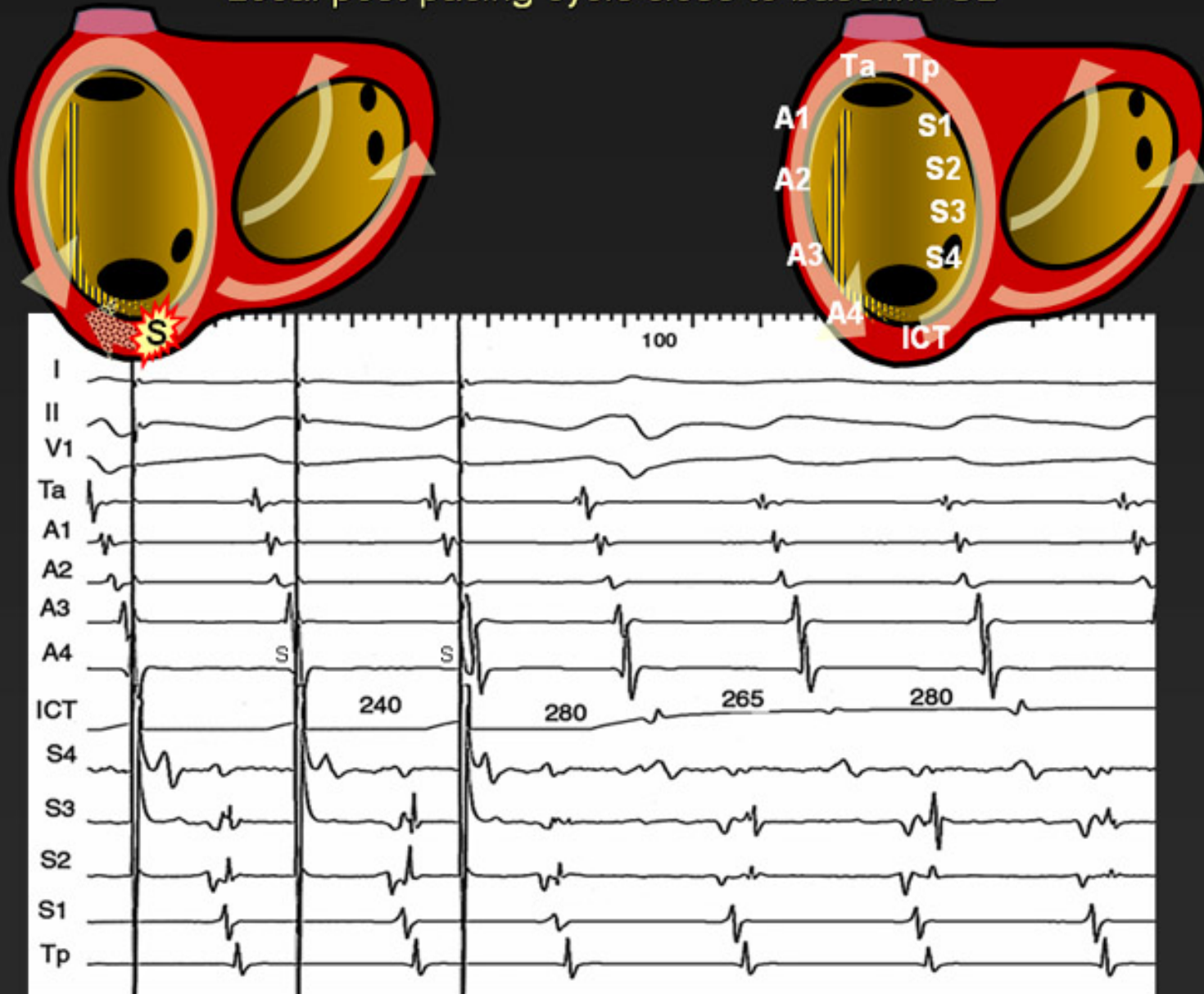


The PPI confirms that the pacing site is in the circuit
(*pacing a dead-end channel, could produce concealed
entrainment but the local PPI would be long*)

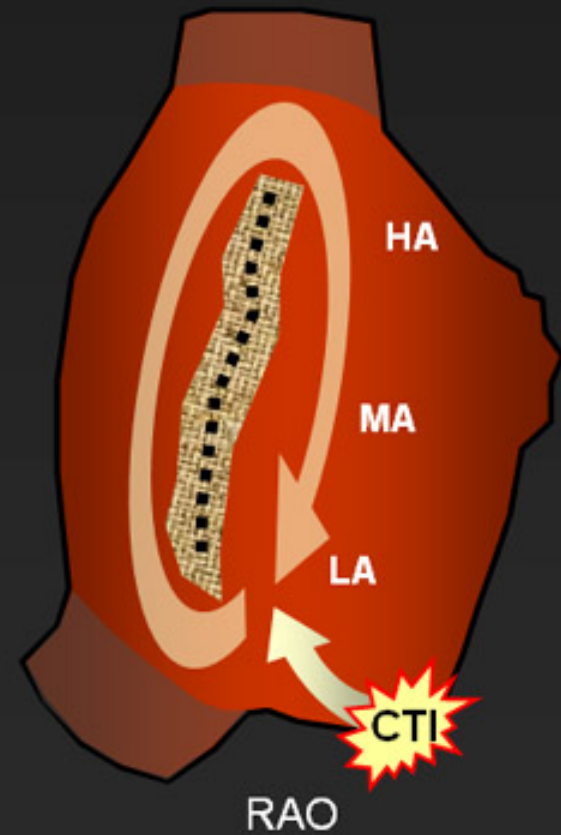
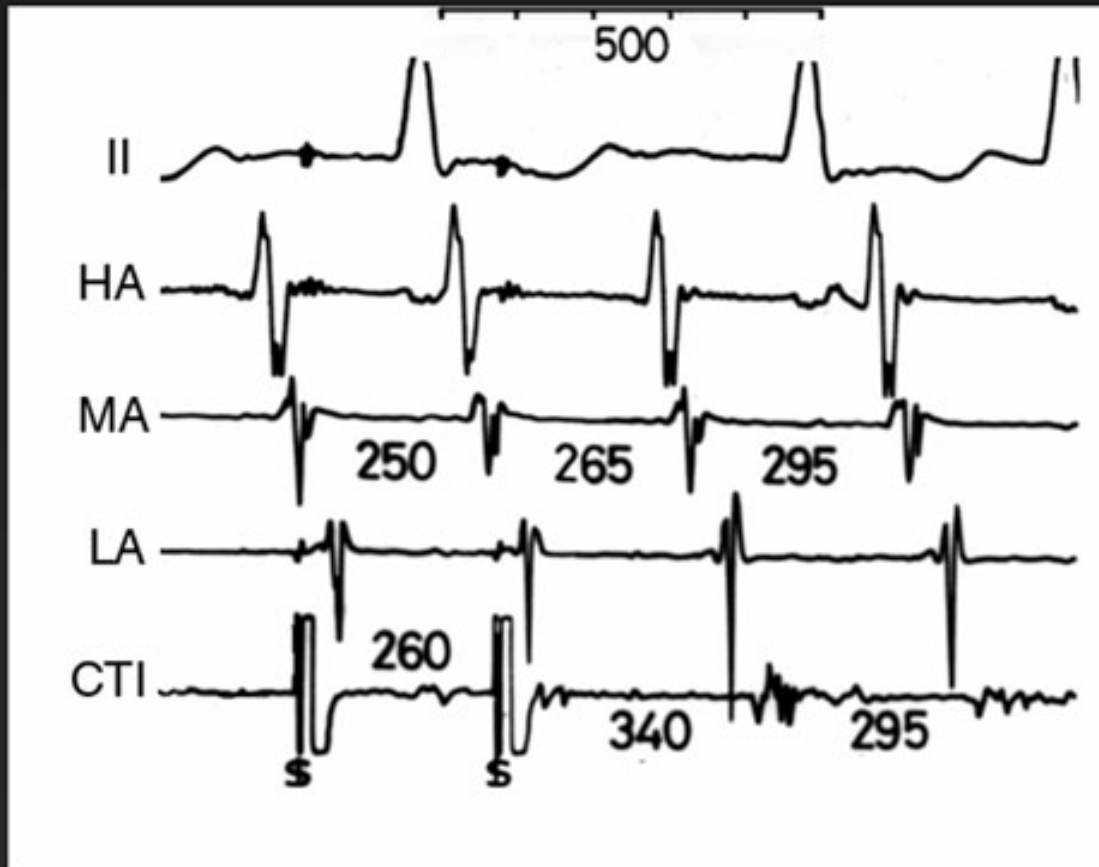


But then, note that: the PPI will be equal to basic CL inside the circuit even when pacing is done outside it. This helps localize the circuit with recordings from multiple sites.

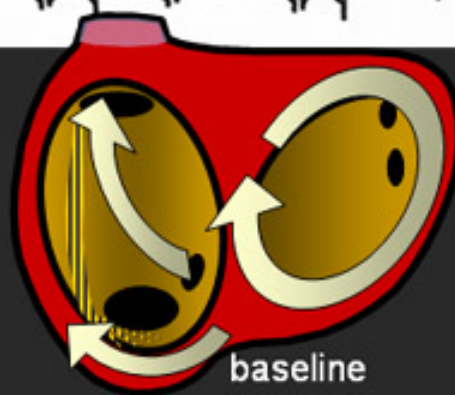
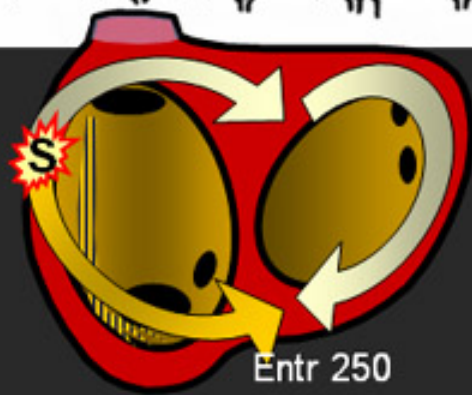
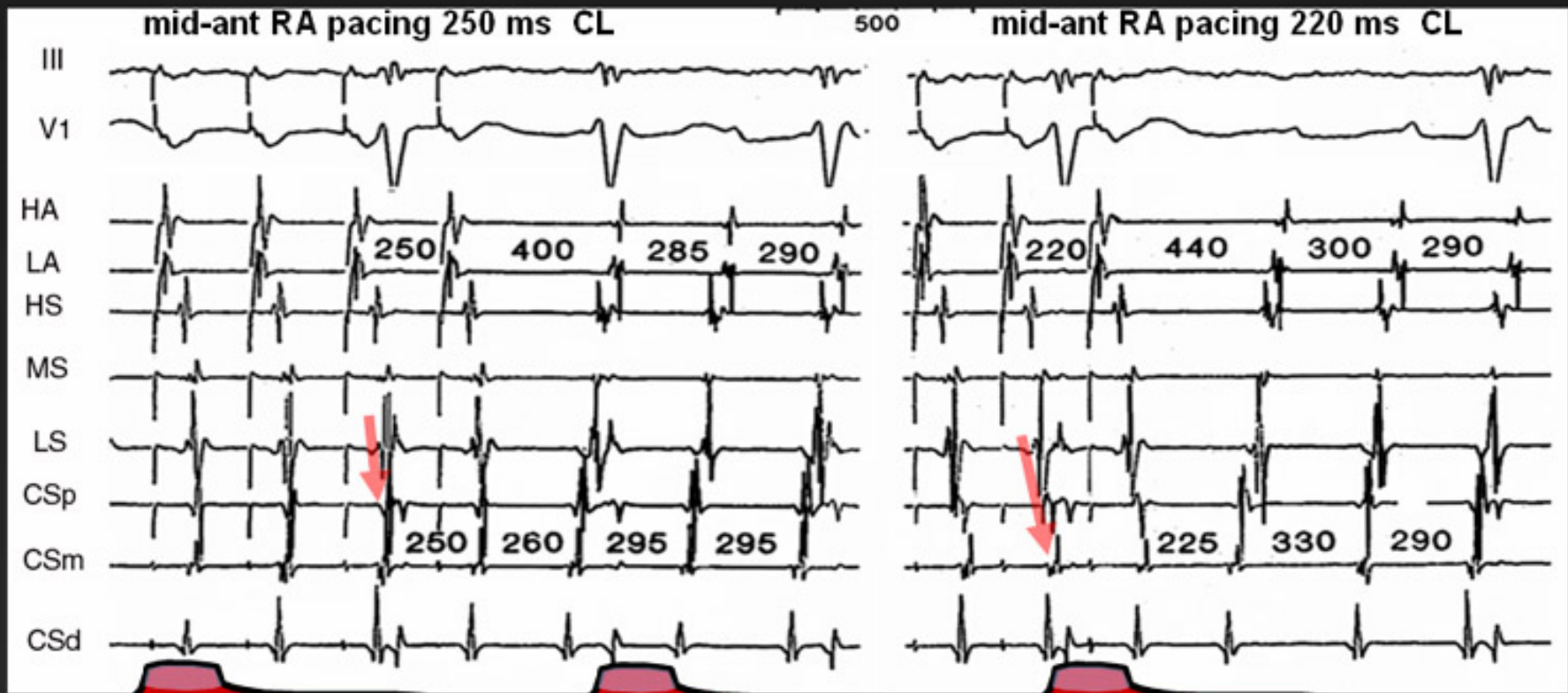
Concealed entrainment in Typical Atrial Flutter
Local post-pacing cycle close to baseline CL



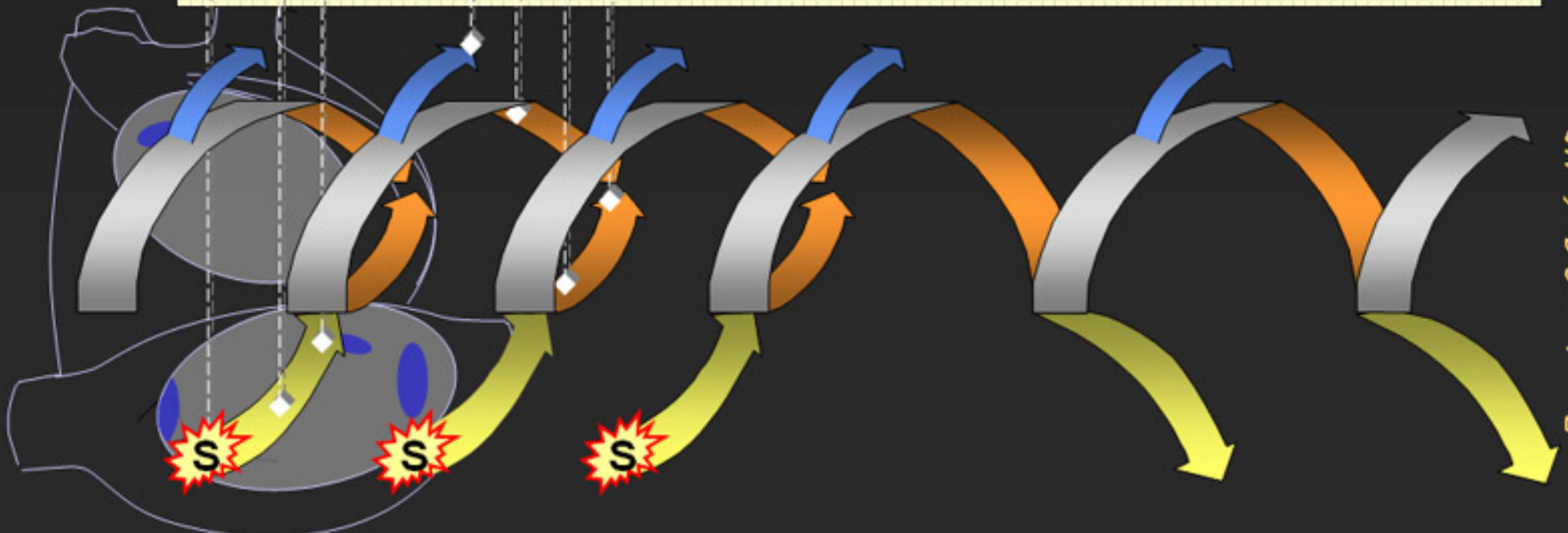
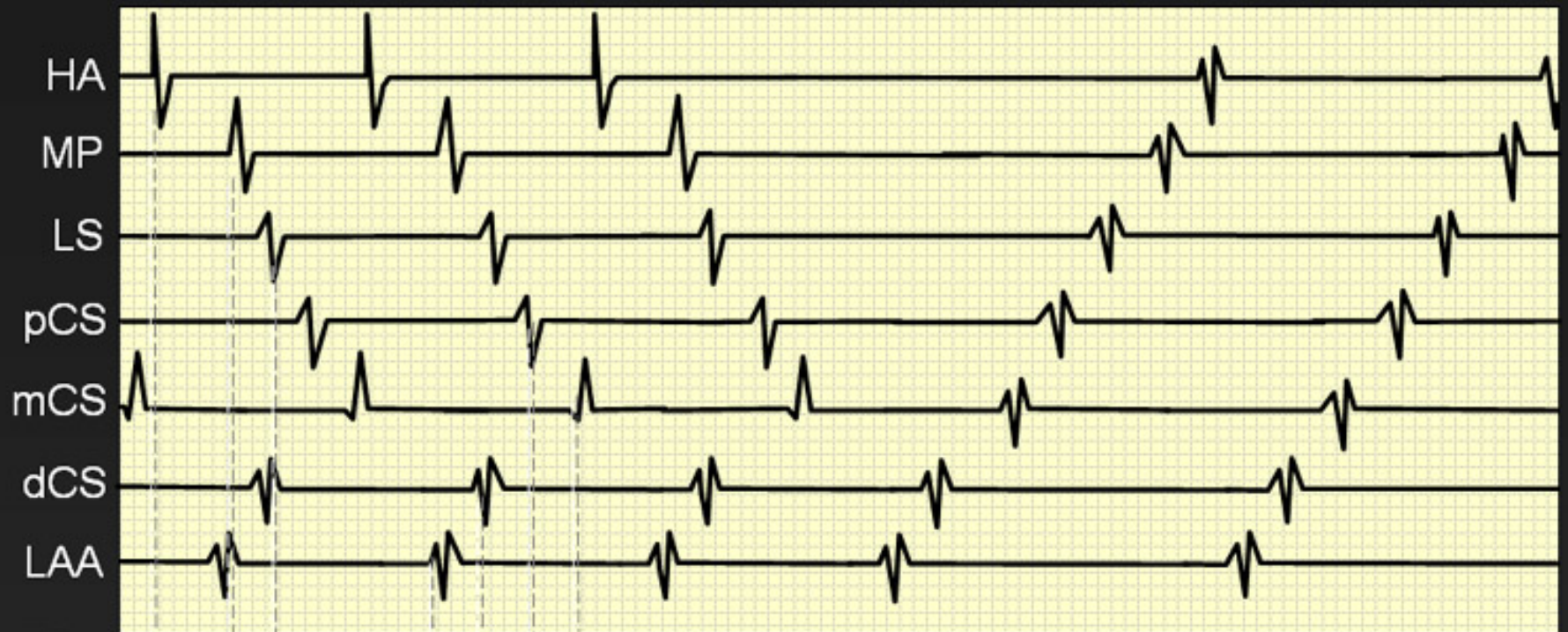
Recognize entrainment by recording
PPI distant from the pacing site



Recognize PPI and progressive fusion in intracardiac recordings away from the pacing point: LA MRT



Recognize PPI and progressive fusion in intracardiac recordings away from the pacing point: LA MRT



Francisco G Cosío MD