

EAE RECOMMENDATIONS
Contrast echocardiography:
evidence-based
recommendations by European Association
of Echocardiography

Roxy Senior, Harald Becher, Mark Monaghan, Luciano Agati, Jose Zamorano, Jean Louis Vanoverschelde, and Petros Nihoyannopoulos

European Journal of Echocardiography (2009) 10, 194–212

©European Association of Echocardiography 2009

www.escardio.org/EAE



Table 1 Characteristic of currently available contrast agents in UK and Europe

	SonoVue ⁶	Optison ⁷	Luminality ⁸
Gas	Sulphur hexafluoride	Perfluoropropane	Perfluoropropane
Bubble size	2–8 μm	3.0–4.5 μm	1.1–2.5 μm
Surface coating	Surfactant/powder	Human albumin	Naturally occurring lipids
Contraindications and precautions			
Patients experiencing side effects in clinical trials (%)	11	17	8
Most frequent side effects in clinical trials	Headache (2.1%), nausea (1.3%), chest pain (1.3%), taste perversion (0.9%), hyperglycaemia (0.6%), injection site reaction 0.6%), paresthesia (0.6%), vasodilation (0.6%), injection site pain (0.5%).	Headache (5.4%), nausea and/or vomiting (4.3%), warm sensation or flushing (3.6%), dizziness (2.5%).	Headache (2.0%), flushing (1.0%), back pain (0.9%). rash/urticaria, wheezing/,allergic/anaphylaxis
Manufacturer	Bracco Diagnostics	GE Healthcare	Lantheus Medical Imaging (formerly Bristol-Myers Squibb)

European Journal of Echocardiography (2009) 10, 194–212

Table 2 Efficacy of contrast agents on various measures of image enhancement in echocardiography (Modified from Bhatia and Senior)¹⁰²

Study	Patients (n)	Contrast agent used vs. comparator or control	Measure of contrast enhancement					
			LVB length	LVO	LVEB score	Duration of contrast effect	Salvage of non-diagnostic echo	Side effect profile
Cohen <i>et al.</i> ⁹⁴	203	Optison vs. Albutex	↑	↑		↑		↔↔
Senior <i>et al.</i> ⁹⁵	218	Sonovue			↑		↑	↔↔
Kitzman <i>et al.</i> ⁹⁶	211	Luminity		↑		↑	↑	↔↔
Nguyen <i>et al.</i> ⁹⁷	40	Optison			↑		↑	
Nanda <i>et al.</i> ⁹⁸	138	Sonovue vs. Albutex vs. saline		↑	↑	↑		↔↔
Rizzo <i>et al.</i> ⁹⁹	40	Sonovue			↑			

Upward arrows signify significant improvement and horizontal arrows signify no significant difference in side effects compared with control. LVB, left ventricular border; LVO, left ventricular opacification; LVEB, left ventricular endocardial border delineation score.

European Journal of Echocardiography (2009) 10, 194–212

Table 3 Efficacy of contrast echocardiography for the assessment of left ventricular ejection fraction volumes or regional wall motion abnormalities (Adapted from Bhatia and Senior)¹⁰²

	Patients (n)	Comparator	Unenhanced imaging mode	Contrast agent	Agreement vs. comparator*		P-value
					Without contrast	With contrast	
Hundley <i>et al.</i> ¹³	40	CMR	FI	EchoGen	0.85 (EF) 0.92 (EDV) 0.94 (ESV)	0.93 (EF) 0.95 (EDV) 0.97 (ESV)	<0.03 <0.02 <0.01
Reilly <i>et al.</i> ¹⁴	70	^a	HI	Optison	62% (EF)	91% (EF)	<0.0001
Nahar <i>et al.</i> ¹⁵	50	RNI	HI	Optison	0.84 (EF)	0.96 (EF)	
Yu <i>et al.</i> ¹⁶	51	RNI	HI	Levovist	0.89 (EF) 0.71 (EDV) 0.89 (ESV)	0.97 (EF) 0.93 (EDV) 0.97 (ESV)	
Yong <i>et al.</i> ¹⁷	32	TEE	HI	Optison	0.83 (EF) 58% RWMA	0.91 (EF) 70% RWMA	
Malm <i>et al.</i> ¹⁸	110	CMR	HI	Luminity Sonovue	71% EDV 80% ESV 92% EF	85% EDV 90% ESV 97% EF	
Hoffmann <i>et al.</i> ¹⁹	120	CMR ^b	HI	Sonovue	kappa 0.43 RWMA	kappa 0.77 RWMA	<0.05
Lim <i>et al.</i> ²⁰	36	CMR	HI	Sonovue	69% (EF) kappa 0.33	83% (EF) kappa 0.66	
Weiss <i>et al.</i> ²¹	560	^c	HI	Luminity	63% ^c (RWMA)	95% ^c (RWMA)	P<0.0001
Overall total	1069						
Mean correlation coefficient [95% CI]					0.85 (EF)[0.82–0.88] 0.81 (EDV)[0.6–1.02] 0.92 (ESV)[0.87–0.97]	0.94 (EF)[0.91–0.97] 0.94 (EDV)[0.92–0.96] 0.97 (ESV)	
Mean % agreement with gold standard					77% (EF) 61% (RWMA)	94% (EF) 83% (RWMA)	

Figures in bold refer to correlation coefficient. Percentage values refer to mean extent of agreement with standard unless otherwise stipulated.

RNI, radionuclide imaging; TEE, transoesophageal echocardiography; LV, left ventricle; EDV, end-diastolic volume; ESV, end-systolic volume; EF, ejection fraction; RWMA, regional wall motion abnormalities; FI, fundamental imaging; HI, harmonic imaging; CMR, cardiac magnetic resonance imaging.

^aNo gold standard: direct comparison between standard, harmonic, and contrast echo. Values refer to percentage of patients in whom EF could be calculated with certainty.

^bExpert panel decision as gold standard, but patients also underwent CMR. Values refer to Kappa extent of agreement with expert panel consensus.

^cValues refer to percentage of diagnostic stress echocardiograms in difficult-to-image patients within a trial.

Table 4 Contrast for endocardial border delineation in stress echocardiography

Type of study	Method	Number of subjects	Contrast	Study
Single centre	Dobutamine	117	Optison	Dolan <i>et al.</i> ²³
Single centre	Treadmill exercise	100 ^a	Optison	Shimoni <i>et al.</i> ²⁴
Single centre	Dobutamine	300	Optison	Rainbird <i>et al.</i> ²⁵
Single centre	Dipyridamole	70 ^a	Definity	Moir <i>et al.</i> ²⁶
Single centre	Dobutamine	1486 ^a	Definity Optison	Tsutsui <i>et al.</i> ¹⁰⁰
Single centre	Dobutamine	893	Levovist	Wake <i>et al.</i> ¹⁰¹
Single centre	Dipyridamole	120 ^a	Optison	Korosoglou <i>et al.</i> ¹⁰²
Single centre	Dobutamine	30	Infuson	Ikonomides <i>et al.</i> ¹⁰³

Definity, perflutren lipid microspore; Levovist, galactose /palmitic acid microcrystal suspension; Optison, perflutren protein-type A microspheres; Sonazoid, DB723/NC100100, perflubutane microspheres.

^aAlso perfusion.⁹¹

European Journal of Echocardiography (2009) 10, 194–212

Table 5 Comparative mortality in selected cardiac procedures

Procedures	Mortality
Contrast Echo	1:145 000 (SonoVue), 1:500 000 (Definity)
Myocardial Scintigraphy	1:10 000
Exercise ECG	1:2500 (or AMI)
Coronary arteriography	1:1000

Modified from Main *et al.*⁴¹

European Journal of Echocardiography (2009) 10, 194–212

Indications, imaging modality, and contrast administration for left ventricular opacification

I. Indications for resting left ventricular opacification contrast echo

In patients with suboptimal images:

- (1) To enable improved endocardial visualization and assessment of LV structure and function when two or more contiguous segments are NOT seen on non-contrast images
- (2) To have accurate and repeatable measurements of LV volumes, and ejection fraction by 2D Echo
- (3) To increase confidence of the interpreting physician in the LV function, structure and volume assessments
- (4) To confirm or exclude the echocardiographic diagnosis of the following LV structural abnormalities, when non-enhanced images are suboptimal for definitive diagnosis:
 - apical hypertrophic cardiomyopathy
 - ventricular non-compaction
 - apical thrombus
 - ventricular pseudoaneurysm

II. Indications for use of contrast in stress echocardiography

When two or more endocardial border contiguous segments of LV are not well visualized in order to:

- To obtain diagnostic assessment of segmental wall motion and thickening at rest and stress
- To increase the proportion of diagnostic studies
- To increase reader confidence in interpretation

Table 6 Imaging modalities

Power MI)	Type of imaging	Technology	Advantages	Disadvantages
High (0.8–1.0)	Intermittent	Power Doppler ultraharmonics	Very sensitive for detection of contrast	Cannot assess wall motion simultaneously
Low (0.1–0.3)	Continuous (real time)	Power modulation Power pulse inversion Cadence pulse sequencing (or coherent contrast imaging)	Wall motion can be assessed simultaneously	Less sensitive for detection of contrast

European Journal of Echocardiography (2009) 10, 194–212

Table 7 Concordance of myocardial contrast echocardiography and single-photon emission computed tomography for detection of significant coronary artery stenosis in patients with suspected coronary artery disease

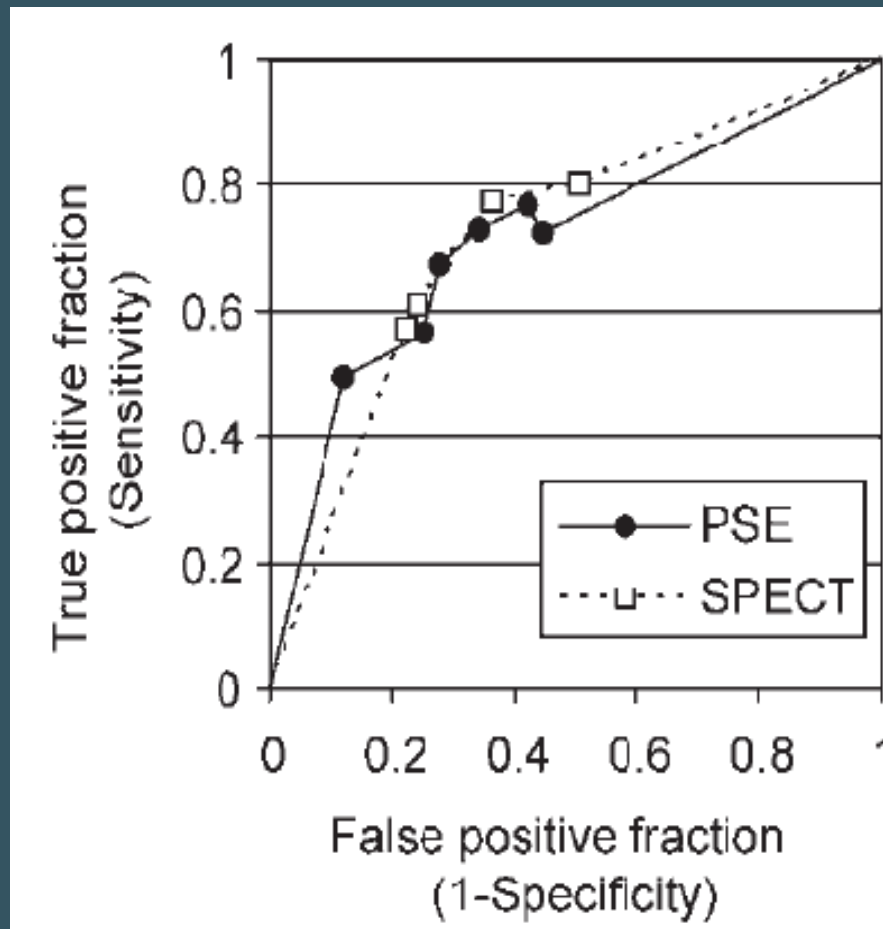
Study	Patients (n)	Imaging mode	Percentage concordance (kappa)		
			Patient basis	Territory basis	Segment basis
Kaul <i>et al.</i> ⁴⁶	30	THI	86 (0.71)	90 (0.77)	92 (0.99)
Heinle <i>et al.</i> ⁴⁷	123	HPD	81 (0.60)	76 (UN)	70 (0.32)
Shimoni <i>et al.</i> ⁴⁸	101	All	76 (0.50)	76–89 (UN)	92 (0.32)
Wei <i>et al.</i> , 2003 ⁴⁹	54	HPD	84 (0.63)	65 (0.41)	UN
Rocchi <i>et al.</i> ⁵⁰	25	HPD	84 (0.67)	92 (0.81)	UN
Olszowska <i>et al.</i> ⁵¹	44	HPD	UN	73–91 (0.4–0.8)	89 (0.81)
Senior <i>et al.</i> ⁵²	55	IPI	UN	70 (0.37)	UN
Xie <i>et al.</i> ⁵³	36	RTI	75 (0.50)	85 (0.61)	UN
Korosoglou <i>et al.</i> ⁵⁴	120	PPI	UN	83 (0.65)	86 (0.65)
Total	(T)588				
Overall mean [95% CI]			81 [76.4–85.6]	81 [74.9–86.5]	86 [76.6–95]

Values are expressed as concordance and agreement (kappa).

All, accelerated intermittent imaging; HPD, harmonic power Doppler; IPI, intermittent pulse inversion; PPI, power pulse inversion; RTI, real-time imaging; SPECT, single-photon-emission computed tomography; THI, triggered harmonic imaging; UN, unknown.

Adapted from Bhatia and Senior.¹⁰⁴

European Journal of Echocardiography (2009) 10, 194–212



European Journal of Echocardiography (2009) 10, 194–212

Figure 1 Multi-reader receiver operating characteristics. Values for each blinded reader from RAMP-1 and -2 trials. Modality-specific curves were extrapolated to the theoretical minimum and maximum values. AUCs were 0.72 for both PSE and SPECT.

Table 8 Accuracy of myocardial contrast echocardiography for the detection of coronary artery disease

Study	Patients undergoing coronary angiography	CAD present	MCE sensitivity	MCE specificity
Chiou <i>et al.</i> ¹⁰⁵	132	85	81	77
Cwaig <i>et al.</i> ¹⁰⁶	45	32	87	66
Elhendy <i>et al.</i> ¹⁰⁷	170	127	91	51
Heinle <i>et al.</i> ⁴⁷	15	12	75	67
Jeetley <i>et al.</i> ¹⁰⁸	123	96	84	56
Karavidas <i>et al.</i> ¹⁰⁹	47	11	91	92
Korosoglou <i>et al.</i> ⁵⁴	89	62	83	72
Lin <i>et al.</i> ¹¹⁰	40	25	84	93
Malm <i>et al.</i> ¹¹¹	43	33	77	72
Moir <i>et al.</i> ²⁶	90	48	93	65
Olszowska <i>et al.</i> ⁵¹	44	44	97	93
Peltier <i>et al.</i> ⁸³	35	22	Qualitative 85 Quantitative 97	Qualitative 79 Quantitative 79–82
Rocchi <i>et al.</i> ⁵⁰	12	12	89	100
Senior <i>et al.</i> ⁵²	55	43	86	88
Senior <i>et al.</i> ⁸⁵	52	22	82	97
Shimoni <i>et al.</i> ⁴⁸	44	28	75	100
Tsutsui <i>et al.</i> ⁹³	16	13	RT imaging 64TR imaging 41	RT imaging 92 TR imaging 96
Winter <i>et al.</i> ¹¹²	36	35	81	67
Hayat <i>et al.</i> ⁸⁶	63	25	92	95
Aggeli C <i>et al.</i> ⁴¹	532	413	92	61
Total	1683	1345		
Mean [95% CI]			83 [78–88]	80 [73–87]

European Journal of Echocardiography (2009) 10, 194–212

Table 9 Accuracy of resting intravenous myocardial contrast echocardiography for the prediction of myocardial viability

Authors	Type of imaging	No. of patients (<i>n</i> = 736)	MCE perfusion	
			Sensitivity (%)	Specificity (%)
Sbano <i>et al.</i> ¹¹³	High MI	50	95	52
Senior <i>et al.</i> ⁷³	High MI	96	62	83
Aggeli <i>et al.</i> ¹¹⁴	High MI	34	88	61
Hillis <i>et al.</i> ¹¹⁵	Low MI	33	86	44
Main <i>et al.</i> ¹¹⁶	Low MI	46	69	85
Swinburn <i>et al.</i> ¹¹⁷	Low MI	19	68	88
Hillis <i>et al.</i> ¹¹⁸	High MI	35	80	67
Lepper <i>et al.</i> ¹¹⁹	High MI	35	94	87
Janardhanan <i>et al.</i> ⁷⁰	Low MI	42	82	83
Hickman <i>et al.</i> ¹²⁰	Low MI	56	83	78
Greaves <i>et al.</i> ⁷⁵	Low MI	15	88	74
Janardhanan <i>et al.</i> ¹²¹	Low MI	50	92	75
Main <i>et al.</i> ¹²²	Low MI	34	77	83
Shimoni <i>et al.</i> ⁷⁴	High MI	18	90	63
Hickman <i>et al.</i> ⁷²	Low MI	23	87	67
Agati <i>et al.</i> ¹²³	High MI	23	100	90
Huang <i>et al.</i> ¹²⁴	Low MI	34	83	82
Bolognese <i>et al.</i> ⁷⁶	High MI	30	96	18
Abe <i>et al.</i> ¹²⁵	High MI	31	98	32
Kousoglou ¹²⁶	Low MI	32	81	88
Mean			85	70

MCE, myocardial contrast echocardiography.

European Journal of Echocardiography (2009) 10, 194–212

Table 10 Interpretation of resting contrast echo studies

Wall motion	Myocardial contrast	Diagnostic confidence
Normal	Normal	High
Abnormal	Abnormal	High
Abnormal	Normal	Stunning, hibernation
Normal	Abnormal	Artefact

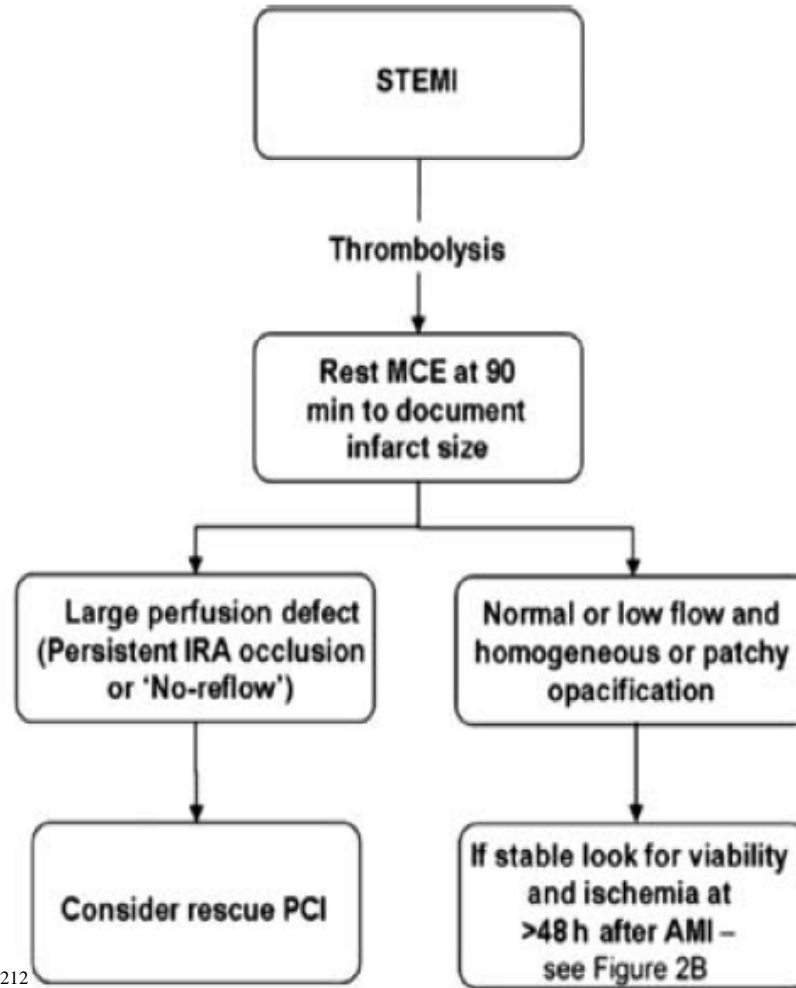
European Journal of Echocardiography (2009) 10, 194–212

Table 11 Interpretation of stress contrast studies

Wall motion	Myocardial contrast	Diagnostic confidence
Normal	Normal	High
New WMA	Perfusion defect	High perfusion defect often depicts extent of ischaemia better
New WMA	Normal	May be artefact, but if in centre of plane cardiomyopathy
Normal	Perfusion defect	Ischaemia

European Journal of Echocardiography (2009) 10, 194–212

(A)



European Journal of Echocardiography (2009) 10, 194–212

Figure 2 (A) Schematic diagram for the proposed role of myocardial contrast echocardiography in assessment of patients in the acute phase of STEMI.

From: Hayat SA, Senior R. Myocardial contrast echocardiography in ST elevation myocardial infarction: ready for prime time? Eur Heart J 2008;29:299–314

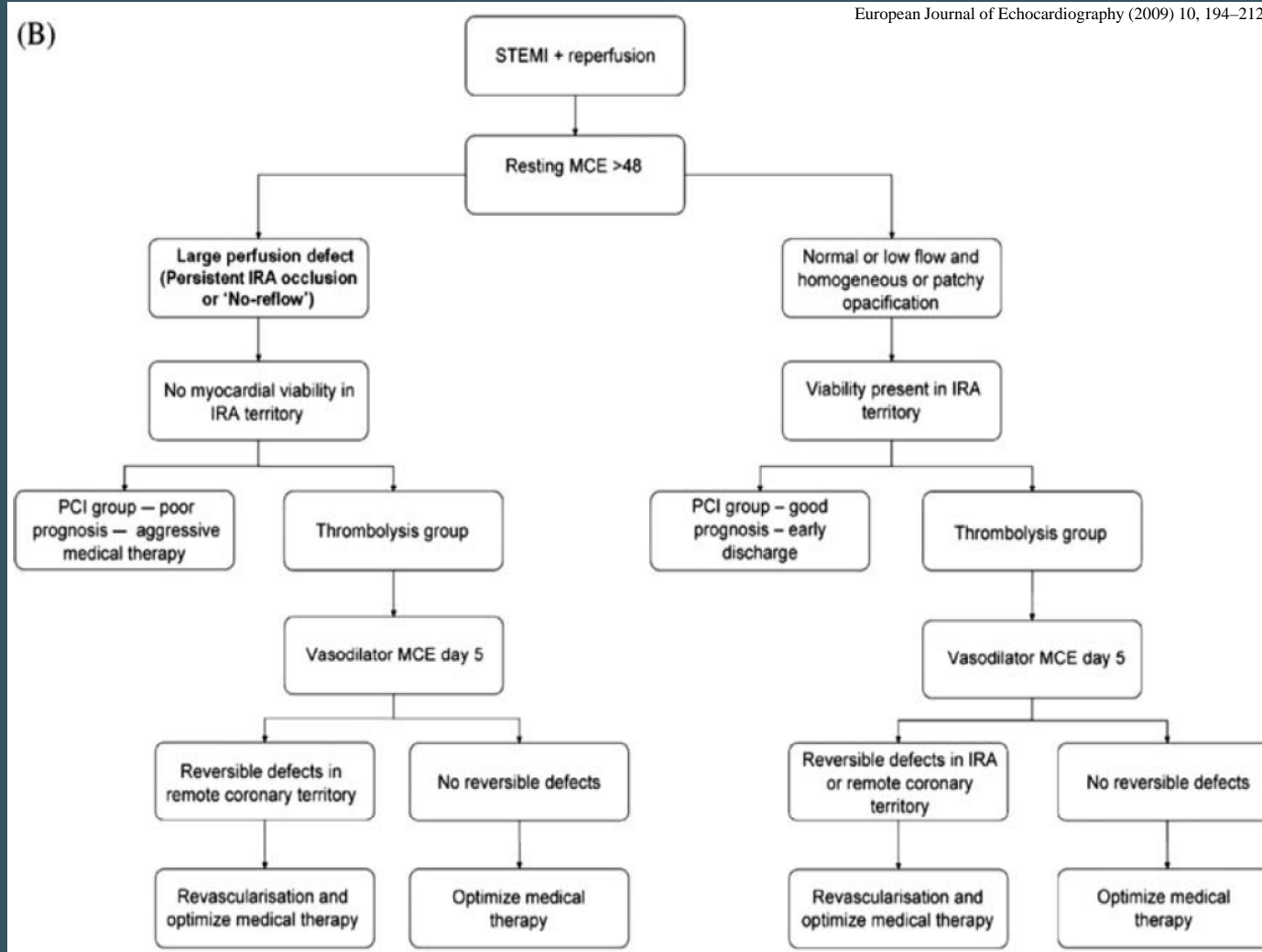
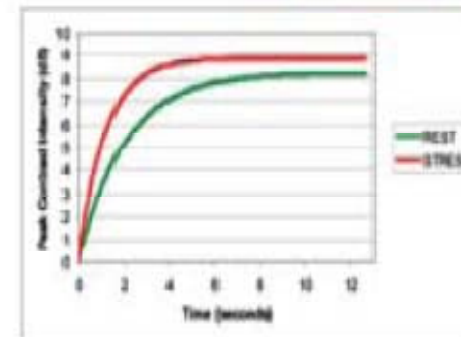
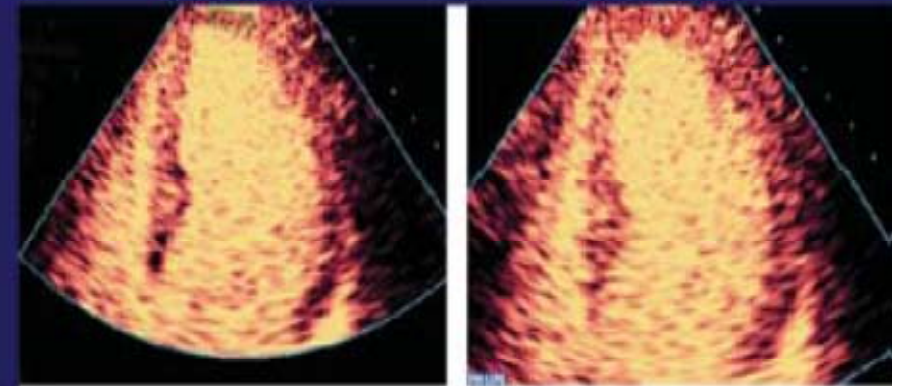
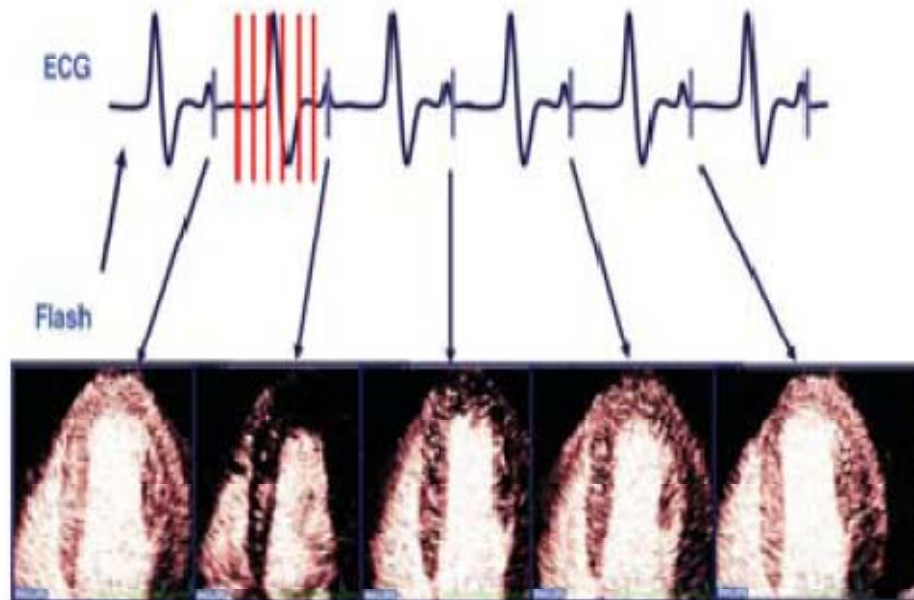


Figure 2 (B) Schematic diagram for the proposed role of myocardial contrast echocardiography in assessment of patients with recent STEMI following reperfusion.

From: Hayat SA, Senior R. Myocardial contrast echocardiography in ST elevation myocardial infarction: ready for prime time? Eur Heart J 2008;29:299–314

Triggered Replenishment Imaging



European Journal of Echocardiography (2009) 10, 194–212

Figure 3 Quantification of myocardial blood flow by myocardial contrast echocardiography

www.escardio.org/EAE

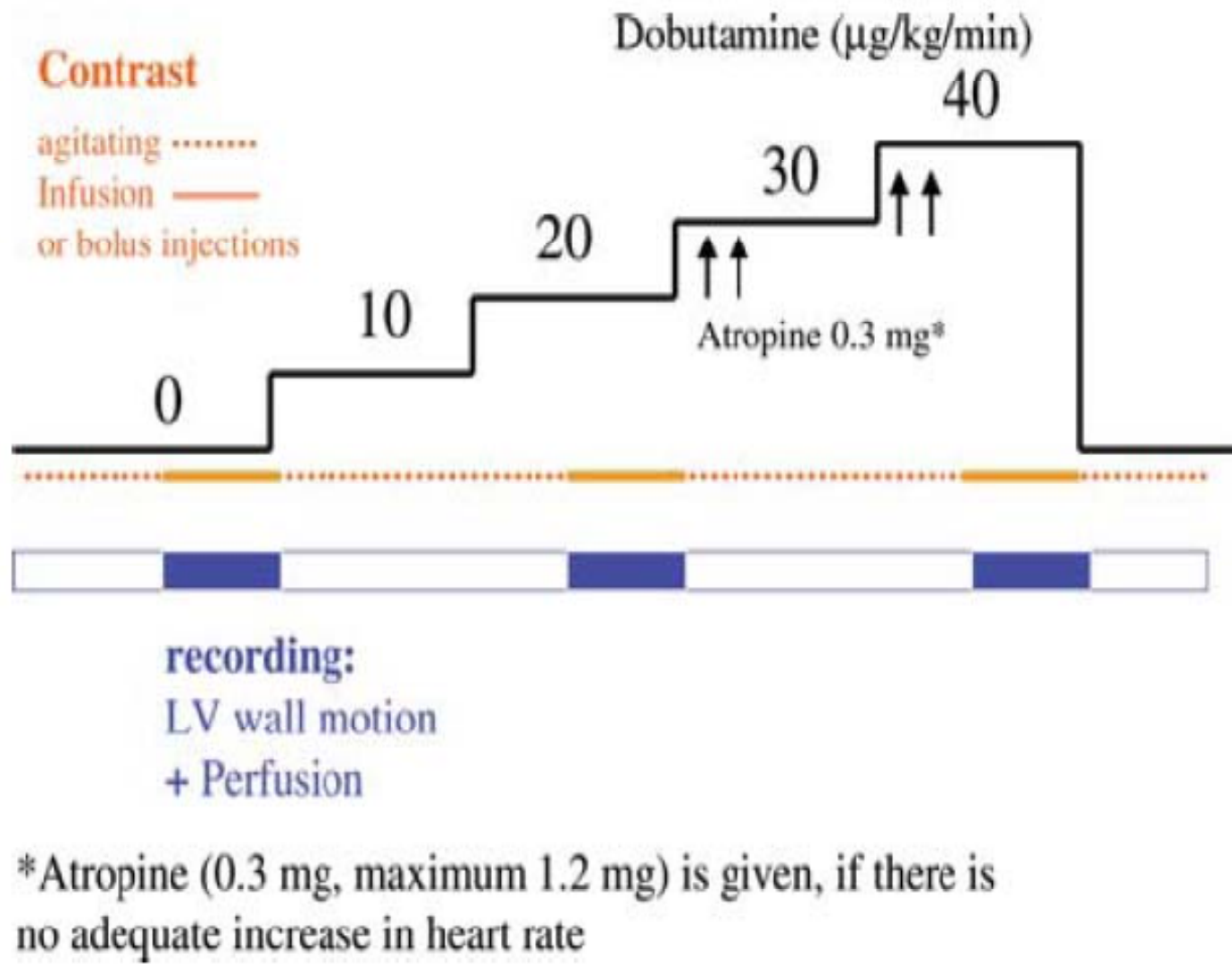
Figure 4. Protocol 1 (low power, real time) for myocardial contrast echocardiography

- 1: standard 2D (tissue harmonic) imaging to adjust scanplanes.
- 2: activate preset *Contrast preset 1 (low power, real-time)*.
- 3: adjust focus (mitral valve level) and gain to achieve some mild background noise (on some scanners, it is only one gain control, whereas on other there different controls for time gain compensation and lateral gain), adjust sector width to obtain frame rate >25 Hz.
- 4: inject contrast bolus (0.3 mL Optison, 0.3 mL Luminity or 0.3 mL SonoVue) or infuse contrast agent 0.8–0.9 mL/min SonoVue or 1 drop/s Luminity.
- 5A: Image acquisition for *bolus injection* (digital loops preferable, back-up on tape) usually it takes at least 30 s after the injection of contrast to opacify the LV before acquiring images check whether LV and myocardial opacification is adequate and that no attenuation is present
4CV, 2CV, 3CV (SAX and LAX may be omitted as they cause attenuation)
1 beat loops in each view.
- 5B: Image acquisition for *contrast infusion* (digital loops preferable, back up on tape):
usually it takes at least 30 s after start of infusion to opacify the LV before acquiring images check whether LV and myocardial opacification is adequate and reduce infusion rate if attenuation is present
4CV, 2CV, 3CV (SAX and LAX may be omitted to save contrast agent)
1 beat loops in each view
flash replenishment technique when infusing contrast
(15 beat loop, high power flash after 2 cardiac cycles)

The setting of the flash has to be adjusted during rest, the flash should clear the contrast from the myocardium with visible destruction (=reduction in intensity in the LV cavity). start with 7 frames duration and MI 0.9)
Triggered low power imaging: use 1:1 trigger, trigger point at endsystole, flash replenishment technique like for real-time imaging and record additional single beat loops in real-time to record wall motion

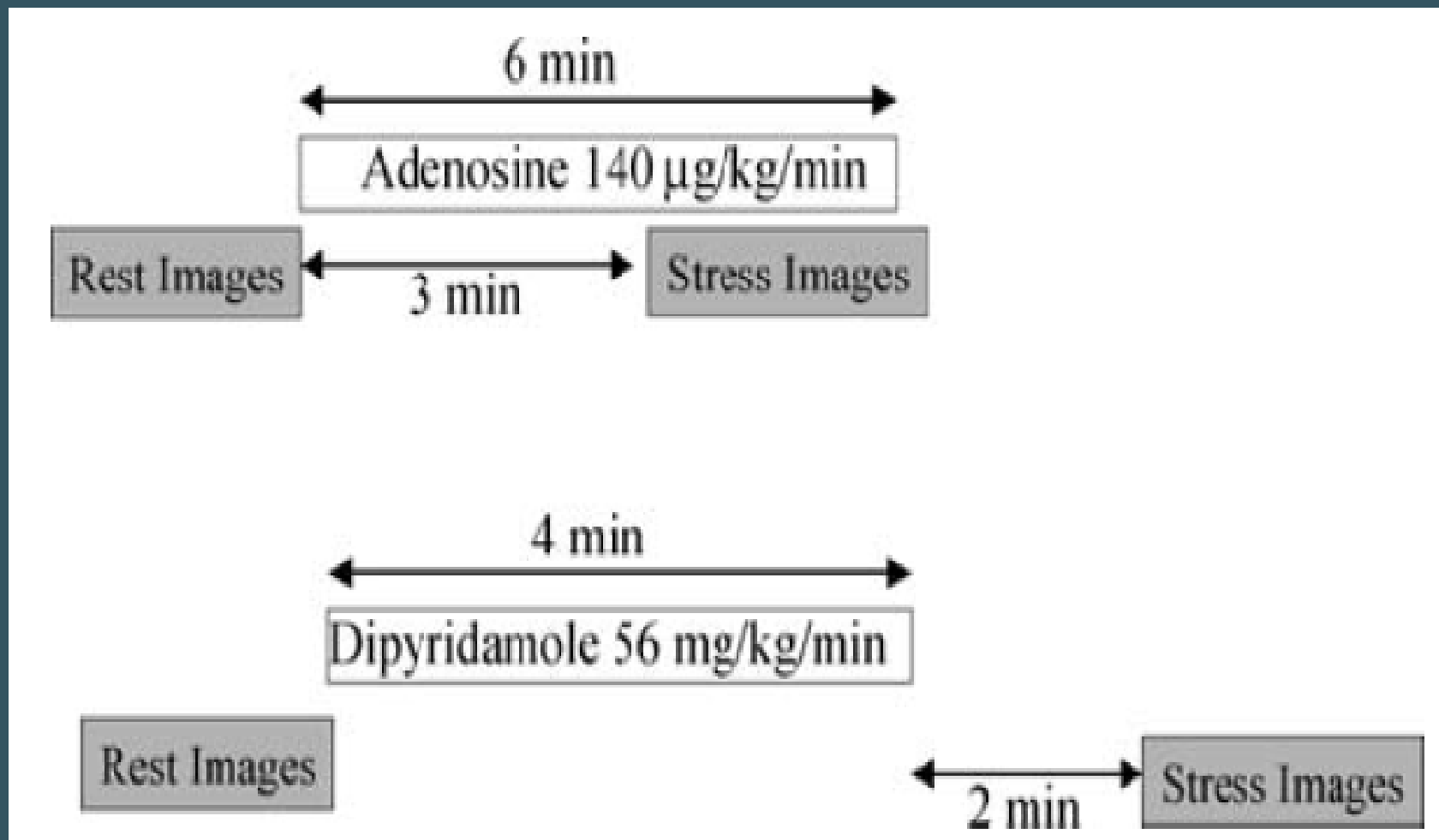
Figure 5. Protocol 2 (high power, triggered imaging) for myocardial contrast echocardiography

- 1: standard 2D (tissue harmonic) imaging to adjust scanplanes
- 2: activate preset *Contrast preset 2 (high power, triggered imaging) second harmonic, ultraharmonic, pulse inversion or harmonic power Doppler (Angio)*
- 3: adjust focus (mitral valve level) and gain to achieve some mild background noise (on some scanners it's only one gain control on other there different controls for time gain compensation and lateral gain)
- 4: adjust trigger (=select the R wave delay for frame acquisition)
double trigger (consecutive imaging and destruction frame):
helps to control whether wall motion artefacts are present
and the contrast agent has been completely destroyed by the imaging frame
trigger point : end-systolic trigger work, avoid upsloping part of T wave!
trigger interval: every fourth cardiac cycle for visual analysis
- 5: infuse contrast agent (0.9 mL/min SonoVue or 1 drop/s Luminity)
for triggered imaging infusion of contrast is recommended
- 6: Image acquisition for *contrast infusion* (digital loops preferable, back up on tape):
usually it takes at least 30 s to opacify the myocardium
before acquiring images check whether LV and myocardial opacification is adequate in 4CV (decrease infusion speed in case of attenuation, increase infusion speed if a normally/hypokinetic contracting mid or apical segment is not opacified)
4CV, 2CV, 3CV (SAX and LAX may be omitted to avoid attenuation)



European Journal of Echocardiography (2009) 10, 194–212

Figure 6 Dobutamine stress contrast protocol



European Journal of Echocardiography (2009) 10, 194–212

Figure 7 Vasodilator protocol