

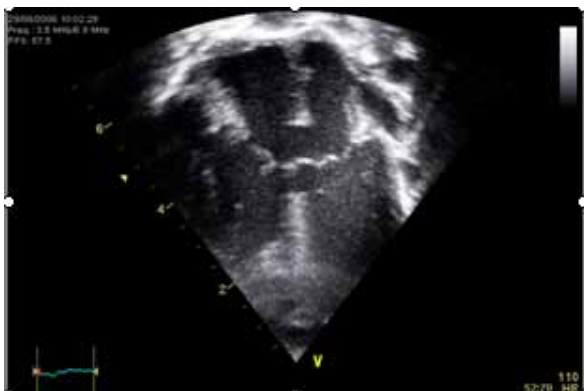
EXAMPLE CLINICAL CASES EVALUATION QUESTIONS AND ANSWERS

CASE 1.

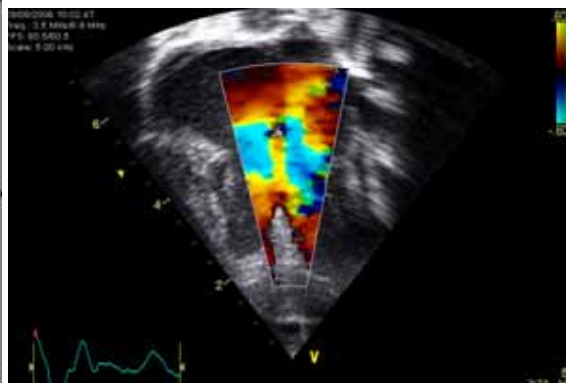
NEWBORN 4 DAYS OLD

TRISOMY 21

LOUD MURMUR GR4/6 UPPER LEFT PARASTERNAL BORDER

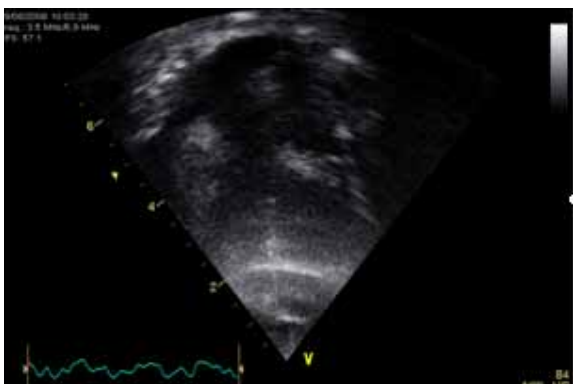


VIDEO 1

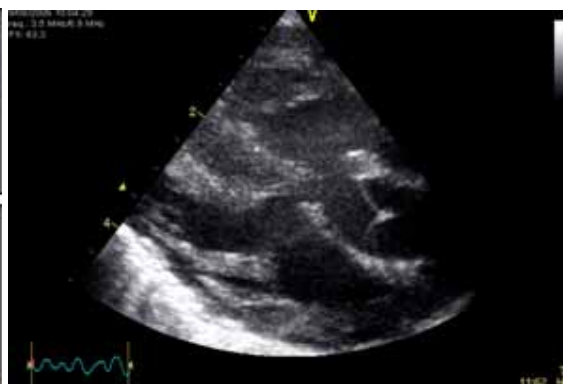

VIDEO 2

- | | |
|---|-------|
| a) THERE IS A LARGE INLET VENTRICULAR SEPTAL DEFECT | TRUE |
| b) THERE IS A LARGE ATRIOVENTRICULAR SEPTAL DEFECT | TRUE |
| c) THERE IS A LARGE SINUS VENOSUS SEPTAL DEFECT | FALSE |
| d) THERE MUST BE PULMONARY HYPERTENSION | FALSE |
| e) THERE IS A LARGE SECUNDUM ATRIAL SEPTAL DEFECT | FALSE |



VIDEO 3



VIDEO 4

- | | |
|---|-------|
| A)THE VSD IS CONFINED TO THE INLET REGION | FALSE |
| B)THE VSD IS A DOUBLY COMMITTED VSD | FALSE |
| C)THERE IS A DOUBLE OUTLET RIGHT VENTRICLE | FALSE |
| D)THE AORTIC VALVE IS THICKENED AND STENOTIC | FALSE |
| E)THERE IS RIGHT VENTRICULAR AND SEPTAL HYPERTROPHY | |