

# Recommendations for the practice of echocardiography in infective endocarditis

**Gilbert Habib (France)\*, Luigi Badano (Italy), Christophe Tribouilloy (France), Isidre Vilacosta (Spain), and Jose Luis Zamorano (Spain)**

**Scientific Committee: Maurizio Galderisi (Italy), Jens-Uwe Voigt (Belgium), Rosa Sicari (Italy)**

**Document Reviewers: Bernard Cosyns (Belgium), Kevin Fox (UK), Svend Aakhus (Norway)**

**On behalf of the European Association of Echocardiography**

Service de Cardiologie, CHU La Timone, Bd Jean Moulin, 13005 Marseille, France

*Received 20 December 2009; accepted after revision 30 December 2009*

# IE: new guidelines EAE 2010

---

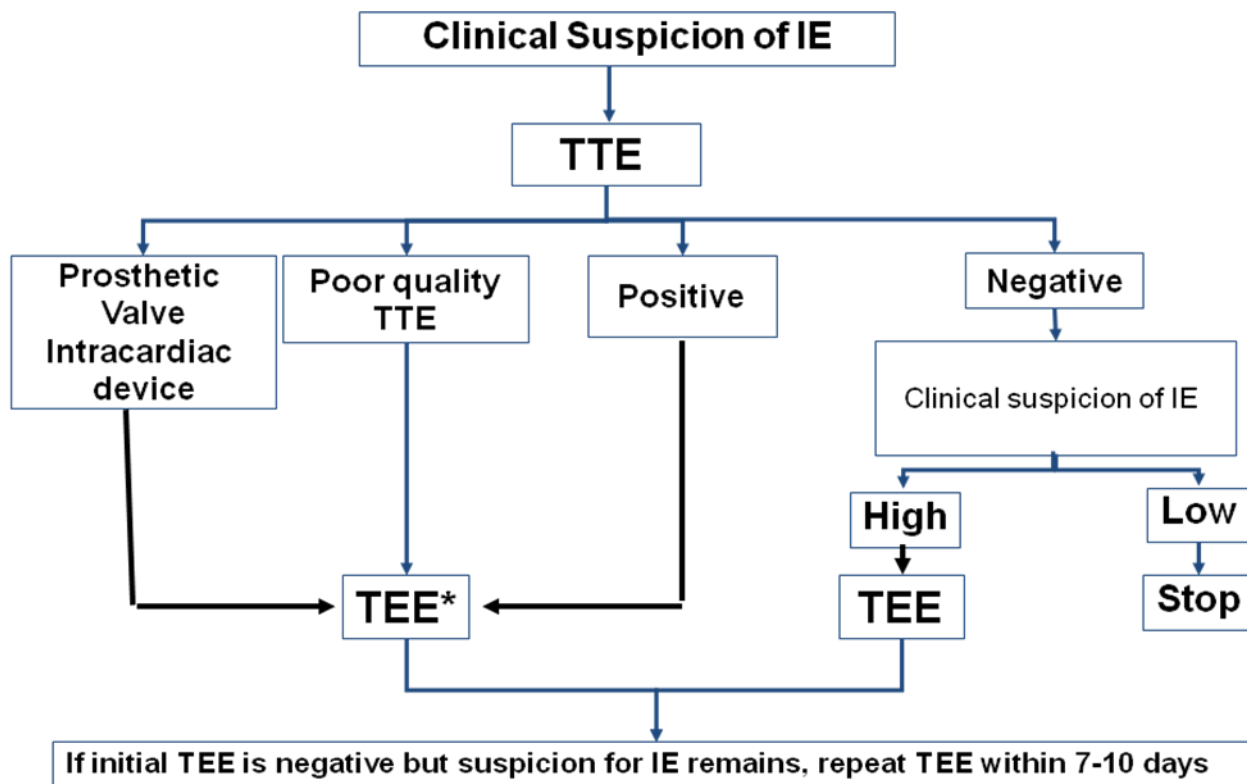
- 1. diagnosis**
- 2. management of complications**
- 3. prognostic assessment / follow-up**
- 4. intraoperative echocardiography**
- 5. specific situations**

# IE: new guidelines EAE 2010

1. ***diagnosis***
2. **management of complications**
3. **prognostic assessment / follow-up**
4. **intraoperative echocardiography**
5. **specific situations**

# Anatomic and echo definitions

	Surgery/necropsy	Echocardiography
<b>Vegetation</b>	Infected mass attached to an endocardial structure, or on implanted intracardiac material	Oscillating or non oscillating intracardiac mass on valve or other endocardial structures, or on implanted intracardiac material
<b>Abscess</b>	Perivalvular cavity with necrosis and purulent material not communicating with the cardiovascular lumen	Thickened, non-homogeneous perivalvular area with echodense or echolucent appearance
<b>Pseudoaneurysm</b>	Perivalvular cavity communicating with the cardiovascular lumen	Pulsatile perivalvular echo-free space, with colour-Doppler flow detected
<b>Perforation</b>	Interruption of endocardial tissue continuity	Interruption of endocardial tissue continuity traversed by colour-Doppler flow
<b>Fistula</b>	Communication between 2 neighbouring cavities through a perforation	Colour-Doppler communication between 2 neighbouring cavities through a perforation
<b>Valve aneurysm</b>	Saccular outpouching of valvular tissue	Saccular bulging of valvular tissue
<b>Dehiscence of a prosthetic valve</b>	Dehiscence of the prosthesis	Paravalvular regurgitation identified by TTE/TEE, with or without rocking motion of the prosthesis



*\*TEE is not mandatory in isolated right-sided native valve IE with good quality TTE examination and unequivocal echocardiographic findings.*

# ***Recommendation 1: diagnosis***

- 1) TTE is recommended as the first imaging modality in suspected IE***
- 2) TEE is recommended in patients with high clinical suspicion of IE and a normal TTE***
- 3) TEE should be considered in the majority of patients with suspected IE, even in case with positive TTE***
- 4) Repeat TTE/TEE within 7-10 days is recommended in case of initially negative examination when clinical suspicion of IE remains high***
- 5) TEE is not indicated in patients with good-quality negative TTE and low clinical suspicion of IE***

# IE: new guidelines EAE 2010

---

1. **diagnosis**
2. ***management of complications***
3. **prognostic assessment / follow-up**
4. **intraoperative echocardiography**
5. **specific situations**

# IE: new guidelines EAE 2010

Recommendations: Indications for surgery	Timing*	Class <sup>a</sup>	Level <sup>b</sup>
<b>A - HEART FAILURE</b>			
Aortic or mitral IE with severe acute regurgitation or valve obstruction causing refractory pulmonary oedema or cardiogenic shock	Emergency	I	B
Aortic or mitral IE with fistula into a cardiac chamber or pericardium causing refractory pulmonary oedema or shock	Emergency	I	B
Aortic or mitral IE with severe acute regurgitation or valve obstruction and persisting heart failure or echocardiographic signs of poor haemodynamic tolerance (early mitral closure or pulmonary hypertension)	Urgent	I	B
Aortic or mitral IE with severe regurgitation and no HF	Elective	IIa	B
<b>B - UNCONTROLLED INFECTION</b>			
Locally uncontrolled infection (abscess, false aneurysm, fistula, enlarging vegetation)	Urgent	I	B
Persisting fever and positive blood cultures > 7-10 days	Urgent	I	B
Infection caused by fungi or multiresistant organisms	Urgent/elective	I	B
<b>C - PREVENTION OF EMBOLISM</b>			
Aortic or mitral IE with large vegetations (> 10 mm) following one or more embolic episodes despite appropriate antibiotic therapy	Urgent	I	B
Aortic or mitral IE with large vegetations (> 10 mm) and other predictors of complicated course (heart failure, persistent infection, abscess)	Urgent	I	C
Isolated very large vegetations (> 15 mm) <sup>#</sup>	Urgent	IIb	C

# ***Recommendation 2: management of complications***

- 1) Heart failure, perivalvular infection, and high embolic risk are the 3 main indications for early surgery***
- 2) Echocardiography plays a major role in decision-making when one of these situations occurs***
- 3) Echocardiography helps clinicians not only for taking the decision to operate or not, but also for choosing the optimal timing of surgery***
- 4) The presence of heart failure, abscess, or high embolic risk usually indicates urgent surgery***

# IE: new guidelines EAE 2010

1. **diagnosis**
2. **management of complications**
3. ***prognostic assessment / follow-up***
4. **intraoperative echocardiography**
5. **specific situations**

# Echocardiographic prognostic markers

## Echocardiographic findings

- Periannular complications
- Severe left-sided valve regurgitation
- Low left ventricular ejection fraction
- Pulmonary hypertension
- Large vegetations
- Severe prosthetic dysfunction
- Premature mitral valve closure and other signs of elevated diastolic pressures

# ***Recommendation 3: follow-up***

- 1) Repeat TTE and TEE are recommended as soon as a new complication of IE is suspected***
- 2) Repeat TTE and TEE should be considered during the follow-up of uncomplicated IE, in order to detect silent complication and monitor vegetation size.***
- 3) TTE is recommended before discharge for subsequent comparison***
- 4) Clinical and echocardiographic periodic follow-up is mandatory during the first year after the end of antibiotic treatment.***

# IE: new guidelines EAE 2010

1. **diagnosis**
2. **management of complications**
3. **prognostic assessment / follow-up**
4. ***intraoperative echocardiography***
5. **specific situations**

# ***Recommendation 4: Intra-operative echocardiography***

- 1) Intraoperative TEE provides useful data for the planning of surgery, is essential for the immediate control of the surgical procedure, has the potential to improve surgical results, and is a reference for future studies.***
- 2) The impact of intraoperative TEE leads to recommend its routine and systematic use, especially in cases of conservative valve surgery and other complex procedures.***
- 3) Intraoperative TEE is recommended in all patients with IE undergoing cardiac surgery.***

# IE: new guidelines EAE 2010

1. **diagnosis**
2. **management of complications**
3. **prognostic assessment / follow-up**
4. **intraoperative echocardiography**
5. ***specific situations***

# IE: specific situations

- 1. *Prosthetic valve IE (PVE)***
- 2. *Cardiac device-related IE (CDRIE)***
- 3. *Right-sided IE***

# ***Recommendation 5: PVE***

- 1) Both TTE and TEE are recommended in suspected or definite PVE***
- 2) Perivalvular complications are frequent in PVE and are better assessed by TEE***
- 3) The sensitivity of echocardiography is lower in PVE than in NVE***
- 4) Perioperative and postoperative echocardiographic assessments of patients with PVE are recommended***
- 5) Repeat echocardiography after discharge is recommended in PVE treated by medical therapy alone because of the risk of late prosthetic dysfunction***

# ***Recommendation 6: CDRIE***

- 1) Although TTE is superior to TTE, both are mandatory in suspected or definite CDRIE***
- 2) The sensitivity of echocardiography is lower in CDRIE than in NVE***
- 3) Echocardiography is also useful for the measurement of vegetation size and should be repeated for follow-up after device explantation.***

# ***Recommendation 7: right-sided IE***

- 1) TEE is not mandatory in isolated right-sided native valve IE with good quality TTE examination and unequivocal echocardiographic findings.***
- 2) The size of the tricuspid vegetation and the severity of the tricuspid regurgitation must be evaluated by echocardiography, because these measurements have the potential to influence the therapeutic strategy.***

# Conclusion: echocardiography in IE

1. key role of echocardiography, but diagnosis is still sometimes difficult
2. major role for prognostic assessment
  - ✦ hemodynamic risk
  - ✦ infectious risk
  - ✦ embolic risk
3. intraoperative echo in the majority of patients